



PATIENT PRESENTING CLINICAL SIGNS

Zeb Elliott NK: 06-14-23 at 9:34a: Eating and drinking well. Eating a grain free dry food - "Pure Being" with duck and sweet potato. Normal thirst. No vomiting or diarrhea. Coughs occasionally - started a few months ago maybe and occurs daily when laying upside down. Cough is dry and easily triggered. Normal exercise and behavior. No sneezing. Licking at his feet. No other itching or allergy type issues. On Nexguard and Interceptor Plus.

SPECIES

Canine

RADIOGRAPHIC STUDY OF THE THORAX

BREED

Orthogonal views of the thorax are provided for review totaling three images. One right lateral, one left lateral and one ventral dorsal view.

Old English Sheepdog

RADIOGRAPHIC FINDINGS

SEX

The cervical and thoracic trachea are normal.

Neutered Male

There is a mild diffuse bronchial pattern throughout the pulmonary parenchyma. In addition, a small pulmonary bulla is seen in the right caudal lung lobe.

AGE

The cardiac silhouette spans approximately 50% of the thoracic width, 3.0 intercostal spaces, with normal shape. (VHS = 10.0). The pulmonary vessels are normal.

10 Years

The pleural space and mediastinum are normal.

INTERPRETED BY

The diaphragm is normal.

Tilde Rodrigues Froes, DMV, MSc., Dr. Med Vet., Dipl. CBraRVet

Multifocal incomplete and complete bridging thoracic spondylosis deformans is noted.

The collimated abdomen is unremarkable.

RADIOGRAPHIC DIAGNOSIS

HOSPITAL NAME

Williamsport West Veterinary Hospital

- Mild diffuse bronchial pulmonary pattern. The differential diagnosis includes allergic lower airway disease, chronic bronchitis, infectious bronchitis. No evidence of bronchopneumonia.
- Focal incidental pulmonary bulla at the right caudal lung lobe.
- Multifocal thoracic spondylosis deformans incidental.

REFERRING VET

Daverio

INTERPRETATION OF THE FINDINGS & FURTHER RECOMMENDATIONS

The pulmonary radiographic findings explain the clinical signs of chronic coughing. Medical treatment for allergic/inflammatory bronchitis is suggested. If patient does not improve, consider bronchoalveolar lavage for obtaining samples for cytology, culture, and sensitivity.

INVOICE

58969

DATE

6-22-23



PATIENT

Zeb Elliott

SPECIES

Canine

BREED

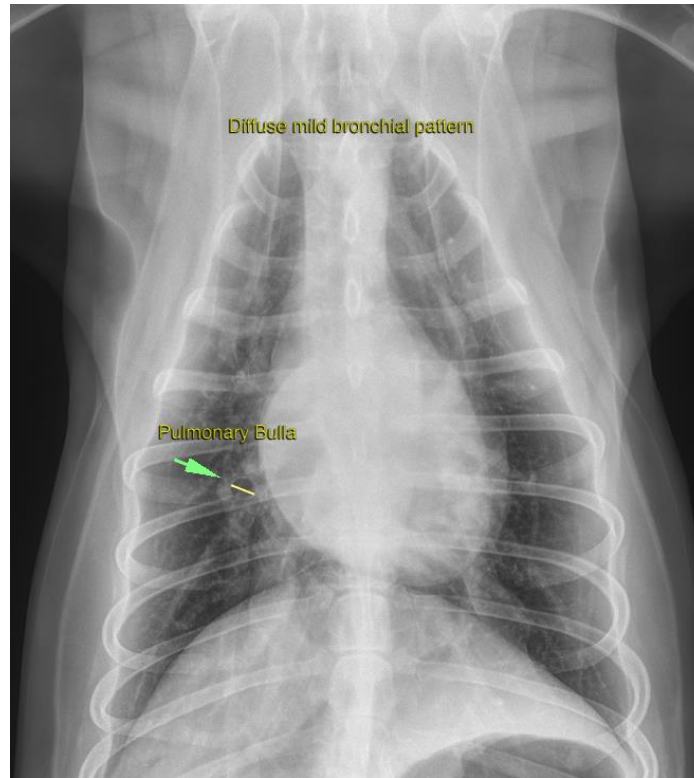
Old English Sheepdog

SEX

Neutered Male

AGE

10 Years



INTERPRETED BY

Tilde Rodrigues Froes,
DMV, MSc., Dr. Med
Vet., Dipl. CBraRVet

HOSPITAL NAME

Williamsport West
Veterinary Hospital

REFERRING VET

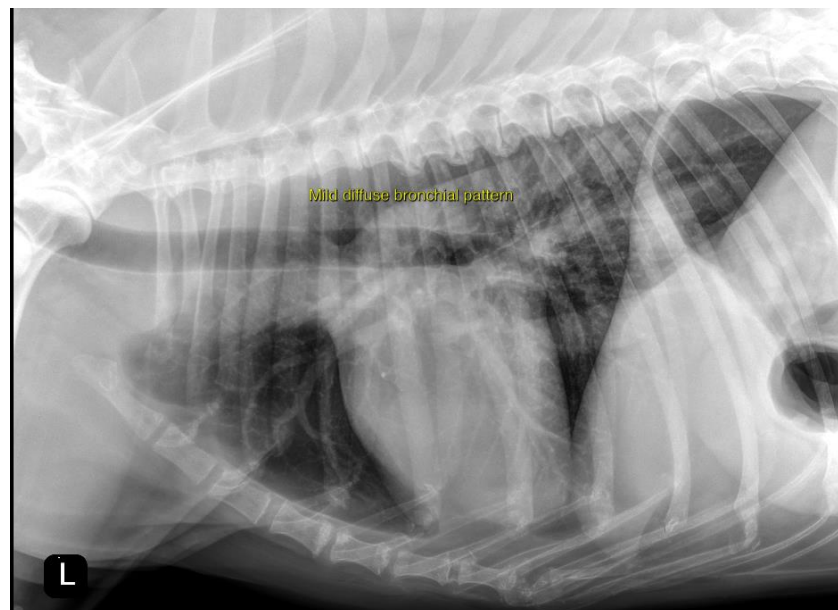
Daverio

INVOICE

58969

DATE

6-22-23





PATIENT

Zeb Elliott

SPECIES

Canine

BREED

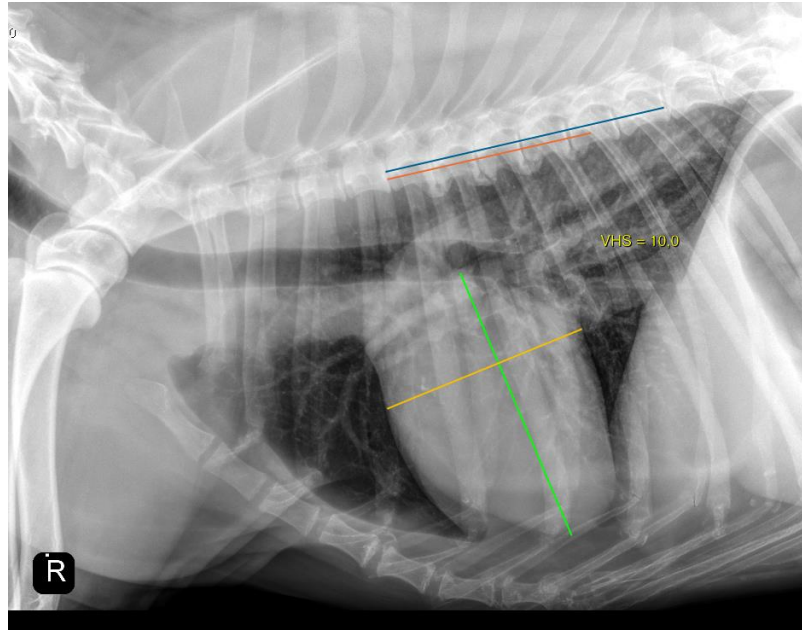
Old English Sheepdog

SEX

Neutered Male

AGE

10 Years



The information and recommendations provided are based on the images presented by the referring veterinarian. No evaluation can be communicated regarding pathology that was not visible in the image/video clips provided.

INTERPRETED BY

Tilde Rodrigues Froes,
DMV, MSc., Dr. Med
Vet., Dipl. CBraRVet

Thank you for this referral. If the clinical or image interpretation does not parallel your findings or if I can be of any further assistance please contact me.

Tilde Rodrigues Froes, DMV, MSc., Dr. Med.Vet., Dipl.CBraRVet
info@sonopath.com

HOSPITAL NAME

Williamsport West
Veterinary Hospital

REFERRING VET

Daverio

INVOICE

58969

DATE

6-22-23