



PATIENT PRESENTING CLINICAL SIGNS

Lincoln Radtke Sneezing, shaking head over the past year. Past 6 months has worsened. Famciclovir 250mg 1 tab PO BID Lysine supplement

SPECIES COMPUTED TOMOGRAPHIC STUDY OF THE HEAD

Feline A high-resolution pre- and post-contrast CT study of the head are provided for review totaling two series. One pre-contrast series, soft tissue algorithm. One post-contrast series soft tissue algorithm.

BREED COMPUTED TOMOGRAPHIC FINDINGS

DSH The nostrils and nasal cavity are unremarkable. No evidence of mass effect or fluid accumulation. The turbinate architecture and symmetry are normal. The frontal sinuses are symmetrical and air-filled.

SEX The tympanic bullae and auditory ear canal lumen and wall are unremarkable.

MN The choana, pharynx and larynx are normal.

AGE The retrobulbar spaces and the ocular globes are normal.

3 Years, 7 Months

Cribriform plate is normal.

Bilaterally, the temporomandibular joints are congruent.

INTERPRETED BY The maxillary and mandibular teeth are normal. All teeth are present.

Tilde Rodrigues Froes, DMV, MSc., Dr. Med Vet., Dipl. CBraRVet

The brain is normal, no mass effect.

The mandibular and medial retropharyngeal lymph nodes are unremarkable.

The osseous calvarium and osseous facial structures are intact.

HOSPITAL NAME

Casselton Vet Service

COMPUTED TOMOGRAPHIC DIAGNOSIS

- Normal head CT scan.
- No evidence of tomographic changes in the nasal cavity or cranial airway structures.
- Normal brain parenchyma.

REFERRING VET

Dr. Brad Bartholomay

INTERPRETATION OF THE FINDINGS & FURTHER RECOMMENDATIONS

Normal head CT scan. No abnormalities on the exam that could explain the presented clinical signs of sneezing and shaking head. Considering the patient's clinical history, a differential diagnosis includes a mild allergic, viral, or mild lymphocytic plasmocytic rhinitis.

INVOICE

58905

DATE

6-20-23



PATIENT

Lincoln Radtke

SPECIES

Feline

BREED

DSH

SEX

MN

AGE

3 Years, 7 Months

INTERPRETED BY

Tilde Rodrigues Froes,
DMV, MSc., Dr. Med
Vet., Dipl. CBraRVet

HOSPITAL NAME

Casselton Vet Service

REFERRING VET

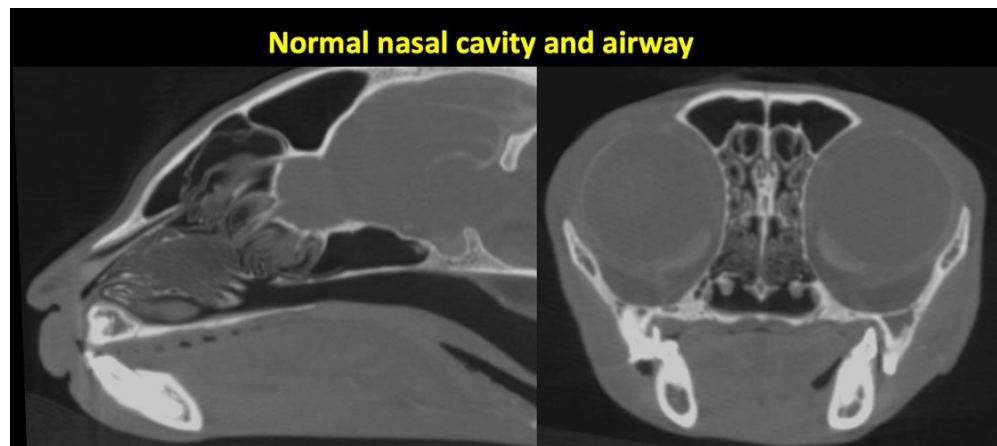
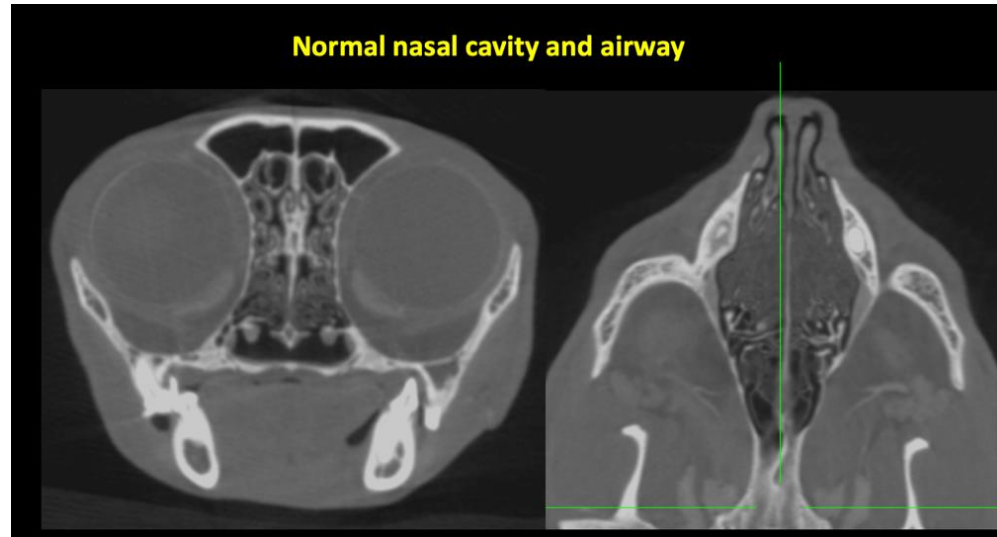
Dr. Brad Bartholomay

INVOICE

58905

DATE

6-20-23





PATIENT

Lincoln Radtke

SPECIES

Feline

BREED

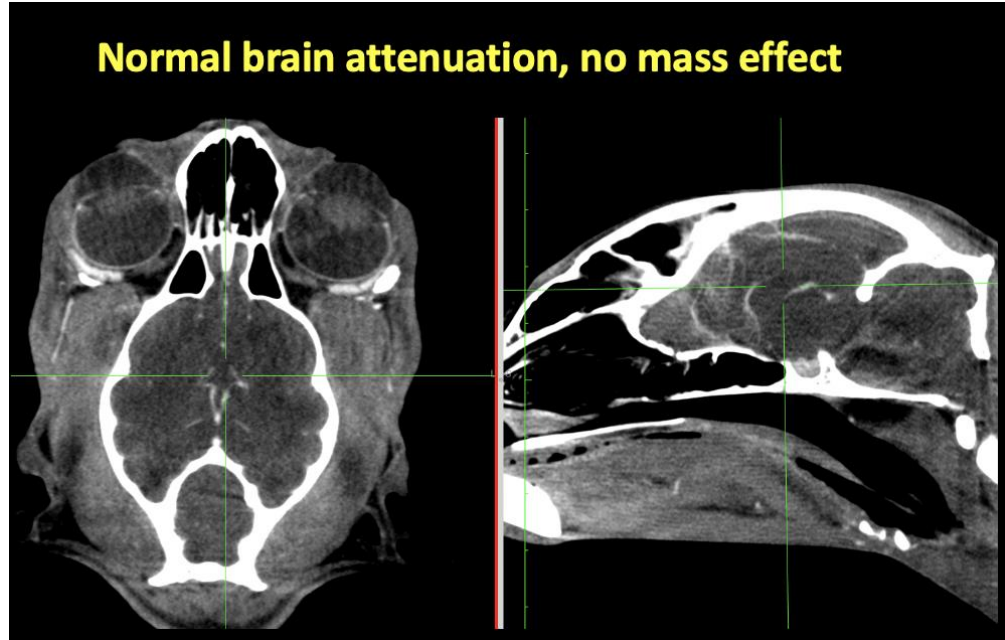
DSH

SEX

MN

AGE

3 Years, 7 Months



Normal brain attenuation, no mass effect

The information and recommendations provided are based on the images presented by the referring veterinarian. No evaluation can be communicated regarding pathology that was not visible in the image/video clips provided.

INTERPRETED BY

Tilde Rodrigues Froes,
DMV, MSc., Dr. Med
Vet., Dipl. CBraRVet

Thank you for this referral. If the clinical or image interpretation does not parallel your findings or if I can be of any further assistance please contact me.

HOSPITAL NAME

Casselton Vet Service

Tilde Rodrigues Froes, DMV, MSc., Dr. Med.Vet., Dipl.CBraRVet
info@sonopath.com

REFERRING VET

Dr. Brad Bartholomay

INVOICE

58905

DATE

6-20-23