



PATIENT PRESENTING CLINICAL SIGNS

Freckles Sullivan Very painful when opening mouth. R/O: masticatory myositis. Bloodwork NSF. Mildly responsive to Prednisolone, azathioprine

SPECIES RADIOGRAPHIC STUDY OF THE HEAD

Canine Orthogonal views of the head are provided for review totaling 6 images. Two lateral views, three temporomandibular oblique, and one open mouth bullae view.

BREED RADIOGRAPHIC FINDINGS

Border Collie Mix There is incongruency of the left temporomandibular joint, better seen in the oblique views. No evidence of remodeling of the ipsilateral condylar process of the mandibula. The right temporomandibular joint is congruent.

SEX No evidence of acute traumatic abnormalities in the mandibulae or maxillae.

Female Spayed No missing teeth are noted in the maxillary and mandibular arcades.

The visible portion of the nasal cavity is normal.

AGE The nasopharynx and larynx are unremarkable.

5 Years The tympanic bullae are normal.

INTERPRETED BY Note: an endotracheal tube is seen, correlated to the anesthesia procedure for the x-ray exam.

Tilde Rodrigues Froes,
DMV, MSc., Dr. Med
Vet., Dipl. CBraRVet

RADIOGRAPHIC DIAGNOSIS

- Incongruency of the left temporomandibular joint, no evidence of concurrent degenerative joint disease. The differential diagnosis includes positional artifact.
- No fractures or complete luxation are identified.
- Otherwise, normal head.

HOSPITAL NAME

Mt. Yonah Animal
Hospital

INTERPRETATION OF THE FINDINGS & FURTHER RECOMMENDATIONS

The identified incongruency of the left temporomandibular joint could or could not be associated with the clinical signs. If the pain is persistent, continuing investigation for masticatory myositis is suggested, for example, with an antibody associated with masticatory myositis called the 2M antibody. If any muscle asymmetry is identified, possible trigeminal nerve involvement could be considered a potential diagnosis, and in this case, an MRI or computed tomography is suggested.

REFERRING VET

Ashley Douglass,
DVM

INVOICE

58907

DATE

6-20-23



PATIENT

Freckles Sullivan

SPECIES

Canine

BREED

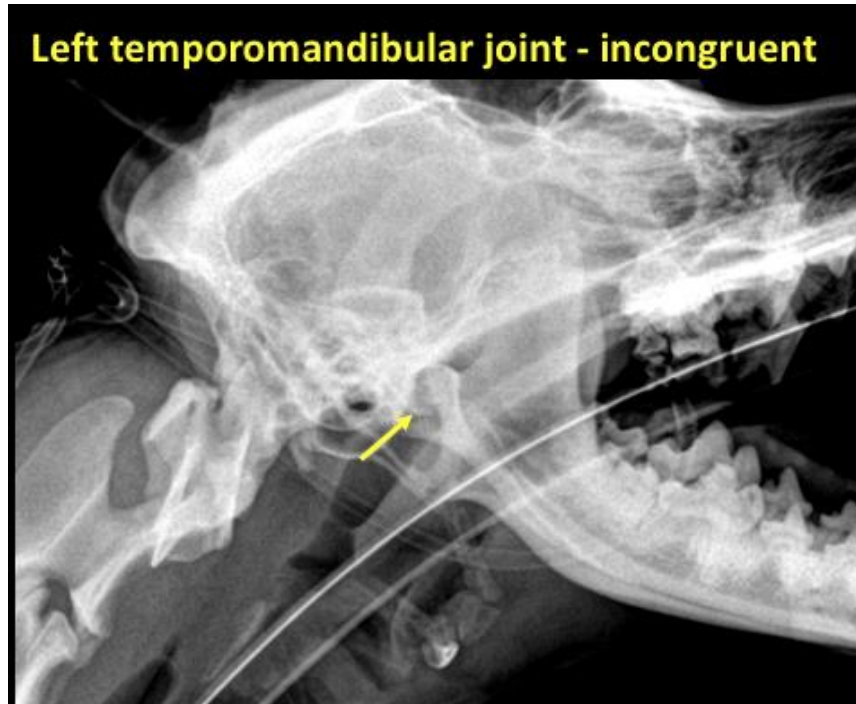
Border Collie Mix

SEX

Female Spayed

AGE

5 Years



INTERPRETED BY

Tilde Rodrigues Froes,
DMV, MSc., Dr. Med
Vet., Dipl. CBraRVet

HOSPITAL NAME

Mt. Yonah Animal
Hospital

REFERRING VET

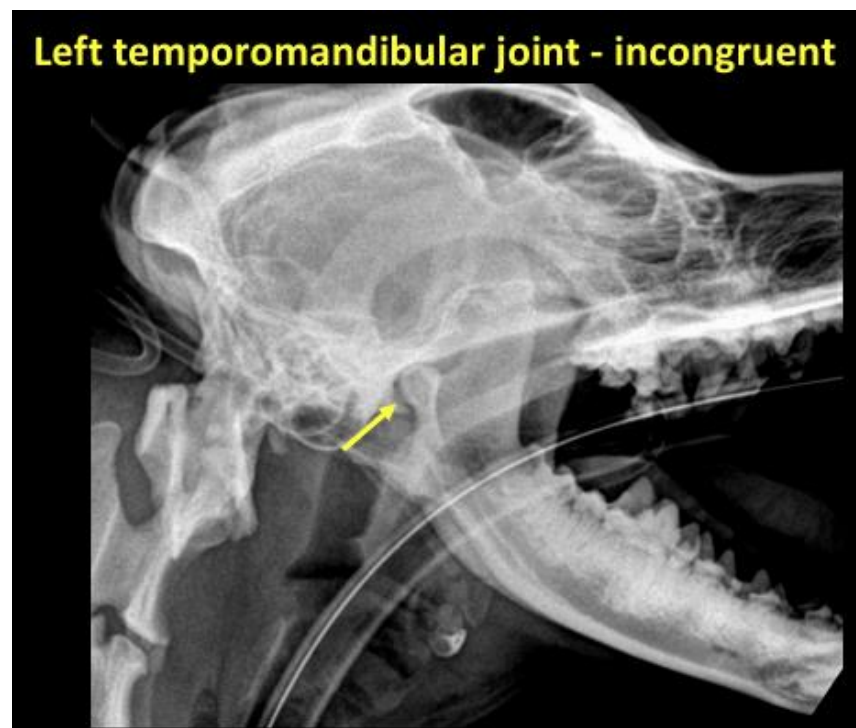
Ashley Douglass,
DVM

INVOICE

58907

DATE

6-20-23





PATIENT

Freckles Sullivan

SPECIES

Canine

BREED

Border Collie Mix

SEX

Female Spayed

AGE

5 Years

INTERPRETED BY

Tilde Rodrigues Froes,
DMV, MSc., Dr. Med
Vet., Dipl. CBraRVet

HOSPITAL NAME

Mt. Yonah Animal
Hospital

REFERRING VET

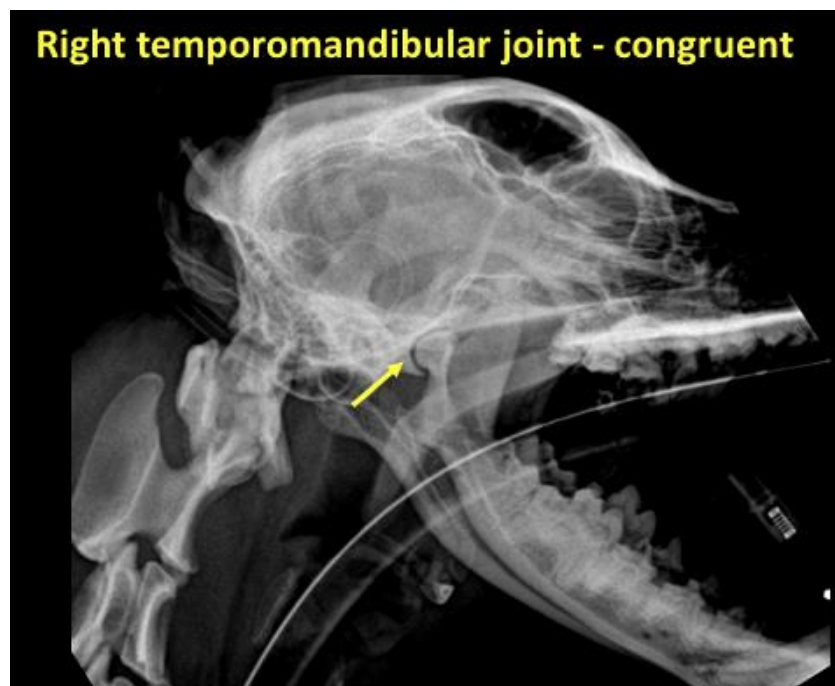
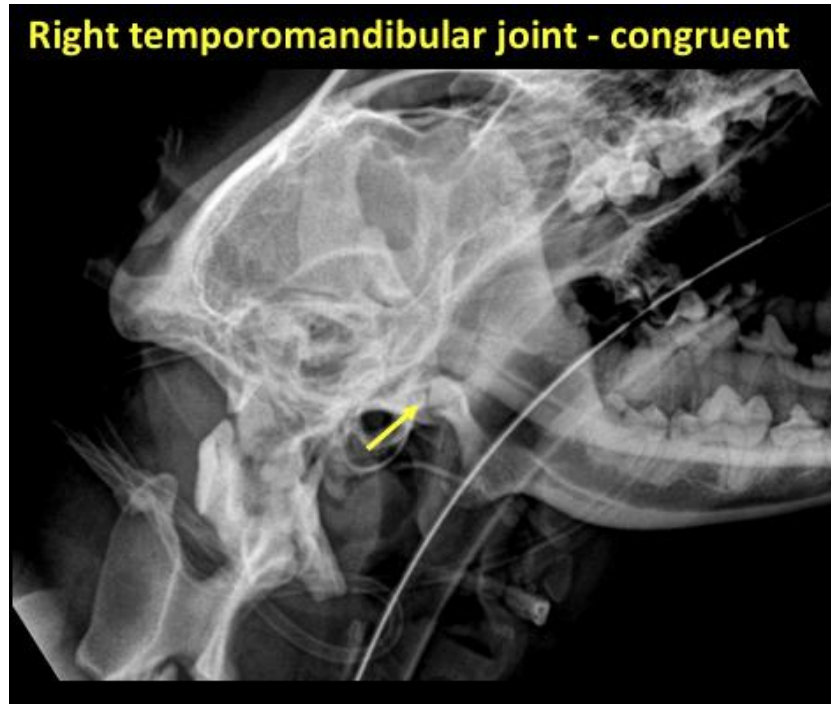
Ashley Douglass,
DVM

INVOICE

58907

DATE

6-20-23





PATIENT

Freckles Sullivan

SPECIES

Canine

The information and recommendations provided are based on the images presented by the referring veterinarian. No evaluation can be communicated regarding pathology that was not visible in the image/video clips provided.

Thank you for this referral. If the clinical or image interpretation does not parallel your findings or if I can be of any further assistance please contact me.

BREED

Border Collie Mix

Tilde Rodrigues Froes, DMV, MSc., Dr. Med.Vet., Dipl.CBraRVet
info@sonopath.com

SEX

Female Spayed

AGE

5 Years

INTERPRETED BY

Tilde Rodrigues Froes,
DMV, MSc., Dr. Med
Vet., Dipl. CBraRVet

HOSPITAL NAME

Mt. Yonah Animal
Hospital

REFERRING VET

Ashley Douglass,
DVM

INVOICE

58907

DATE

6-20-23