



PATIENT PRESENTING CLINICAL SIGNS

PATIENT Addy Visentine Dx with Lymphoma and went thru chemo - CHOP protocol successfully went into remission. Finished Chemo Feb 7, 2023; recently there has been some soft coughing especially after eating and drinking; all external LN are normal

SPECIES Abnormal PE/Chem/CBC/UA Results: X-rays - please review - concern for the hilar region and the bronchus - see attached

Canine

RADIOGRAPHIC STUDY OF THE THORAX

BREED Radiographs of the thorax, in three imaging planes are provided for review, right lateral, left lateral and two ventral dorsal views, totaling 4 images.

Bernese Mix

RADIOGRAPHIC FINDINGS

SEX A rounded, opaque soft tissue mass is noted in the cranial mediastinum, displacing the trachea dorsally and bordering the base of the cardiac silhouette. The mass measures approximately 4.1cm by 4.5cm.

FS

Another lobular mass effect is noted bordering and effacing the caudal thoracic trachea/carina and perihilar region.

AGE

8 Years

The cardiac silhouette spans approximately 55% of the thoracic width, 3.0 intercostal spaces, with normal shape and contour. The pulmonary vessels are normal.

The pulmonary parenchyma is normal in opacity.

INTERPRETED BY

Tilde Rodrigues Froes, DMV, MSc., Dr. Med Vet., Dipl. CBraRVet

The pleural space is unremarkable.

The diaphragm is unremarkable.

Incomplete bridging spondylosis deformans is seen at T3-T4, T4-T5 and T5-T6.

HOSPITAL NAME

Petworks Veterinary Hospital

The collimated abdomen is normal.

RADIOGRAPHIC DIAGNOSIS

- Cranial mediastinal and tracheobronchial lymphadenopathy is consistent with recurrence of neoplastic process, lymphoma.
- Multifocal incidental thoracic spondylosis deformans.

REFERRING VET

Dr Trudeau

INTERPRETATION OF THE FINDINGS & FURTHER RECOMMENDATIONS

INVOICE

58909

The thoracic radiographs show a recurrence of the lymphoma. The present clinical signs of coughing, especially after eating and drinking, are likely correlated with the mass effect in the region of the carina.

DATE

6-20-23



PATIENT

Addy Visentine

SPECIES

Canine

BREED

Bernese Mix

SEX

FS

AGE

8 Years

INTERPRETED BY

Tilde Rodrigues Froes,
DMV, MSc., Dr. Med
Vet., Dipl. CBraRVet

HOSPITAL NAME

Petworks Veterinary
Hospital

REFERRING VET

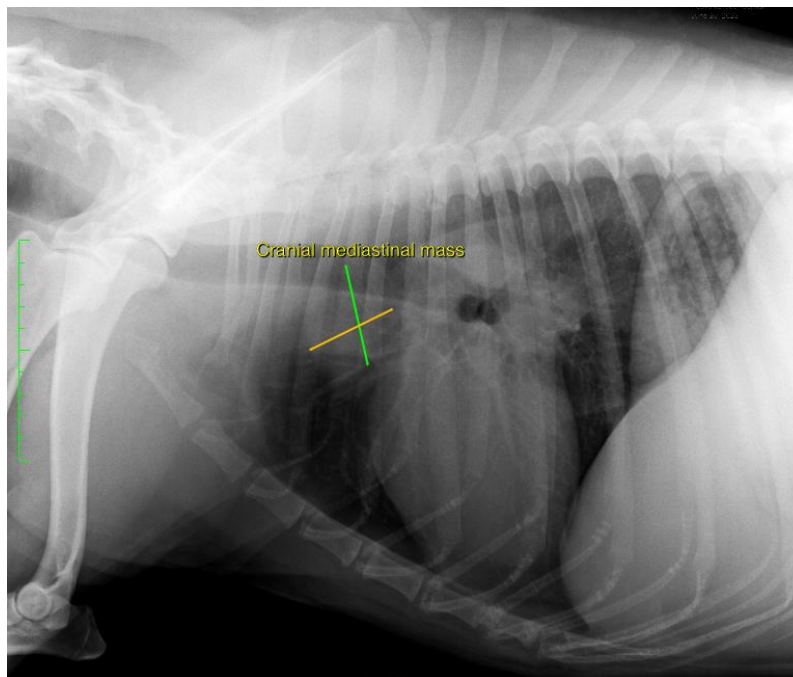
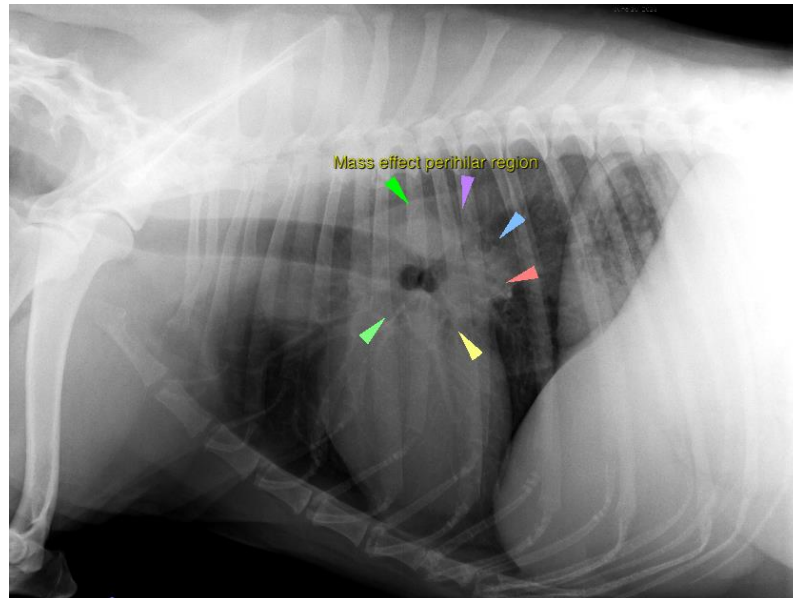
Dr Trudeau

INVOICE

58909

DATE

6-20-23





PATIENT

Addy Visentine

The information and recommendations provided are based on the images presented by the referring veterinarian. No evaluation can be communicated regarding pathology that was not visible in the image/video clips provided.

SPECIES

Canine

Thank you for this referral. If the clinical or image interpretation does not parallel your findings or if I can be of any further assistance please contact me.

Tilde Rodrigues Froes, DMV, MSc., Dr. Med.Vet., Dipl.CBraRVet
info@sonopath.com

BREED

Bernese Mix

SEX

FS

AGE

8 Years

INTERPRETED BY

Tilde Rodrigues Froes,
DMV, MSc., Dr. Med
Vet., Dipl. CBraRVet

HOSPITAL NAME

Petworks Veterinary
Hospital

REFERRING VET

Dr Trudeau

INVOICE

58909

DATE

6-20-23