



PATIENT

Moose Van Wyk

SPECIES

Canine

BREED

Labrador Retriever

SEX

MN

AGE

6Y

WEIGHT

135lbs

INTERPRETED BY

Tilde Rodrigues Froes,
DMV, MSc., Dr. Med
Vet., Dipl. CBraRVet

IMAGING PERFORMED BY

Dr. Amanda Causey

HOSPITAL NAME

Heron Lakes Animal
Hospital

REFERRING VET

Dr. Lera

INVOICE

75531

DATE

6-17-26

PRESENTING CLINICAL SIGNS

On/off lameness front left limb.

Pain on flexion of left shoulder. Reduced range of motion in the cervical spine with pain on flexion and rotation to both left and the right sides.

COMPUTED TOMOGRAPHIC STUDY OF THE NECK (CERVICAL SPINE) & SHOULDER JOINTS

A pre- and post- contrast CT study of the cervicothoracic spine and shoulder joints are provided for review. Transverse, bone algorithm.

COMPUTED TOMOGRAPHIC FINDINGS

CERVICAL SPINE

Seven cervical vertebrae are present with normal vertebral alignment.

Discrete incomplete bridging ventral spondylosis deformans at C6-7.

Remaining cervical and included cranial thoracic vertebral bodies are normal in size, shape, and attenuation. Articular facet joints are unremarkable.

Vertebral canal is normal in diameter without evidence of osseous stenosis.

No aggressive osseous lesions or lytic/proliferative changes are identified.

Cervical soft tissues, including the salivary glands, thyroid glands, medial retropharyngeal lymph nodes, trachea, esophagus, and major cervical vessels, are unremarkable.

SHOULDER JOINTS

Focal mineralization adjacent to the greater tubercle of the right humerus, within the region of the infraspinatus tendon insertion, associated with a small adjacent subchondral cystic change (microcyst).

Right glenohumeral joint remains congruent. The scapula is unremarkable.

Left shoulder joint and adjacent soft tissues are unremarkable. The left scapula and humerus is unremarkable.

The axillary lymph nodes are unremarkable.

COMPUTED TOMOGRAPHIC DIAGNOSIS

- Discrete C6–C7 spondylosis deformans. Otherwise, normal cervical spine.
- Focal mineralization adjacent to the greater tubercle of the right humerus, in the region of the infraspinatus tendon insertion, with a small adjacent subchondral cystic change; likely chronic and incidental.
- No CT abnormality identified in the left shoulder.
- No evidence of aggressive osseous disease or cervical vertebral canal stenosis.



PATIENT

Moose Van Wyk

SPECIES

Canine

BREED

Labrador Retriever

SEX

MN

AGE

6Y

WEIGHT

135lbs

INTERPRETED BY

Tilde Rodrigues Froes,
DMV, MSc., Dr. Med
Vet., Dipl. CBraRVet

IMAGING PERFORMED BY

Dr. Amanda Causey

HOSPITAL NAME

Heron Lakes Animal
Hospital

REFERRING VET

Dr. Lera

INVOICE

75531

DATE

6-17-26

INTERPRETATION OF THE FINDINGS & FURTHER RECOMMENDATIONS

The mild C6–C7 spondylosis deformans is considered an incidental age-related degenerative finding.

Focal mineralization adjacent to the right greater tubercle represents a chronic incidental finding, not necessarily associated with possible lameness.

No CT abnormality is identified to explain the patient's left shoulder pain or intermittent left forelimb lameness. If clinical suspicion persists, shoulder ultrasonography or MRI may be considered for further assessment.

Fig. 1. Discrete C6–C7 spondylosis deformans

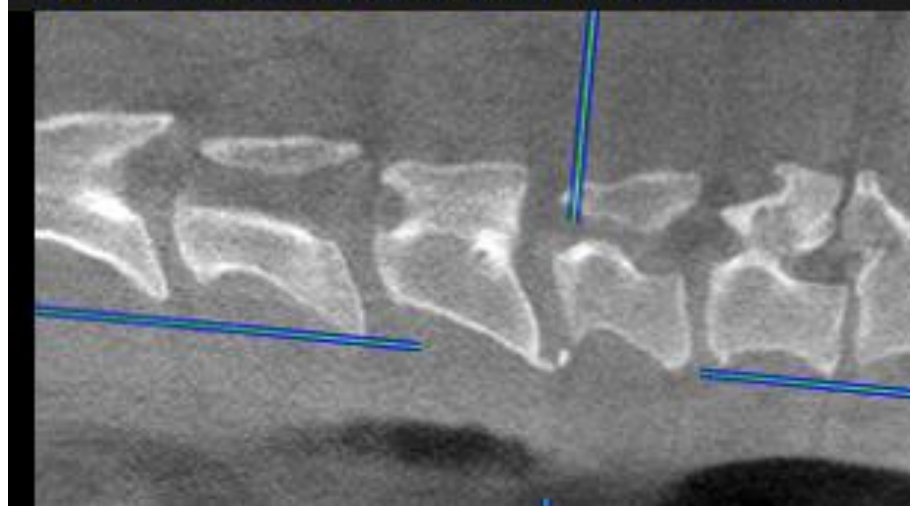
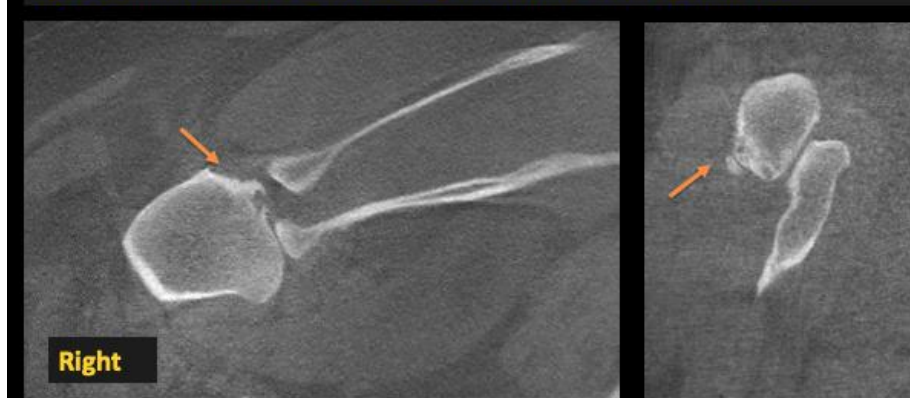


Fig 2. Focal mineralization adjacent to the greater tubercle of the right humerus





PATIENT

Moose Van Wyk

SPECIES

Canine

BREED

Labrador Retriever

SEX

MN

AGE

6Y

WEIGHT

135lbs

INTERPRETED BY

Tilde Rodrigues Froes,
DMV, MSc., Dr. Med
Vet., Dipl. CBraRVet

IMAGING PERFORMED BY

Dr. Amanda Causey

HOSPITAL NAME

Heron Lakes Animal
Hospital

REFERRING VET

Dr. Lera

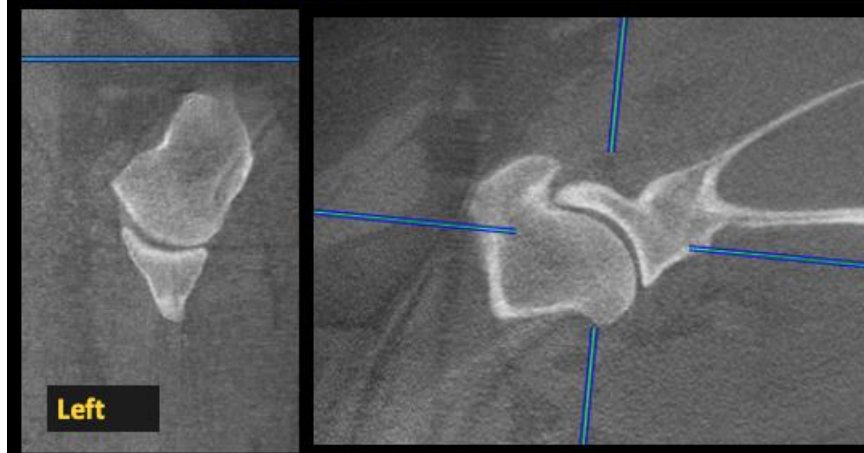
INVOICE

75531

DATE

6-17-26

Fig.3 . Normal left shoulder joint



The information and recommendations provided are based on the images presented by the referring veterinarian. No evaluation can be communicated regarding pathology that was not visible in the image/video clips provided.

Thank you for this referral. If the clinical or image interpretation does not parallel your findings or if I can be of any further assistance, please contact me.

Tilde Rodrigues Froes, DMV, MSc., Dr. Med.Vet., Dipl.CBraRVet
info@sonopath.com