



PATIENT

Faye Richards

SPECIES

Canine

BREED

Beagle

SEX

FS

AGE

6

WEIGHT

18.5

INTERPRETED BY

Tilde Rodrigues Froes,
DMV, MSc., Dr. Med
Vet., Dipl. CBraRVet

IMAGING PERFORMED BY

Henry Xue

HOSPITAL NAME

Belconnen Veterinary
Centre

REFERRING VET

Henry Xue

INVOICE

75528

DATE

6-16-26

PRESENTING CLINICAL SIGNS

same history as last submission, this is for extra region interpretation
Abnormal PE/Chem/CBC/UA Results: elevated iCa 1.53 (normal range 1.2-

COMPUTED TOMOGRAPHIC STUDY OF THE ABDOMEN

A pre- and post-contrast CT study of the abdomen is provided for review totaling 5 series. One pre-contrast series of the whole body (soft tissue algorithm). one pre-contrast series of the thorax (lung algorithm). One pre-contrast series of the whole body (bone algorithm). One pre-contrast series of the whole body (bone algorithm). One post-contrast series of the whole body (soft tissue algorithm).

COMPUTED TOMOGRAPHIC FINDINGS

The liver is normal in size, shape, attenuation, and contrast enhancement. The gallbladder, cystic duct, and common bile duct are unremarkable.

The spleen is normal in size and demonstrates homogeneous attenuation and enhancement.

The adrenal glands are bilaterally small and mildly flattened, measuring approximately 1.4 × 0.43 cm (right) and 1.0 × 0.43 cm (left). The glands are otherwise homogeneous and normally contrast-enhancing.

The pancreas and abdominal lymph nodes are within normal limits

Both kidneys are normal in size, shape, attenuation, and enhancement. The renal pelves and ureters are within normal limits.

The urinary bladder is moderately distended with fluid and has a normal wall thickness. The stomach is moderately distended with fluid and gas. Wall thickness is normal.

The small intestine is nondilated with normal wall thickness.

The colon and rectum contain gas and fecal material without mural abnormality.

The anal sacs are mildly to moderately distended and contain small mineral foci admixed with fluid attenuation material, consistent with incidental inspissated/mineralized secretions. The anal sac walls are smooth and well-defined. No mural thickening, soft tissue mass, abnormal contrast enhancement, or associated lymphadenopathy is identified.

The serosal fat shows normal attenuation.

Mild right L2-L3 articular facet osteoarthritis and mild incomplete bridging spondylosis deformans at T12-T13 are noted incidentally.

COMPUTED TOMOGRAPHIC DIAGNOSIS

- No significant tomographic abnormalities identified within the abdomen.
- Mild bilateral adrenal gland atrophy (small, flattened adrenal glands).
- Mild bilateral anal sac distension containing inspissated secretions with small mineral foci, without CT evidence of anal sac mass effect or abnormalities.



PATIENT

Faye Richards

SPECIES

Canine

BREED

Beagle

SEX

FS

AGE

6

WEIGHT

18.5

INTERPRETED BY

Tilde Rodrigues Froes,
DMV, MSc., Dr. Med
Vet., Dipl. CBraRVet

**IMAGING
PERFORMED BY**

Henry Xue

HOSPITAL NAME

Belconnen Veterinary
Centre

REFERRING VET

Henry Xue

INVOICE

75528

DATE

6-16-26

- Mild incidental right L2–L3 facet osteoarthritis and incomplete bridging spondylosis deformans at T12–T13.

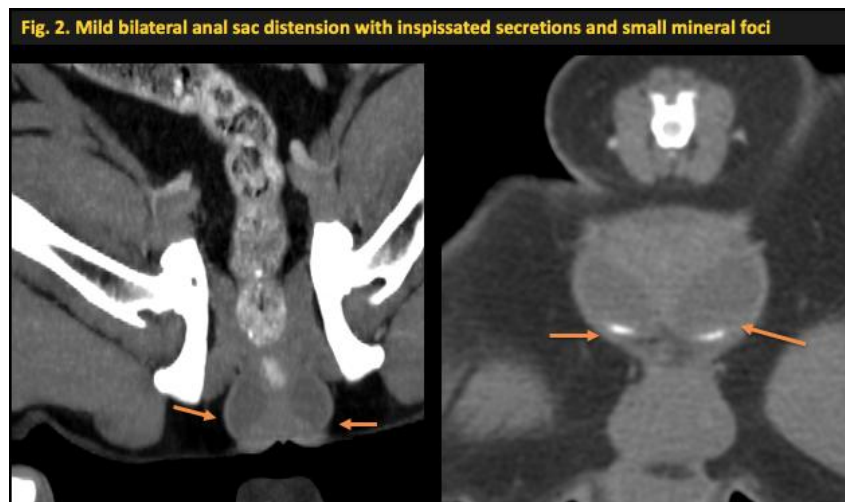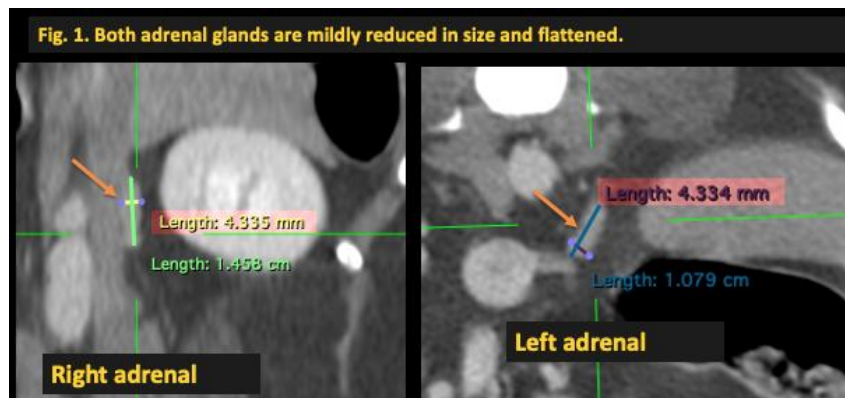
INTERPRETATION OF THE FINDINGS & FURTHER RECOMMENDATIONS

No abdominal mass or metastatic disease is identified to explain the mild ionized hypercalcemia.

Specifically, there is no CT evidence of anal sac lesion, as the anal sacs demonstrate only mild distension with mineralized/inspissated secretions and have smooth, well-defined walls without an enhancing soft tissue mass, local invasion, or regional lymphadenopathy.

Both adrenal glands are mildly reduced in size and flattened. Although this finding is nonspecific, it may be compatible with adrenal atrophy and should be interpreted in conjunction with the clinical presentation and endocrine testing. Hypoadrenocorticism may be associated with mild hypercalcemia in some dogs and should be considered if supported by the clinical and clinicopathologic findings.

Correlation with serum electrolytes and adrenal function testing (basal cortisol concentration and/or ACTH stimulation test, as clinically indicated) is recommended if hypoadrenocorticism is suspected.





PATIENT

Faye Richards

SPECIES

Canine

BREED

Beagle

SEX

FS

AGE

6

WEIGHT

18.5

INTERPRETED BY

Tilde Rodrigues Froes,
DMV, MSc., Dr. Med
Vet., Dipl. CBraRVet

IMAGING PERFORMED BY

Henry Xue

HOSPITAL NAME

Belconnen Veterinary
Centre

REFERRING VET

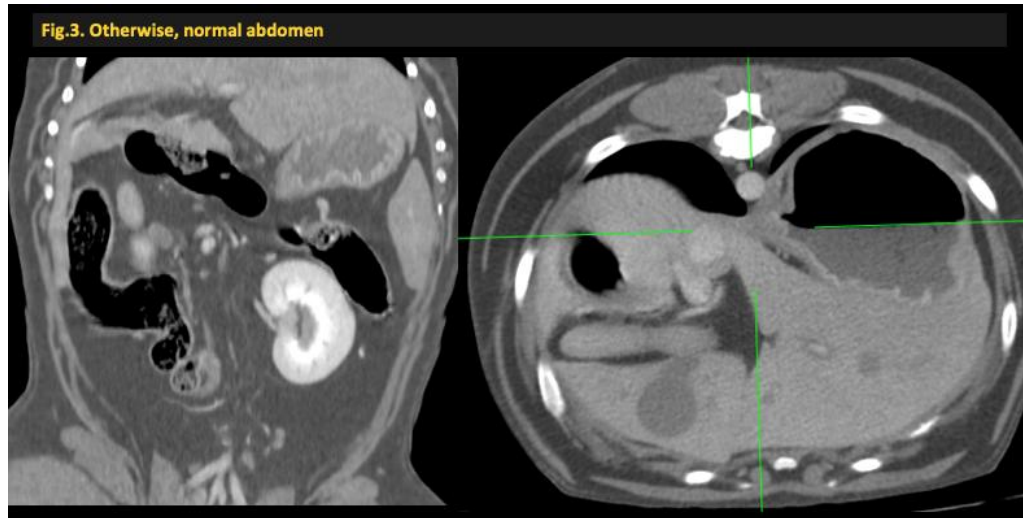Henry Xue

INVOICE

75528

DATE

6-16-26



The information and recommendations provided are based on the images presented by the referring veterinarian. No evaluation can be communicated regarding pathology that was not visible in the image/video clips provided.

Thank you for this referral. If the clinical or image interpretation does not parallel your findings or if I can be of any further assistance, please contact me.

Tilde Rodrigues Froes, DMV, MSc., Dr. Med.Vet., Dipl.CBraRVet
info@sonopath.com