



PATIENT PRESENTING CLINICAL SIGNS

Laxmi Aghera 1 month hx of coughing and sneezing. Non responsive to doxy, prednisone, no heart murmur ausculted. no cough elicited on tracheal palpation.

SPECIES RADIOGRAPHIC STUDY OF THE THORAX

Canine Orthogonal views of the thorax are provided for review totaling three images. One right lateral, one left lateral and one ventral dorsal view.

BREED RADIOGRAPHIC FINDINGS

Bichon Frise The cervical and thoracic trachea is normal.

There is a diffuse mild bronchial pattern throughout the pulmonary parenchyma.

SEX The cardiac silhouette spans approximately 50% of the thoracic width, 3.0 intercostal spaces, with normal shape. (VHS = 10.9). The pulmonary vessels are normal.

SF The pleural space and mediastinum are normal.

AGE The diaphragm is normal.

12 Years, 7 Months The collimated abdomen is unremarkable.

The musculoskeletal structures are unremarkable.

INTERPRETED BY

Tilde Rodrigues Froes, DMV, MSc., Dr. Med Vet., Dipl. CBraRVet

RADIOGRAPHIC DIAGNOSIS

- Mild diffuse bronchial pulmonary pattern. The differential diagnosis includes allergic lower airway disease, chronic bronchitis, infectious bronchitis. No evidence of bronchopneumonia.

HOSPITAL NAME

Claws N Paws Animal Hospital

INTERPRETATION OF THE FINDINGS & FURTHER RECOMMENDATIONS

The pulmonary radiographic findings explain the clinical signs of coughing. Continue medical treatment for allergic/inflammatory bronchitis. The association of inhalable agents (e.g., budesonide or fluticasone) could be used as an alternative. If patient does not improve, consider bronchoalveolar lavage for obtaining samples for cytology, culture, and sensitivity.

REFERRING VET

Nitin Singh

INVOICE

58846

DATE

6-15-23



PATIENT

Laxmi Aghera

SPECIES

Canine

BREED

Bichon Frise

SEX

SF

AGE

12 Years, 7 Months

INTERPRETED BY

Tilde Rodrigues Froes,
DMV, MSc., Dr. Med
Vet., Dipl. CBraRVet

HOSPITAL NAME

Claws N Paws Animal
Hospital

REFERRING VET

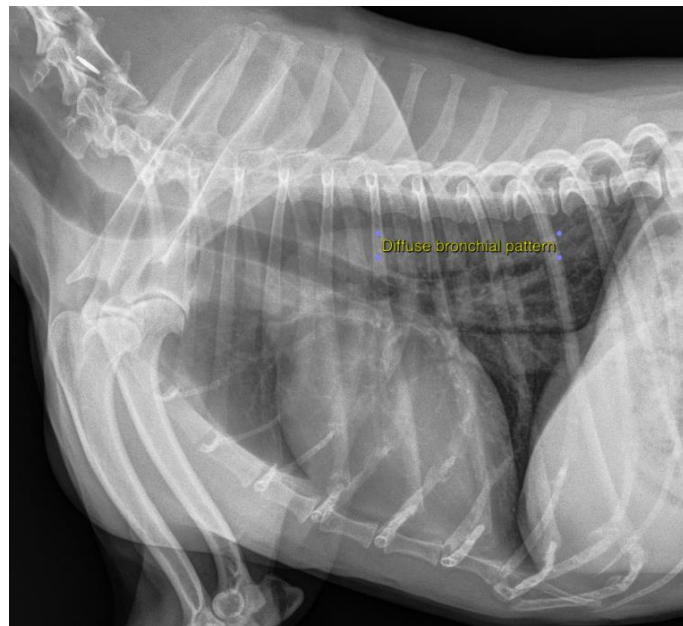
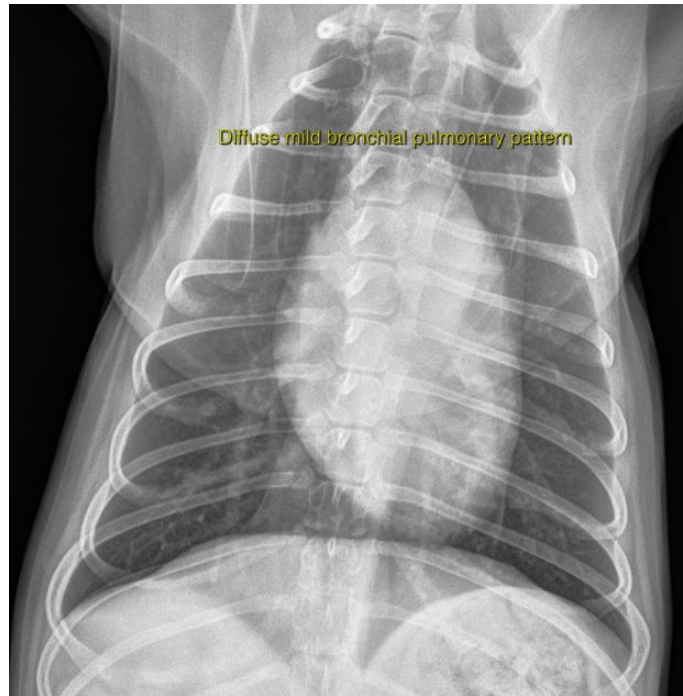
Nitin Singh

INVOICE

58846

DATE

6-15-23





PATIENT

Laxmi Aghera

SPECIES

Canine

BREED

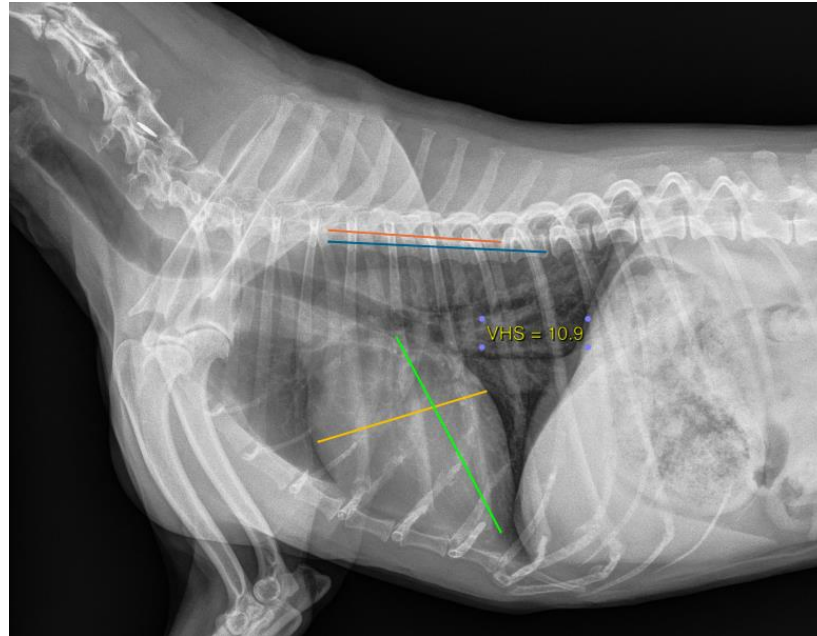
Bichon Frise

SEX

SF

AGE

12 Years, 7 Months



INTERPRETED BY

Tilde Rodrigues Froes,
DMV, MSc., Dr. Med
Vet., Dipl. CBraRVet

The information and recommendations provided are based on the images presented by the referring veterinarian. No evaluation can be communicated regarding pathology that was not visible in the image/video clips provided.

Thank you for this referral. If the clinical or image interpretation does not parallel your findings or if I can be of any further assistance please contact me.

HOSPITAL NAME

Claws N Paws Animal
Hospital

Tilde Rodrigues Froes, DMV, MSc., Dr. Med.Vet., Dipl.CBraRVet
info@sonopath.com

REFERRING VET

Nitin Singh

INVOICE

58846

DATE

6-15-23