



**PATIENT PRESENTING CLINICAL SIGNS**

Zen Smith On 4/24/23 O reports that 4 weeks ago did a surgery removing an abscess and they looked at his eye and saw a pea size lump on eye and was bleeding on the right eye and skin is turning black and blue  
 Eyes: OD- periorbital swelling and serosal discharge 0.5x0.5 cm mass on the ventral aspect of the right eye was noted. left eye wnl. Assessment: peri orbital swelling/mass r/o abscess vs tooth root abscess vs neoplasia. hypothyroidism  
 Canine Abnormal PE/Chem/CBC/UA Results: 5/20/23 CBC/CHEM elevated ALT 230 elevated ALP 207

**BREED**

Yorkshire Terrier

**COMPUTED TOMOGRAPHIC STUDY OF THE HEAD**

A post-contrast CT study of the head are provided for review totaling one series. One post-contrast series, soft tissue algorithm.

**COMPUTED TOMOGRAPHIC FINDINGS**

**SEX**

Male Neutered

There is a large, focal, irregular, demarcated geographic lysis associated with the root of the triadan 108. In addition, an osteolytic portion of the maxilla is seen at the lateral external border with focal increased soft tissue volume, swelling, and focal enhanced attenuation.

**AGE**

5 Years, 7 Months

The retrobulbar spaces are unremarkable, bilaterally.

The right parotid lymph node is enlarged and rounded in shape, normal attenuation.

Absent triadans include 105, 106, 107, 110, 205, 207, 210, 405, 311, and 411. There is diffuse horizontal and vertical bone loss along the remaining maxillary and mandibular teeth.

**INTERPRETED BY**

Tilde Rodrigues Froes, DMV, MSc., Dr. Med Vet., Dipl. CBraRVet

The cribriform plate is intact.

The frontal sinuses are rudimentary, incidental.

The tympanic bullae and external auditory canals are normal.

**HOSPITAL NAME**

Animal Surgical Center

The right parotid lymph node is enlarged and rounded with homogenous attenuation. The medial retropharyngeal lymph nodes and mandibular lymph nodes are mildly enlarged, with homogeneous attenuation.

No mass effect or abnormal attenuation is seen in the brain.

**REFERRING VET**

Noah's Ark Veterinary Practice

**COMPUTED TOMOGRAPHIC DIAGNOSIS**

- Periapical lesion adjacent to the root of the triadan 108, with regional cellulitis and swelling. Differential diagnosis, concurrent focal maxilla osteomyelitis.
- Diffuse periodontal disease.
- Absent teeth, triadans 105, 106, 107, 110, 205, 207, 210, 405, 311, 411.
- Mild enlargement of the right parotid lymph node, retropharyngeal lymph nodes and mandibular lymph nodes, reactive.

**INVOICE**

58790

**DATE**

6-13-23



**PATIENT INTERPRETATION OF THE FINDINGS & FURTHER RECOMMENDATION**

**Zen Smith** A pea-sized lump with increased volume adjacent to the right eye and periorbital swelling is likely correlated to the identified tomographic periapical abscess of the triadan 108 and corresponds to the clinical suspicion.

**SPECIES**  
Canine A dental exam and odontology treatment, including a more invasive approach, could be necessary for treatment, and a specialist consult is suggested because usually the treatment requires the extraction of the 108 tooth. Concurrent medical management can be instituted temporally with broad-spectrum antibiotics and analgesics.

**BREED**  
Yorkshire Terrier There is no evidence of a retrobulbar abscess; however, some patients with an advanced dental disease could develop concurrent uveitis. An ophthalmologic exam is suggested.

**SEX**

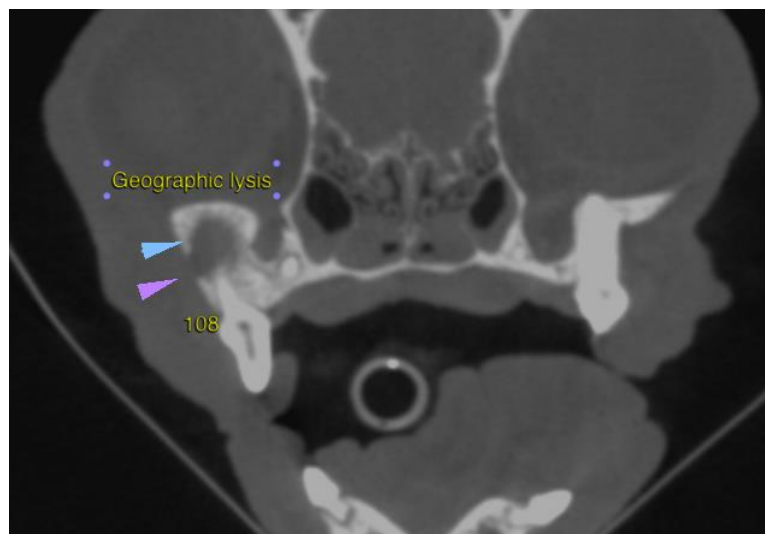
Male Neutered

**AGE**

5 Years, 7 Months

**INTERPRETED BY**

Tilde Rodrigues Froes, DMV, MSc., Dr. Med Vet., Dipl. CBraRVet

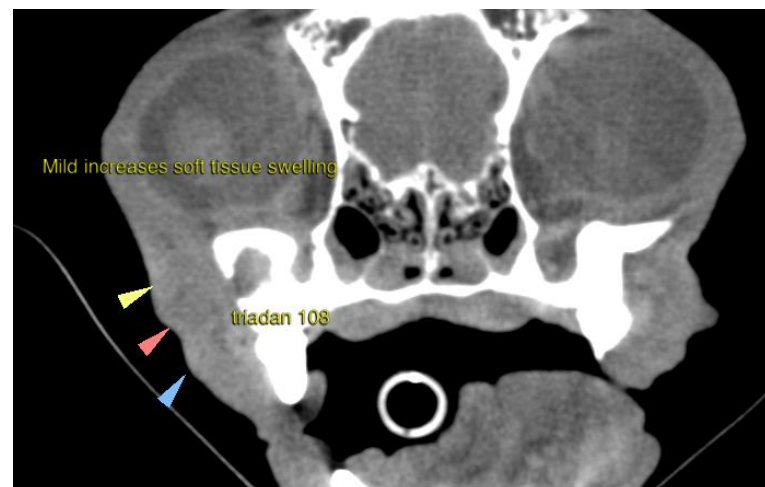


**HOSPITAL NAME**

Animal Surgical Center

**REFERRING VET**

Noah's Ark Veterinary Practice



**INVOICE**

58790

**DATE**

6-13-23



**PATIENT**

Zen Smith

**SPECIES**

Canine

**BREED**

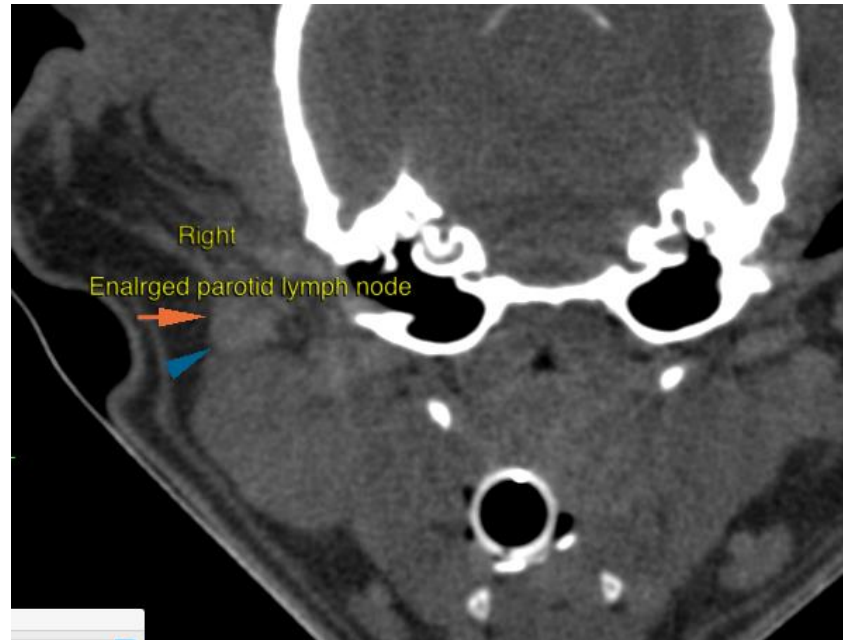
Yorkshire Terrier

**SEX**

Male Neutered

**AGE**

5 Years, 7 Months



The information and recommendations provided are based on the images presented by the referring veterinarian. No evaluation can be communicated regarding pathology that was not visible in the image/video clips provided.

**INTERPRETED BY**

Tilde Rodrigues Froes,  
DMV, MSc., Dr. Med  
Vet., Dipl. CBraRVet

Thank you for this referral. If the clinical or image interpretation does not parallel your findings or if I can be of any further assistance please contact me.

**Tilde Rodrigues Froes, DMV, MSc., Dr. Med.Vet., Dipl.CBraRVet**  
info@sonopath.com

**HOSPITAL NAME**

Animal Surgical  
Center

**REFERRING VET**

Noah's Ark  
Veterinary Practice

**INVOICE**

58790

**DATE**

6-13-23