



PATIENT PRESENTING CLINICAL SIGNS

Xavier Marcelletti Pet presented 4/10/23 for coughing, sneezing, and hacking for 6-8 months. About 3 times a week. No change in litter, owner smokes in home. During exam pet was found to have a heart murmur grade 2 out of 6. Took blood at this time, recommended x-rays and ultrasound. Were not performed at this time. Pet returned 5/18/23 for ongoing sneezing and coughing. Gave Orbax suspension 20mL (1.4mL once daily until gone). Pet returned 6/13/23, same symptoms no improvement. Orbax did not help. Feline Took digital radiographs today and administered 0.5 mL Depo Medrol 40mg/ml. Abnormal PE/Chem/CBC/UA Results: High Triglycerides; range between 25-160, pet's values were 260.

BREED RADIOGRAPHIC STUDY OF THE THORAX

Don Sphynx Orthogonal views of the thorax are available for review totaling 3 images. One ventrodorsal view, one left lateral view and one right lateral view. The ventrodorsal view is mildly oblique.

SEX RADIOGRAPHIC FINDINGS

Male Neutered The trachea is normal.

AGE There is a diffuse bronchial pattern in the pulmonary parenchyma.
11 Years, 2 Months The cardiac silhouette is of normal size and shape. The pulmonary vessels are normal.
The pleural space and mediastinum are normal.

INTERPRETED BY The diaphragm is normal.

Tilde Rodrigues Froes, DMV, MSc., Dr. Med Vet., Dipl. CBraRVet The collimated abdomen is unremarkable.
The musculoskeletal structures are unremarkable.
No other abnormalities are identified.

HOSPITAL NAME RADIOGRAPHIC DIAGNOSIS

Denville Animal Hospital

- Mild generalized bronchial pulmonary pattern, differential diagnosis includes allergic lower airway disease, chronic bronchitis, infectious bronchitis.
- Normal heart and pulmonary vessels.

REFERRING VET INTERPRETATION OF THE FINDINGS & FURTHER RECOMMENDATIONS

Doctor Reddy The pulmonary radiographic findings are correlated to the patient's history of coughing, sneezing, and hacking. There is no evidence of bronchopneumonia. Medical therapy is suggested. If the patient does not improve, a bronchoalveolar lavage may be useful in obtaining samples for cytology, culture, and sensitivity.

INVOICE 58799 Normal radiographic cardiac size: due to the identification of murmurs, the differential diagnosis includes cardiac disease at a stage not producing secondary radiographic changes. An echocardiogram is suggested for further evaluation.

DATE

6-13-23



PATIENT

Xavier Marcelletti

SPECIES

Feline

BREED

Don Sphynx

SEX

Male Neutered

AGE

11 Years, 2 Months

INTERPRETED BY

Tilde Rodrigues Froes,
DMV, MSc., Dr. Med
Vet., Dipl. CBraRVet

HOSPITAL NAME

Denville Animal
Hospital

REFERRING VET

Doctor Reddy

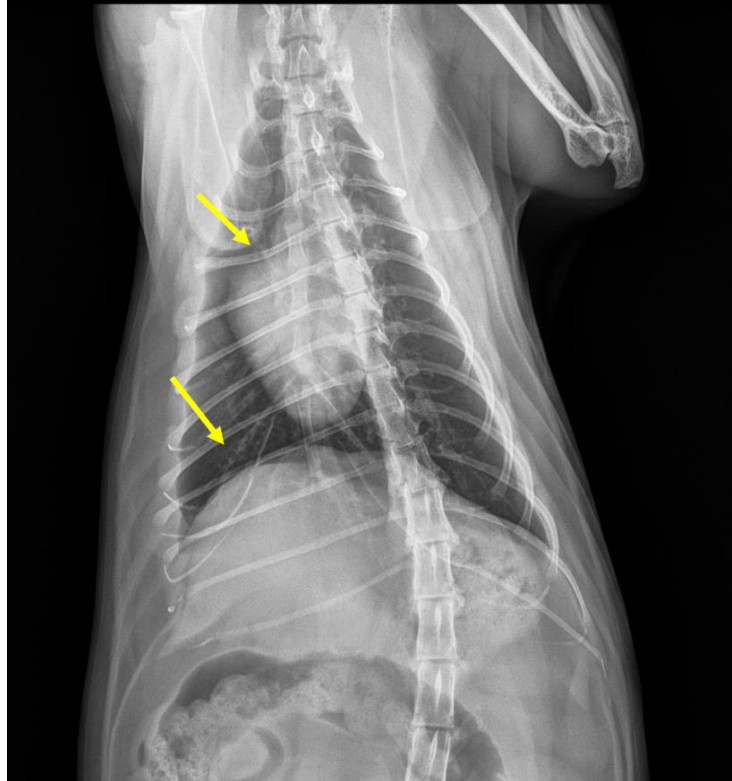
INVOICE

58799

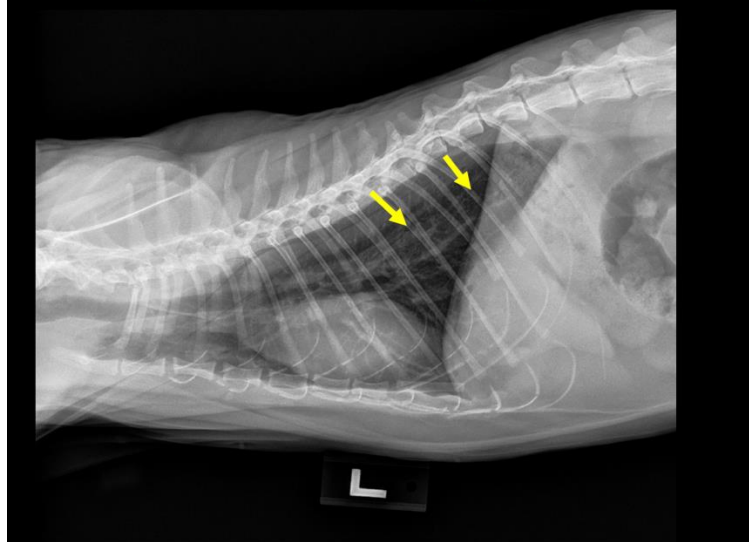
DATE

6-13-23

Mild diffuse bronchial pattern



Mild diffuse bronchial pattern





PATIENT

Xavier Marcelletti

SPECIES

Feline

The information and recommendations provided are based on the images presented by the referring veterinarian. No evaluation can be communicated regarding pathology that was not visible in the image/video clips provided.

BREED

Don Sphynx

Thank you for this referral. If the clinical or image interpretation does not parallel your findings or if I can be of any further assistance please contact me.

SEX

Male Neutered

Tilde Rodrigues Froes, DMV, MSc., Dr. Med.Vet., Dipl.CBraRVet
info@sonopath.com

AGE

11 Years, 2 Months

INTERPRETED BY

Tilde Rodrigues Froes,
DMV, MSc., Dr. Med
Vet., Dipl. CBraRVet

HOSPITAL NAME

Denville Animal
Hospital

REFERRING VET

Doctor Reddy

INVOICE

58799

DATE

6-13-23