



PATIENT

Merah Duclos

SPECIES

Canine

BREED

Lab

SEX

Female Spayed

AGE

8Y, 1M

WEIGHT

32kg

INTERPRETED BY

Tilde Rodrigues Froes,
DMV, MSc., Dr. Med
Vet., Dipl. CBraRVet

IMAGING PERFORMED BY

Lucy

HOSPITAL NAME

Bridgwater Veterinary
Hospital and Wellness
Centre

REFERRING VET

Dr. R Rentz

INVOICE

74915

DATE

5-6-26

PRESENTING CLINICAL SIGNS

Client noted limping on the LFL for a few months, but was intermittent. Around APR 20-24 was playing and landed, now NWB-WB lame on LFL. Elbow seems swollen. is otherwise completely normal. No hx of travel to Whiteshell/Ontario in the last 2 years. Physical examination revealed a weight-bearing lameness of the LFL. Patient prefers to not bear weight on the limb if possible. Holds it up when standing still. Distal humerus/elbow swollen, discomfort on palpation. Reduced flexion of the elbow on ROM. Radiographs revealed an osteoproliferative lesion of distal humerus - radiology consult with IDEXX suspected chronic flexor enthesopathy, potentially with an acute exacerbation or avulsion injury given the recent history of rough-housing; however, neoplasia/osteomyelitis are rule outs. Patient has been on gabapentin/metacam and has been resting; minimal response to treatment noted. Abnormal PE/Chem/CBC/UA Results: Globulin - high @ 47 Alkaline phosphatase - high @ 287

COMPUTED TOMOGRAPHIC STUDY OF THE THORACIC LIMBS - ELBOW JOINTS

Pre- and post-contrast series of the thoracic limbs are provided for review. Two pre- contrast series of the elbow joints, soft tissue algorithm. One post- contrast series of the elbow joints, soft tissue algorithm.

COMPUTED TOMOGRAPHIC FINDINGS

LEFT THORACIC LIMB

There is a marked mixed, predominantly osteoproliferative osseous lesion affecting the distal metaphysis and diaphysis of the left humerus. The lesion is characterized by moderate cortical expansion, a Codman triangle-type periosteal reaction, and multifocal irregular trabecular periosteal proliferation, predominantly involving the medial cortex. Multifocal mottled medullary sclerosis and trabecular bone heterogeneity are present. The transition zone is poorly defined. Despite the periosteal reaction, portions of the lesion maintain relatively smooth and regular contours.

Moderate extra-articular soft tissue swelling surrounds the left elbow joint.

Additionally, there is a well-defined, hypoattenuating, rounded soft tissue lesion located slightly distal to the elbow joint along the medial aspect of the antebrachium, positioned between the biceps brachii, flexor carpi radialis, and pronator teres muscles, measuring approximately 2.6 × 2.3 × 2.1 cm.

The medial coronoid process, anconeal process, and radial head are unremarkable. The humeroulnar and humeroradial joints remain congruent.

RIGHT THORACIC LIMB

The humeroulnar and humeroradial joints are congruent. The medial coronoid process is intact.

Moderate periarticular ossification is present adjacent to the medial humeral condyle, including a large enthesophyte associated with the flexor digitorum superficialis muscle origin.

There is discrete periarticular new bone formation involving the dorsal aspect of the anconeal process.

A small mineral-attenuating extra-articular body measuring approximately 0.6 cm is identified within the medial soft tissues adjacent to the ulna, approximately 5.7 cm distal to the elbow joint, superimposed over the flexor carpi radialis muscle.



PATIENT

Merah Duclos

SPECIES

Canine

BREED

Lab

SEX

Female Spayed

AGE

8Y, 1M

WEIGHT

32kg

INTERPRETED BY

Tilde Rodrigues Froes,
DMV, MSc., Dr. Med
Vet., Dipl. CBraRVet

IMAGING PERFORMED BY

Lucy

HOSPITAL NAME

Bridgwater Veterinary
Hospital and Wellness
Centre

REFERRING VET

Dr. R Rentz

INVOICE

74915

DATE

5-6-26

COMPUTED TOMOGRAPHIC DIAGNOSIS

LEFT ELBOW:

- Marked mixed osteoproliferative lesion affecting the distal metaphysis and diaphysis of the left humerus, characterized by cortical expansion, Codman triangle-type periosteal reaction, multifocal irregular periosteal proliferation, mottled medullary sclerosis, and poorly defined transition zone. Differential diagnoses include osteomyelitis (fungal) or primary bone neoplasia.
- Moderate periarticular and extra-articular soft tissue swelling surrounding the left elbow joint.
- Well-defined hypoattenuating soft tissue lesion within the medial proximal antebrachial musculature slightly distal to the left elbow joint. Differential diagnoses include hematoma, seroma, abscess, cystic lesion, or less likely soft tissue neoplasia.

RIGHT ELBOW:

- Mild to moderate chronic degenerative and enthesiopathic changes of the right elbow joint.
- Small mineralized extra-articular body adjacent to the proximal right ulna, likely chronic dystrophic mineralization or enthesiopathic mineralization.

INTERPRETATION OF THE FINDINGS & FURTHER RECOMMENDATIONS

The tomographic findings reveal marked osseous lesion involving the distal metaphysis and diaphysis of the left humerus, characterized by cortical expansion, Codman triangle-type periosteal reaction, multifocal irregular periosteal proliferation, mottled medullary sclerosis, and a poorly defined transition zone. The primary differential diagnoses include fungal osteomyelitis and primary bone neoplasia. The relatively smooth appearance of portions of the periosteal reaction and the associated soft tissue changes may favor a chronic infectious or inflammatory component; however, imaging findings alone are insufficient for definitive differentiation.

Moderate periarticular and extra-articular soft tissue swelling is present surrounding the left elbow joint, in association with a well-defined hypoattenuating lesion within the medial proximal antebrachial musculature. Differential diagnoses for this soft tissue lesion include hematoma, seroma, abscess formation, cystic lesion, or less likely soft tissue neoplasia.

Further diagnostic investigation is strongly recommended, including image-guided biopsy and sampling for histopathology, fungal testing, and bacterial/fungal culture as clinically indicated.

Thoracic staging is also recommended if primary bone neoplasia remains a major clinical concern.

The right elbow demonstrates chronic mild-to-moderate degenerative and enthesiopathic changes, likely incidental and unrelated to the primary left-sided lesion.



PATIENT

Merah Duclos

SPECIES

Canine

BREED

Lab

SEX

Female Spayed

AGE

8Y, 1M

WEIGHT

32kg

INTERPRETED BY

Tilde Rodrigues Froes,
DMV, MSc., Dr. Med
Vet., Dipl. CBraRVet

IMAGING PERFORMED BY

Lucy

HOSPITAL NAME

Bridgwater Veterinary
Hospital and Wellness
Centre

REFERRING VET

Dr. R Rentz

INVOICE

74915

DATE

5-6-26

Fig. 1. Marked mixed osteoproliferative lesion affecting the distal metaphysis and diaphysis of the left humerus, with cortical expansion, periosteal reaction, medullary sclerosis, and poorly defined transition zone.

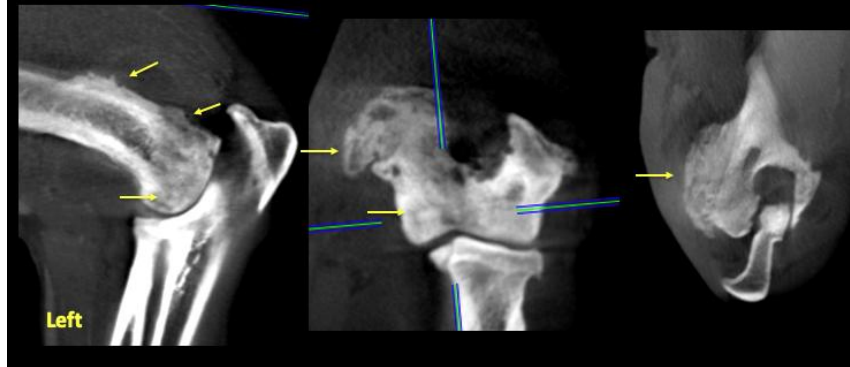
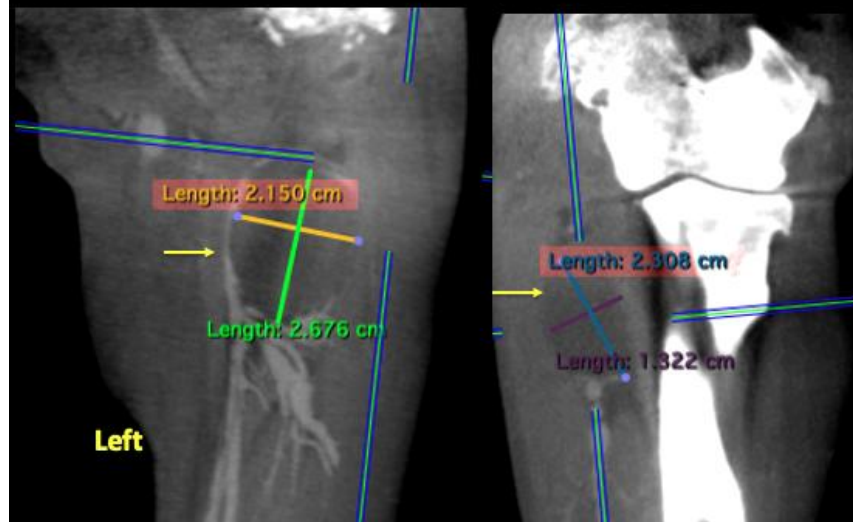

Fig. 2. Well-defined hypoattenuating soft tissue lesion within the medial proximal antebrachial musculature distal to the left elbow joint.





PATIENT

Merah Duclos

SPECIES

Canine

BREED

Lab

SEX

Female Spayed

AGE

8Y, 1M

WEIGHT

32kg

INTERPRETED BY

Tilde Rodrigues Froes,
DMV, MSc., Dr. Med
Vet., Dipl. CBraRVet

IMAGING PERFORMED BY

Lucy

HOSPITAL NAME

Bridgwater Veterinary
Hospital and Wellness
Centre

REFERRING VET

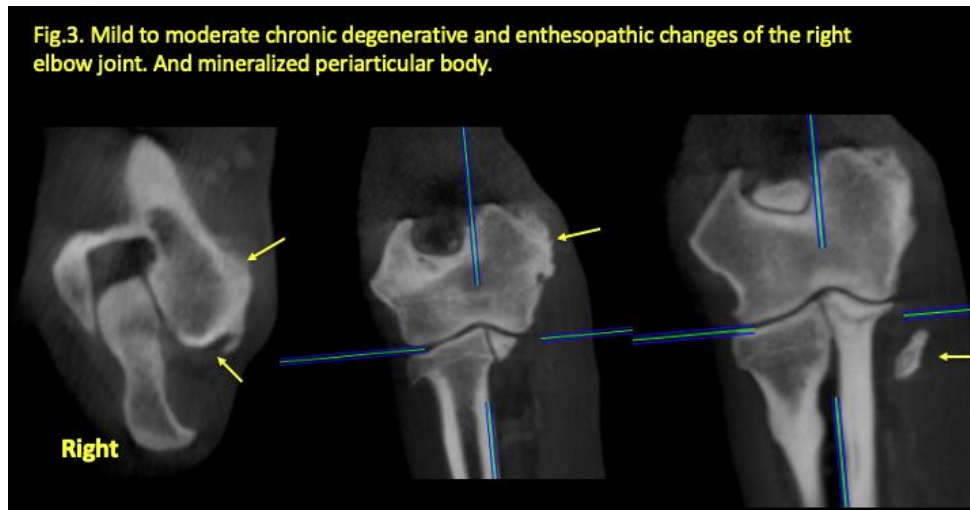
Dr. R Rentz

INVOICE

74915

DATE

5-6-26



The information and recommendations provided are based on the images presented by the referring veterinarian. No evaluation can be communicated regarding pathology that was not visible in the image/video clips provided.

Thank you for this referral. If the clinical or image interpretation does not parallel your findings or if I can be of any further assistance, please contact me.

Tilde Rodrigues Froes, DMV, MSc., Dr. Med.Vet., Dipl.CBraRVet
info@sonopath.com