



## PATIENT

Argy Sumberg

## SPECIES

Feline

## BREED

DMH

## SEX

MN

## AGE

6M

## WEIGHT

7

## INTERPRETED BY

Tilde Rodrigues Froes,  
DMV, MSc., Dr. Med  
Vet., Dipl. CBraRVet

## IMAGING PERFORMED BY

Lyndsey/Ashley L

## HOSPITAL NAME

Tempe Lake Veterinary  
Hospital

## REFERRING VET

Dr. Pini

## INVOICE

74875

## DATE

5-4-26

## PRESENTING CLINICAL SIGNS

6 month MN domestic shorthair w/ bony mandibular mass. P has had since 2 months old and it was grown in size since, per O. Non-bothersome. P is otherwise normal. BW unremarkable, in-house valley fever test negative, bone biopsy pending (easily friable on biopsy w/ 18G needle).

## COMPUTED TOMOGRAPHIC STUDY OF THE HEAD

A single non-contrast CT study of the head was provided for review, acquired in the transverse plane using a bone algorithm.

## COMPUTED TOMOGRAPHIC FINDINGS

There is a severe mixed, predominantly osteoproliferative osseous lesion affecting nearly the entirety of the left mandible. The lesion predominantly involves the mandibular body, where marked cortical expansion and mass effect are observed, including a Codman triangle-type periosteal reaction and multifocal rostral spiculated periosteal proliferation. Despite the aggressive periosteal reaction, portions of the lesion maintain relatively smooth and regular contours.

Multifocal internal regions of osteolysis/osteonecrosis are present within the proliferative osseous lesion. The transition zone is poorly defined. The lesion extends to the mandibular ramus and coronoid process; at these sites, the periosteal proliferation assumes a more regular pattern.

The lesion also extends into the medullary cavity and alveolar bone; however, the dental roots of Triadan 304, 307, 308, and 309 remain preserved without evident lysis.

The left mandibular lymph nodes are enlarged.

The remaining dentition and alveolar bone are within normal limits.

The remaining cranial and facial osseous structures are unremarkable.

The nasal cavities and turbinates are within normal limits.

The cribriform plate is intact.

The oropharynx and nasopharynx are within normal limits.

The frontal sinuses are unremarkable.

The tympanic cavities and external auditory canals are within normal limits.

The globes and retrobulbar spaces are within normal limits.

The temporomandibular joints are bilaterally congruent.

## COMPUTED TOMOGRAPHIC DIAGNOSIS

- Severe mixed, predominantly osteoproliferative and locally aggressive lesion affecting the left mandible, associated with marked cortical expansion, periosteal reaction, multifocal internal osteolysis/osteonecrosis, and a poorly defined transition zone. Despite the aggressive



**PATIENT**

Argy Sumberg

periosteal reaction, portions of the lesion maintain relatively smooth and regular contours. Primary differential diagnosis includes chronic osteomyelitis.

- Enlargement of the left mandibular lymph nodes, likely representing reactive lymphadenopathy.

**SPECIES**

Feline

**BREED**

DMH

**SEX**

MN

**AGE**

6M

**WEIGHT**

7

**INTERPRETATION OF THE FINDINGS & FURTHER RECOMMENDATIONS**

The tomographic findings reveal a severe mixed osseous lesion affecting the left mandible, characterized predominantly by osteoproliferative changes, marked cortical expansion, periosteal reaction, and a poorly defined transition zone. Despite the aggressive appearance, portions of the lesion maintain relatively smooth and regular contours.

The primary differential diagnosis is chronic osteomyelitis, particularly considering the patient's age and the chronicity of the lesion. A primary osseous neoplasm is considered less likely; however, it cannot be entirely excluded based on imaging findings alone.

The enlarged left mandibular lymph nodes are most consistent with reactive lymphadenopathy, or less likely metastatic involvement cannot be completely excluded.

Correlation with pending histopathology is recommended for definitive diagnosis. Additional bacterial and fungal culture may also be considered if clinically indicated.

**TECHNICAL COMMENTS**

The absence of post-contrast series reduces sensitivity for soft tissue structural assessment.

**INTERPRETED BY**

Tilde Rodrigues Froes,  
DMV, MSc., Dr. Med  
Vet., Dipl. CBraRVet

**IMAGING PERFORMED BY**

Lyndsey/Ashley L

**HOSPITAL NAME**

Tempe Lake Veterinary  
Hospital

**REFERRING VET**

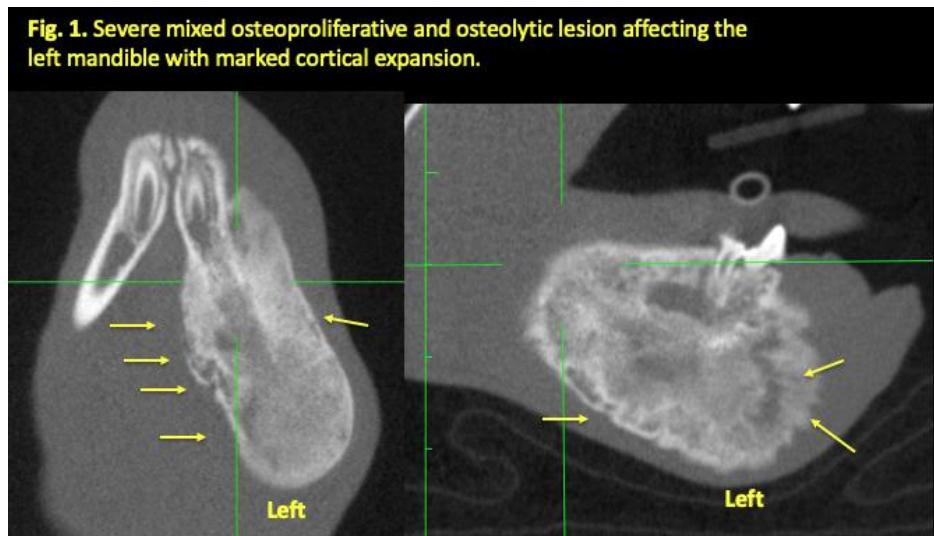
Dr. Pini

**INVOICE**

74875

**DATE**

5-4-26





## PATIENT

Argy Sumberg

## SPECIES

Feline

## BREED

DMH

## SEX

MN

## AGE

6M

## WEIGHT

7

## INTERPRETED BY

Tilde Rodrigues Froes,  
DMV, MSc., Dr. Med  
Vet., Dipl. CBraRVet

## IMAGING PERFORMED BY

Lyndsey/Ashley L

## HOSPITAL NAME

Tempe Lake Veterinary  
Hospital

## REFERRING VET

Dr. Pini

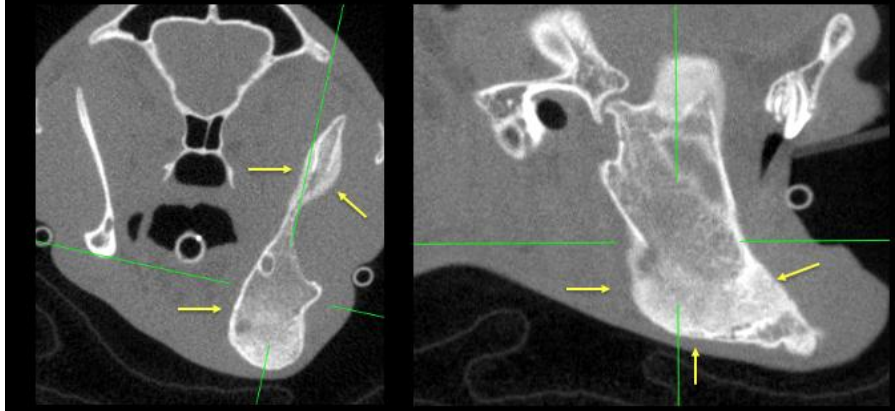
## INVOICE

74875

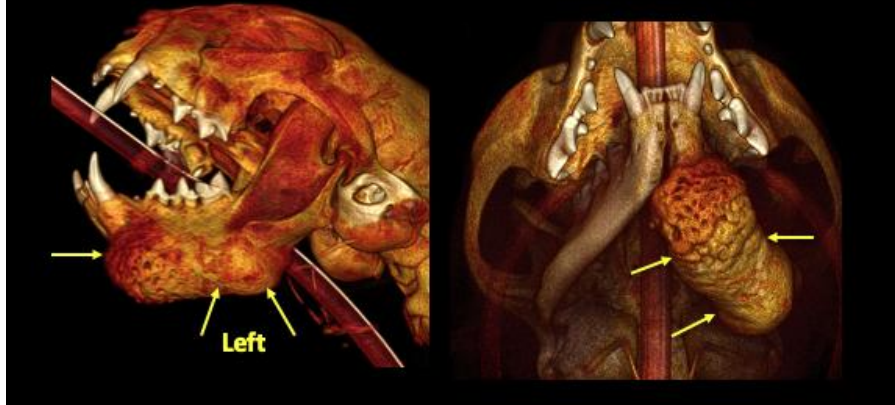
## DATE

5-4-26

**Fig. 2. Lesion margins**  
Despite the aggressive appearance, portions of the lesion maintain relatively smooth and regular contours.



**Fig. 3. 3D reconstruction demonstrating a mixed osteoproliferative and osteolytic lesion of the left mandible with marked cortical expansion.**



The information and recommendations provided are based on the images presented by the referring veterinarian. No evaluation can be communicated regarding pathology that was not visible in the image/video clips provided.

Thank you for this referral. If the clinical or image interpretation does not parallel your findings or if I can be of any further assistance, please contact me.

**Tilde Rodrigues Froes, DMV, MSc., Dr. Med.Vet., Dipl.CBraRVet**  
[info@sonopath.com](mailto:info@sonopath.com)