



PATIENT PRESENTING CLINICAL SIGNS

Shayna Maline Limping left pelvic limb. On Galliprant 20 mg SID

SPECIES RADIOGRAPHIC STUDY OF THE PELVIC LIMBS

Canine Radiographs of the pelvic limbs in two imaging planes are provided for review. One ventral dorsal view, one lateral view focus on left stifle joint, and one lateral view focus on right stifle joint.

RADIOGRAPHIC FINDINGS

BREED Left Pelvic Limb

Scottish Terrier There is articular swelling of the left stifle joint and increased volume extending caudally, medially, and cranially from normal margins, and is compressing the caudal 40% of the infrapatellar fat pad. The proximal tibia is cranially translocated in relation to the distal femur.

SEX
FS Moderate periarticular ossification is seen at the margins of the left patella, femoral trochlear ridges, border of tibial condyles and sesamoids of the gastrocnemius.

AGE There is mild subchondral sclerosis and periarticular osteophytes in the tarsocrural joint.

16 The superficial digital flexor tendon is subjectively thickened, and an enthesophyte ossification is seen in the plantar surface of the calcaneus.

INTERPRETED BY The popliteal lymph node is mildly enlarged in comparison with the contralateral and measures approximately 1.7cm x 0.5cm.

Tilde Rodrigues Froes,
DMV, MSc., Dr. Med
Vet., Dipl. CBraRVet

Right Pelvic Limb

The stifle joint and fat-pad opacity are normal.

The patella is unremarkable.

HOSPITAL NAME There is mild subchondral sclerosis and periarticular osteophytes in the tarsocrural joint.

Byram Animal Hospital There is adequate coverage of the femoral heads by the dorsal acetabular margins of approximately 50%. The coxofemoral joints are congruent, normal pelvis.

REFERRING VET RADIOGRAPHIC DIAGNOSIS

- Left stifle joint synovial swelling, moderate secondary osteoarthritis, and subluxation are indicative with a partial tear or complete rupture of the cranial cruciate ligament. Differential diagnosis includes concurrent inflammatory joint effusion, synovial hyperplasia.
- Thickening of the superficial digital flexor tendon indicates tendinopathy ("Achilles tendinopathy) or swelling.
- Left popliteal lymphadenopathy, reactive.
- Bilateral mild tarsocrural degenerative osteoarthritis.

INVOICE
58112

DATE
5-3-23



PATIENT INTERPRETATION OF THE FINDINGS & FURTHER RECOMMENDATIONS

Shayna Maline

The radiographic findings of the left stifle joint correlate with the patient's history. Correlate the radiographic findings with specific orthopedic exams, for example, the tibial thrust and cranial drawer. A musculoskeletal ultrasound could be considered for next approach for the evaluation of the left superficial digital flexor tendon.

SPECIES

Canine

If attainable, consider a fine-needle aspiration of the left popliteal lymph node.

BREED

Scottish Terrier

SEX

FS

AGE

16

INTERPRETED BY

Tilde Rodrigues Froes,
DMV, MSc., Dr. Med
Vet., Dipl. CBraRVet

HOSPITAL NAME

Byram Animal
Hospital

REFERRING VET

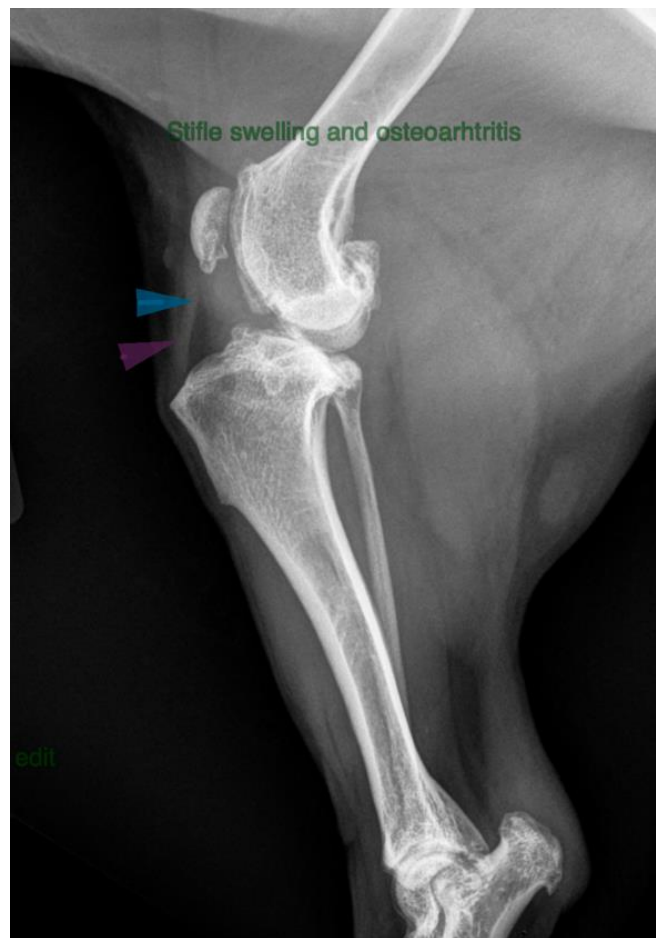Dr. Carlos Abdul-
Chani

INVOICE

58112

DATE

5-3-23





PATIENT

Shayna Maline

SPECIES

Canine

BREED

Scottish Terrier

SEX

FS

AGE

16

INTERPRETED BY

Tilde Rodrigues Froes,
DMV, MSc., Dr. Med
Vet., Dipl. CBraRVet

HOSPITAL NAME

Byram Animal
Hospital

REFERRING VET

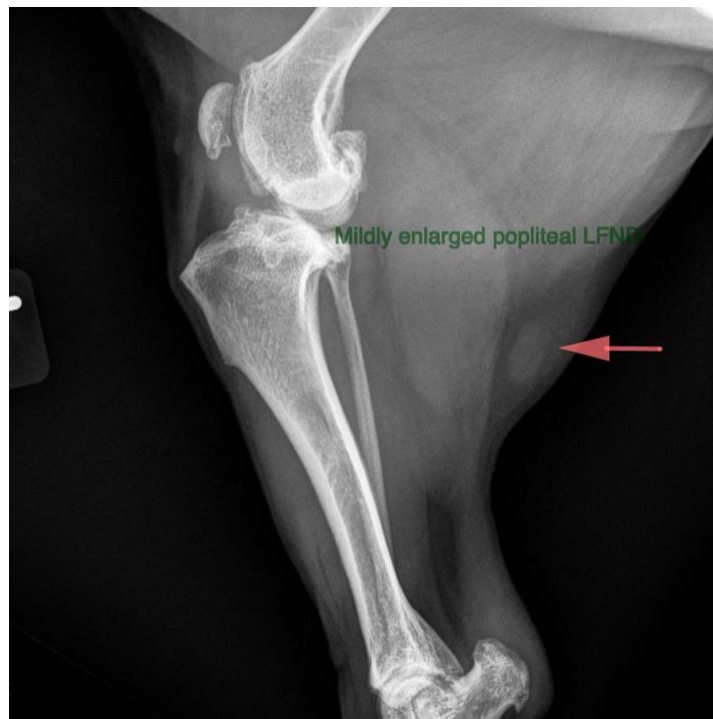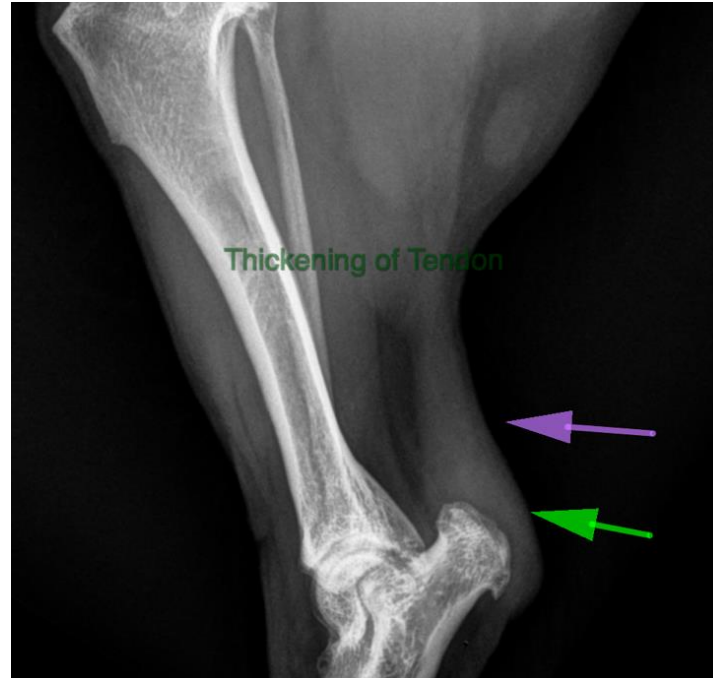
Dr. Carlos Abdul-
Chani

INVOICE

58112

DATE

5-3-23





PATIENT

Shayna Maline

SPECIES

Canine

BREED

Scottish Terrier

SEX

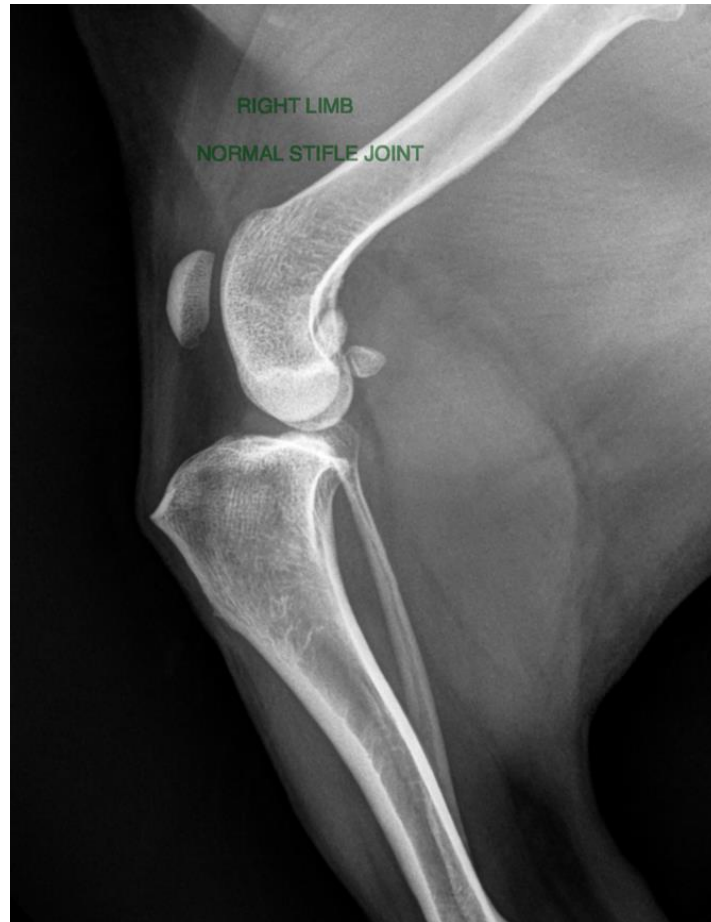FS

AGE

16

INTERPRETED BY

Tilde Rodrigues Froes,
DMV, MSc., Dr. Med
Vet., Dipl. CBraRVet



HOSPITAL NAME

Byram Animal
Hospital

The information and recommendations provided are based on the images presented by the referring veterinarian. No evaluation can be communicated regarding pathology that was not visible in the image/video clips provided.

REFERRING VET

Dr. Carlos Abdul-
Chani

Thank you for this referral. If the clinical or image interpretation does not parallel your findings or if I can be of any further assistance please contact me.

Tilde Rodrigues Froes, DMV, MSc., Dr. Med.Vet., Dipl.CBraRVet
info@sonopath.com

INVOICE

58112

DATE

5-3-23