

PATIENT

Luna Delgado

SPECIES

Feline

BREED

Domestic Short Hair

SEX

Female Spayed

AGE

12Y

WEIGHT

11.2lbs

INTERPRETED BY

Tilde Rodrigues Froes,
DMV, MSc., Dr. Med
Vet., Dipl. CBraRVet

IMAGING PERFORMED BY

Dr. Abina Glennon

HOSPITAL NAME

New Bridge Veterinary
Practice

REFERRING VET

Dr. Abina Glennon

INVOICE

75187

DATE

5-28-26

PRESENTING CLINICAL SIGNS

limping left thoracic limb

RADIOGRAPHIC STUDY OF THE THORACIC LIMBS – CARPI, METACARPI, AND DIGITS

Orthogonal radiographic views of both thoracic limbs were obtained, including craniocaudal and lateral projections (4 images total).

RADIOGRAPHIC FINDINGS

The antebrachial, carpal, metacarpal, and digital joints are preserved bilaterally, with normal alignment and no evidence of acute osseous abnormality.

The radius, ulna, carpal bones, metacarpal bones, phalanges, and ungual processes are unremarkable bilaterally.

The claws and adjacent soft tissues are within normal radiographic limits.

The elbow regions are collimated on the submitted images. Mild bilateral periarticular osteophytosis is present within the visualized aspects of both elbow joints. Small adjacent mineralized osteochondral bodies are noted associated with both elbows.

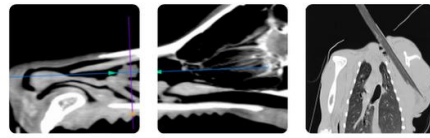
RADIOGRAPHIC DIAGNOSIS

- No radiographic abnormalities identified involving the antebrachial, carpal, metacarpal, or digital regions of either thoracic limb.
- Mild bilateral elbow osteoarthritis.

INTERPRETATION OF THE FINDINGS & FURTHER RECOMMENDATIONS

The distal portions of both thoracic limbs are radiographically normal.

Mild bilateral degenerative changes are present at the visualized elbow joints. These findings may or may not be associated with clinical signs of lameness, and concurrent flexor enthesopathy cannot be excluded. However, mild degenerative changes are a common incidental finding in this region in cats and do not always correlate with clinical lameness.



PATIENT

Luna Delgado

SPECIES

Feline

BREED

Domestic Short Hair

SEX

Female Spayed

AGE

12Y

WEIGHT

11.2lbs

INTERPRETED BY

Tilde Rodrigues Froes,
DMV, MSc., Dr. Med
Vet., Dipl. CBraRVet

**IMAGING
PERFORMED BY**

Dr. Abina Glennon

HOSPITAL NAME

New Bridge Veterinary
Practice

REFERRING VET

Dr. Abina Glennon

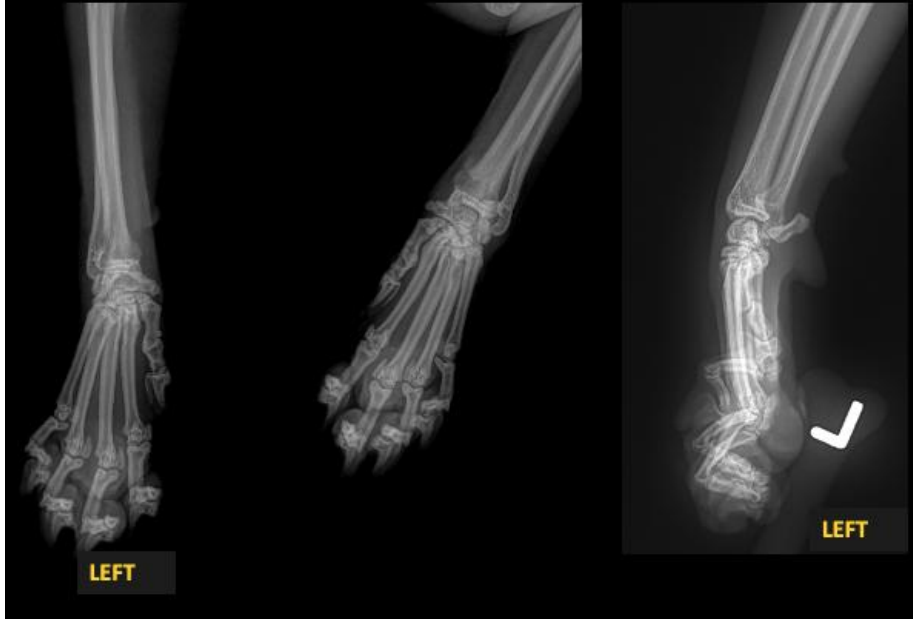INVOICE

75187

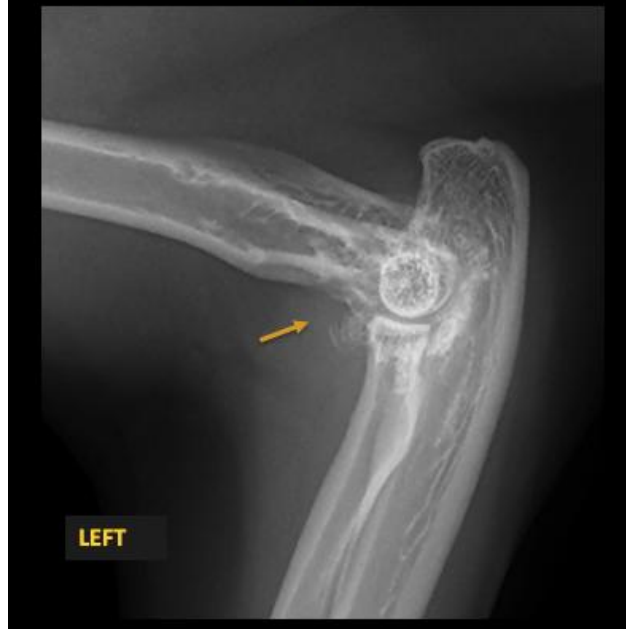DATE

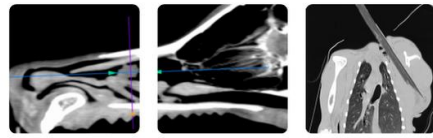
5-28-26

**Fig. 1. Normal distal thoracic limb structures
Antebrachial, carpal, metacarpal, and digital bones are unremarkable.**



**Fig. 2. Mild periarticular osteophytosis is present
within the left elbow joint.**





PATIENT

Luna Delgado

SPECIES

Feline

BREED

Domestic Short Hair

SEX

Female Spayed

AGE

12Y

WEIGHT

11.2lbs

INTERPRETED BY

Tilde Rodrigues Froes,
DMV, MSc., Dr. Med
Vet., Dipl. CBraRVet

IMAGING PERFORMED BY

Dr. Abina Glennon

HOSPITAL NAME

New Bridge Veterinary
Practice

REFERRING VET

Dr. Abina Glennon

INVOICE

75187

DATE

5-28-26

The information and recommendations provided are based on the images presented by the referring veterinarian. No evaluation can be communicated regarding pathology that was not visible in the image/video clips provided.

Thank you for this referral. If the clinical or image interpretation does not parallel your findings or if I can be of any further assistance, please contact me.

Tilde Rodrigues Froes, DMV, MSc., Dr. Med.Vet., Dipl.CBraRVet
info@sonopath.com