



## PATIENT

Pebbles Coe

## SPECIES

Feline

## BREED

DSH

## SEX

FS

## AGE

6Y

## WEIGHT

10lbs

## INTERPRETED BY

Tilde Rodrigues Froes,  
DMV, MSc., Dr. Med  
Vet., Dipl. CBraRVet

## IMAGING PERFORMED BY

Vet Techs

## HOSPITAL NAME

Northshore Veterinary  
Hospital

## REFERRING VET

Caley Landin

## INVOICE

75135

## DATE

5-26-26

## PRESENTING CLINICAL SIGNS

New patient - 6 day history inappetence/lethargy. Multiple instances of vomiting. Is still drinking water. Indoor/outdoor, is up to date on her vaccinations  
Abnormal PE/Chem/CBC/UA Results: 4/9 BCS. 5% dehydrated. Cre 2.8, BUN 43, isosthenuria. No pain on abdominal palpation. Afebrile. Urinalysis otherwise boring. Felv/fiv negative. No known toxin exposure but she does have unsupervised access outdoors

## RADIOGRAPHIC STUDY OF THE THORAX & ABDOMEN

Orthogonal views of the whole body are available for review totaling three images. One ventrodorsal view. One right lateral view. One left lateral view.

## RADIOGRAPHIC FINDINGS

### THORAX

The cardiac silhouette is within normal limits in size and shape (VHS = 7.0).

Pulmonary parenchyma is within normal radiographic limits, without evidence of focal pulmonary opacity or pulmonary mass.

Pulmonary vessels are within normal limits in size and distribution.

The trachea is normal in position and diameter.

The pleural space, mediastinum, diaphragm, thoracic wall, and visible osseous structures are unremarkable.

The esophagus is unremarkable.

### ABDOMEN

The liver, spleen, and kidneys are within normal radiographic limits for size, shape, and opacity.

The stomach contains a small amount of gas and ingesta and is in normal position.

The urinary bladder mildly distended with homogeneous soft tissue opaque fluid opacity.

The small are normally distributed and are not abnormally distended or evidence of mass effect.

The colon is almost empty, with discrete amount of heterogeneous opaque fecal material and predominantly air-filled.

Abdominal serosal detail is preserved.

The visible osseous structures are unremarkable.



## PATIENT

Pebbles Coe

## SPECIES

Feline

## BREED

DSH

## SEX

FS

## AGE

6Y

## WEIGHT

10lbs

## INTERPRETED BY

Tilde Rodrigues Froes,  
DMV, MSc., Dr. Med  
Vet., Dipl. CBraRVet

## IMAGING PERFORMED BY

Vet Techs

## HOSPITAL NAME

Northshore Veterinary  
Hospital

## REFERRING VET

Caley Landin

## INVOICE

75135

## DATE

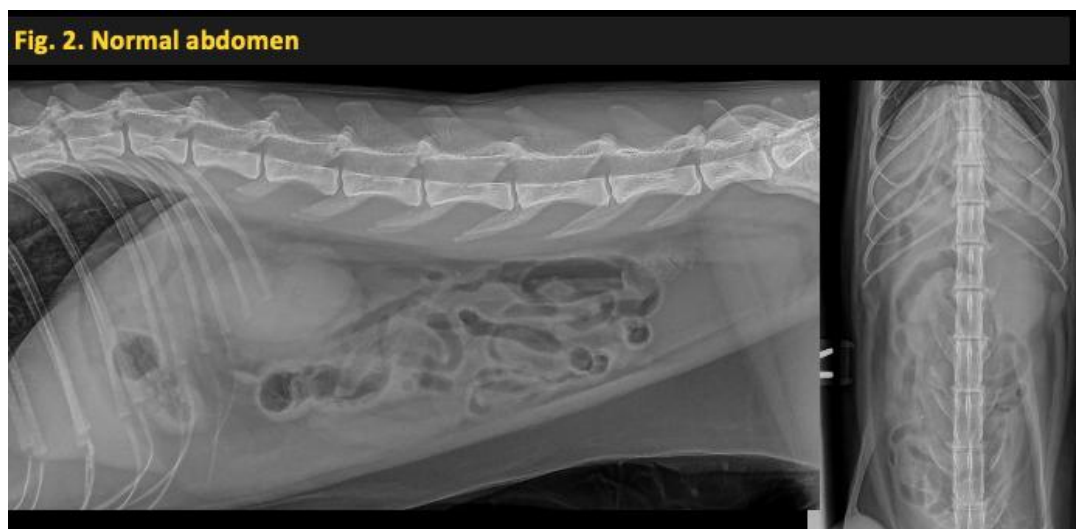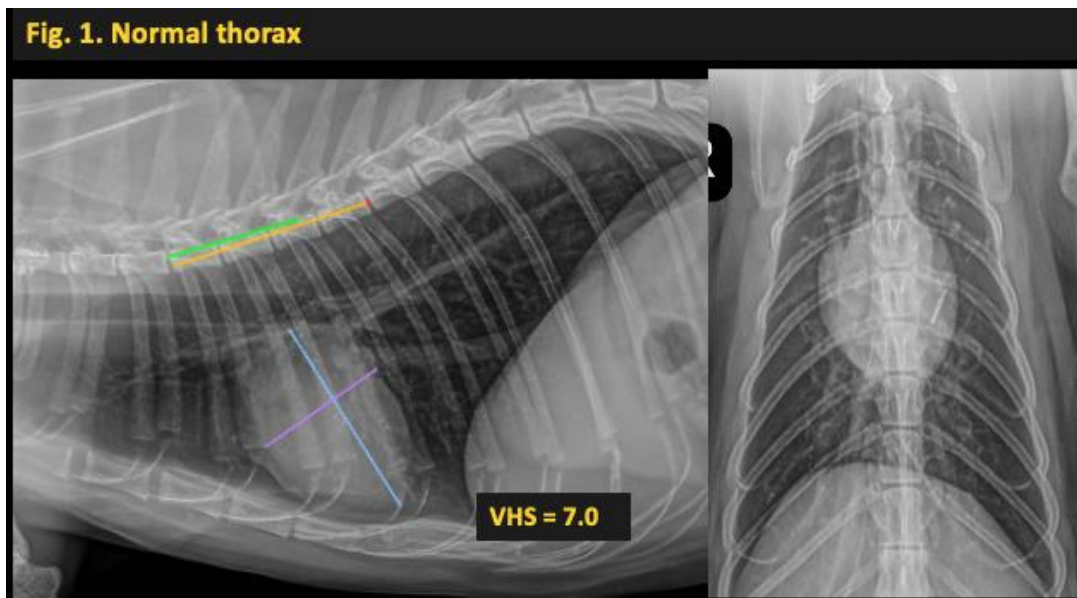
5-26-26

## RADIOGRAPHIC DIAGNOSIS

- No radiographic abnormalities identified in the thorax or abdomen.

## INTERPRETATION OF THE FINDINGS & FURTHER RECOMMENDATIONS

Thoracic and abdominal radiographs show no significant abnormalities to account for the reported clinical signs.





## PATIENT

Pebbles Coe

## SPECIES

Feline

## BREED

DSH

## SEX

FS

## AGE

6Y

## WEIGHT

10lbs

## INTERPRETED BY

Tilde Rodrigues Froes,  
DMV, MSc., Dr. Med  
Vet., Dipl. CBraRVet

## IMAGING PERFORMED BY

Vet Techs

## HOSPITAL NAME

Northshore Veterinary  
Hospital

## REFERRING VET

Caley Landin

## INVOICE

75135

## DATE

5-26-26

The information and recommendations provided are based on the images presented by the referring veterinarian. No evaluation can be communicated regarding pathology that was not visible in the image/video clips provided.

Thank you for this referral. If the clinical or image interpretation does not parallel your findings or if I can be of any further assistance, please contact me.

**Tilde Rodrigues Froes, DMV, MSc., Dr. Med.Vet., Dipl.CBraRVet**  
[info@sonopath.com](mailto:info@sonopath.com)