



PATIENT

Effie Schimkus

SPECIES

Feline

BREED

British Shorthair

SEX

FS

AGE

11

WEIGHT

7.56lbs

INTERPRETED BY

Tilde Rodrigues Froes,
DMV, MSc., Dr. Med
Vet., Dipl. CBraRVet

IMAGING PERFORMED BY

Peregrine

HOSPITAL NAME

Animal Medical Center
of Corona

REFERRING VET

Sean Yamada

INVOICE

75086

DATE

5-20-26

PRESENTING CLINICAL SIGNS

Effie - 11y FS British shorthair presenting to AMCC for metastasis check. Multiple ultrasound scans performed at AVH, and an internal medicine specialist determined that the progression of inflamed bowels, ultrasonographical evidence of pancreatitis, liver mass, and progression of dilation of gallbladder and bile duct to be concerning and the CT scan was recommended. P originally presented at AVH for vomiting and hyporexia.

Abnormal PE/Chem/CBC/UA Results: P has normal cobalamin/folate, normal fPL/TLI/precision PSL, elevated liver enzymes, and hyperbilirubinemia. P is clinically stable today and history suggests that P is eating well and having normal activity at this time. AST 141 (10 - 100 IU/L), ALT 537 (10 - 100 IU/L), CHOLESTEROL 276 (75 - 220 mg/dL), Absolute Neutrophils 8811 (2500 - 8500 /uL), Absolute Lymphocytes 792 (1200 - 8000 /uL).

COMPUTED TOMOGRAPHIC STUDY OF THE THORAX AND ABDOMEN

A pre- and post-contrast CT study of the thorax and abdomen is provided for review totaling 2 series. One pre-contrast series of the thorax (bone algorithm). One post-contrast series of the abdomen (soft tissue algorithm).

COMPUTED TOMOGRAPHIC FINDINGS

ABDOMEN

The liver contains at least five small hypoattenuating nodules and one larger hypoattenuating mildly heterogeneous nodule, predominantly located at the periphery of the hepatic lobes. The smaller nodules measure approximately 0.3 × 0.7 cm, 0.7 × 0.7 cm, and 0.4 × 0.2 cm. The largest nodule, measuring approximately 1.3 × 1.5 cm, is located along the ventral peripheral aspect of the left medial liver lobe. Mild diffuse heterogeneous post-contrast hepatic enhancement is present. Hepatic margins are predominantly regular, except adjacent to the larger left medial lobe nodule.

The gallbladder is moderately distended with homogeneous hypoattenuating content. Mild cystic duct dilation is present 4.0 mm. Multifocal intrahepatic biliary ductal dilation is observed, reaching up to approximately 4.0–6.0 mm in diameter in some segments. The common bile duct is mildly distended, and near its insertion, measuring approximately 3.2 mm in diameter. No mineral attenuating intraluminal material or obstructive cholelithiasis is identified.

No pancreatic or duodenal mass effect is identified. The pancreas maintains normal contour, size, and attenuation of both lobes without significant surrounding mesenteric fat stranding.

The stomach is mildly distended by homogeneous fluid content without mural abnormality.

There is diffuse mild circumferential mural thickening of the duodenum, jejunum, and ileum, measuring approximately 0.4–0.5 cm in thickness. The muscularis layer appears subjectively more prominent than the mucosal layer in multifocal segments of the small intestine. Mild mural thickening is also present within the ileum without evidence of focal mass effect.

The transverse and descending colon are predominantly unremarkable; however, multifocal mild mural thickening is noted in portions of the distal descending colon and rectum.

No enlargement of the jejunal, colic, or hepatic portal lymph nodes is identified. The abdominal lymph nodes are unremarkable.



PATIENT

Effie Schimkus

SPECIES

Feline

BREED

British Shorthair

SEX

FS

AGE

11

WEIGHT

7.56lbs

INTERPRETED BY

Tilde Rodrigues Froes,
DMV, MSc., Dr. Med
Vet., Dipl. CBraRVet

IMAGING PERFORMED BY

Peregrine

HOSPITAL NAME

Animal Medical Center
of Corona

REFERRING VET

Sean Yamada

INVOICE

75086

DATE

5-20-26

The spleen is mildly enlarged with mildly convex margins and a subtle mottled attenuation pattern, likely incidental or congestion related.

The right kidney demonstrates mild focal cortical retraction involving the cranial pole, associated with tiny multifocal wedge-shaped hyperattenuating cortical foci. A 2.6 mm mineral attenuating focus is present within the right renal pelvis region, without associated pyelectasia. The remaining renal parenchyma is preserved bilaterally. The left kidney is within normal limits regarding size, contour, and attenuation. The ureters are unremarkable.

The urinary bladder is moderately distended by homogeneous hypoattenuating fluid content with normal mural thickness.

The adrenal glands are within normal limits.

The mesentery demonstrates normal attenuation without free abdominal fluid or steatitis.

THORAX

The trachea and mainstem bronchi are within normal limits.

Discrete peripheral pulmonary consolidative opacities are present, most consistent with mild dependent/passive atelectatic change. The remaining pulmonary parenchyma demonstrates normal attenuation and aeration, without evidence of pulmonary nodules or masses.

The bronchial tree exhibits normal branching and tapering. Bronchial walls are thin and smooth, with a normal bronchus-to-artery ratio.

The sternal, cranial mediastinal, and tracheobronchial lymph nodes are unremarkable.

The cardiac silhouette and major thoracic vessels are unremarkable.

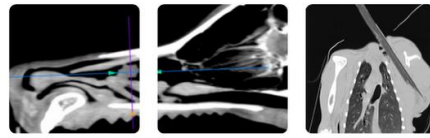
The pleural space and diaphragm are unremarkable.

The thoracic esophagus is unremarkable.

The thoracic wall and osseous structures included in the study are unremarkable for clinically significant abnormalities.

COMPUTED TOMOGRAPHIC DIAGNOSIS

- Multifocal hypoattenuating hepatic nodules, including one larger left medial liver lobe nodule. Differential diagnoses include inflammatory nodules, cholangiohepatitis-associated changes (abscess/microabscess), nodular hyperplasia, regenerative nodules, or neoplastic disease.
- Moderate gallbladder distension with mild extrahepatic and multifocal intrahepatic biliary ductal dilation, without CT evidence of obstructive cholelithiasis or pancreatic/duodenal compressive mass effect. Differential diagnoses include cholestatic hepatobiliary disease and/or inflammatory, cholangitis/cholangiohepatitis, less likely partial obstruction due to dense intraluminal content.
- Diffuse mild small intestinal mural thickening with subjective muscularis layer prominence, most consistent with chronic enteropathy/inflammatory bowel disease. Low-grade infiltrative disease such as small-cell lymphoma cannot be excluded based on imaging alone.



PATIENT

Effie Schimkus

SPECIES

Feline

BREED

British Shorthair

SEX

FS

AGE

11

WEIGHT

7.56lbs

INTERPRETED BY

Tilde Rodrigues Froes,
DMV, MSc., Dr. Med
Vet., Dipl. CBraRVet

**IMAGING
PERFORMED BY**

Peregrine

HOSPITAL NAME

Animal Medical Center
of Corona

REFERRING VET

Sean Yamada

INVOICE

75086

DATE

5-20-26

- Mild multifocal mural thickening involving portions of the distal colon and rectum, likely inflammatory.
- Mild splenomegaly with subtle mottled attenuation pattern, likely incidental/congestion-related, other potential differential diagnosis extramedullary hematopoiesis, lymphoid hyperplasia, infiltrative disease.
- Mild right renal cortical scarring/remodeling with a small non-obstructive right nephrolith.
- Mild dependent pulmonary atelectatic changes without evidence of metastatic pulmonary disease or clinically significant thoracic abnormality.
- Otherwise, normal thorax.

INTERPRETATION OF THE FINDINGS & FURTHER RECOMMENDATIONS

The tomographic findings support a chronic hepatobiliary and intestinal inflammatory process. The combination of multifocal biliary dilation, gallbladder distension, diffuse intestinal mural thickening with muscularis layer prominence, and the clinical history of inflammatory bowel disease, even without pancreatitis aspect, raises concern for feline triaditis/cholangiohepatitis complex.

Importantly, no obstructive mineralized biliary calculus, pancreatic mass, or duodenal mass effect is identified to explain the biliary dilation; however, partial obstruction related to dense bile material cannot be completely excluded.

The hepatic nodules may represent regenerative or inflammatory nodules; however, neoplastic infiltration cannot be excluded based on imaging findings alone, particularly considering the larger left medial lobe lesion. This larger lesion is peripheral and ventrally positioned for ultrasound-guided fine-needle aspiration.

The diffuse intestinal changes are most compatible with chronic inflammatory enteropathy, although low-grade alimentary lymphoma remains a differential diagnosis.

Correlation with cytology or histopathology of the hepatic nodules and/or liver parenchyma is recommended if clinically indicated. Correlation with bile sampling, culture, pancreatic testing, gastrointestinal biopsy, and serial hepatobiliary ultrasonographic follow-up may also be beneficial depending on clinical progression.

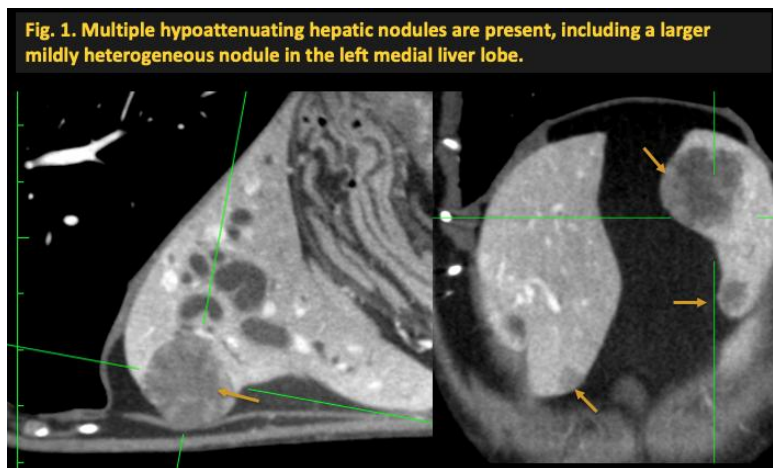
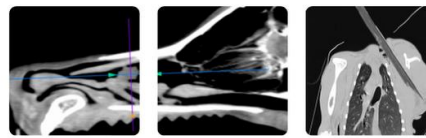


Fig. 1. Multiple hypoattenuating hepatic nodules are present, including a larger mildly heterogeneous nodule in the left medial liver lobe.



PATIENT

Effie Schimkus

SPECIES

Feline

BREED

British Shorthair

SEX

FS

AGE

11

WEIGHT

7.56lbs

INTERPRETED BY

Tilde Rodrigues Froes,
DMV, MSc., Dr. Med
Vet., Dipl. CBraRVet

IMAGING PERFORMED BY

Peregrine

HOSPITAL NAME

Animal Medical Center
of Corona

REFERRING VET

Sean Yamada

INVOICE

75086

DATE

5-20-26

Fig. 2. Multiple hypoattenuating hepatic nodules are present, and moderate gallbladder distension with multifocal intrahepatic

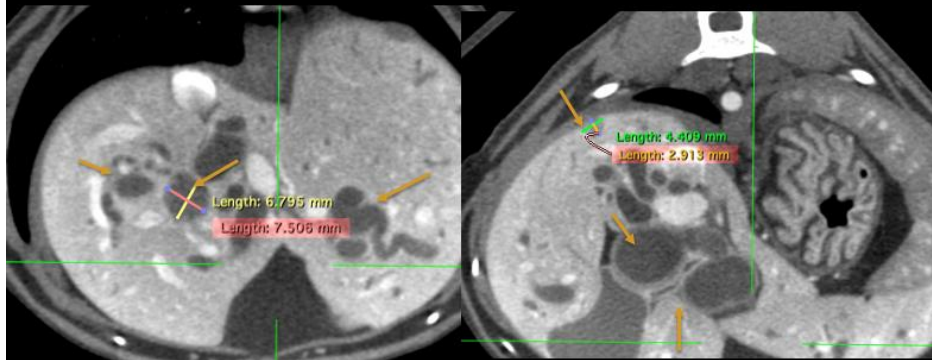


Fig. 3. Moderate gallbladder distension with multifocal intrahepatic biliary ductal dilation, and small peripheral hypoattenuating nodule

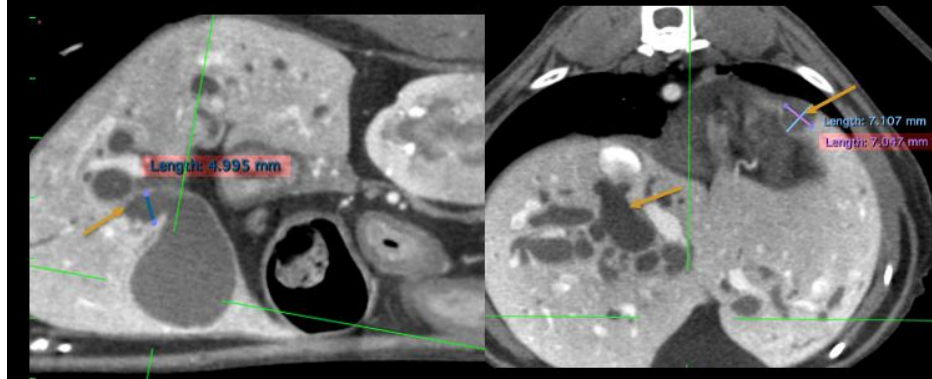
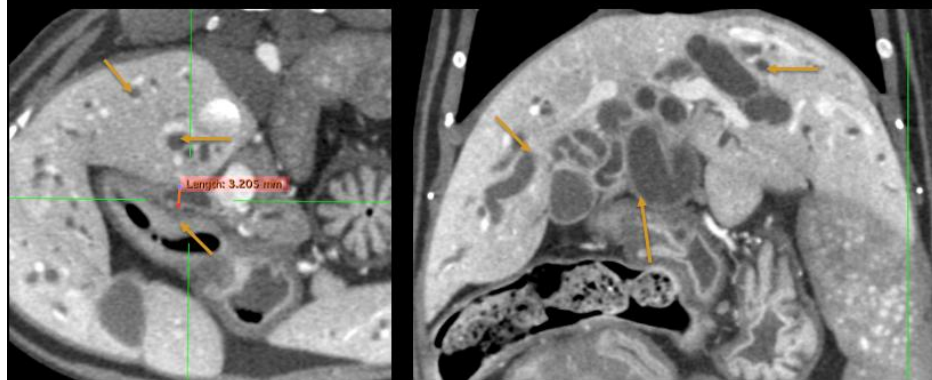
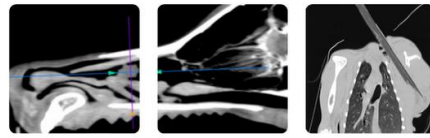


Fig. 4. Multifocal intrahepatic and mild extrahepatic biliary ductal dilation without evidence of obstructive cholelithiasis.





PATIENT

Effie Schimkus

SPECIES

Feline

BREED

British Shorthair

SEX

FS

AGE

11

WEIGHT

7.56lbs

INTERPRETED BY

Tilde Rodrigues Froes, DMV, MSc., Dr. Med Vet., Dipl. CBraRVet

IMAGING PERFORMED BY

Peregrine

HOSPITAL NAME

Animal Medical Center of Corona

REFERRING VET

Sean Yamada

INVOICE

75086

DATE

5-20-26

Fig. 5. Diffuse mild mural thickening of the small intestine with multifocal muscularis layer prominence.

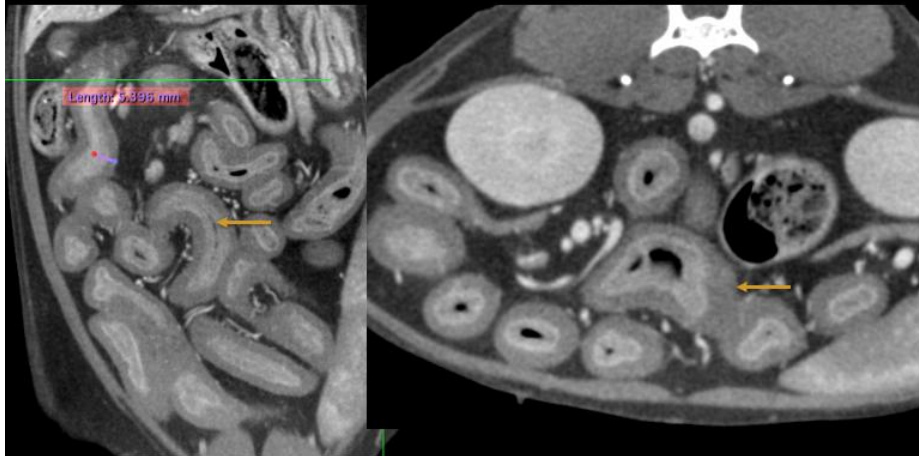
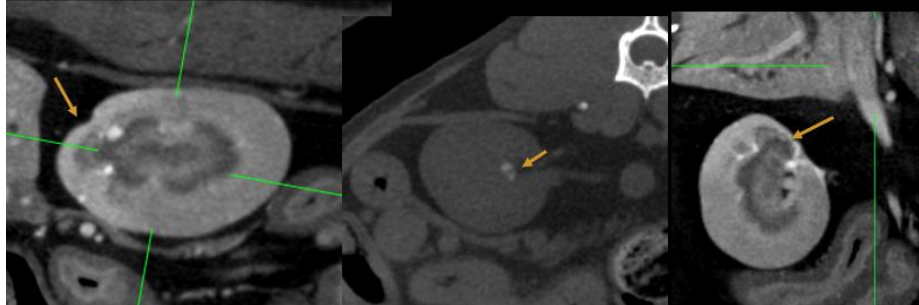


Fig. 6. Mild focal cortical retraction, and a small non-obstructive nephrolith in the renal pelvis region.



The information and recommendations provided are based on the images presented by the referring veterinarian. No evaluation can be communicated regarding pathology that was not visible in the image/video clips provided.

Thank you for this referral. If the clinical or image interpretation does not parallel your findings or if I can be of any further assistance, please contact me.

Tilde Rodrigues Froes, DMV, MSc., Dr. Med.Vet., Dipl.CBraRVet
info@sonopath.com