



**PATIENT PRESENTING CLINICAL SIGNS**

Tucker Gosinco Diagnosed bladder tumor on neck of bladder on AUS

**SPECIES COMPUTED TOMOGRAPHIC STUDY OF ABDOMEN**

K9 A high-resolution pre- and post-contrast CT study of the abdomen is provided for review. One pre-contrast series and one post-contrast CT series are evaluated.

**BREED COMPUTED TOMOGRAPHIC FINDINGS**

Lab Mix A multifocal, raised, broad-base bladder wall mass is seen, which is slightly hyperattenuating and enhancing in comparison to the adjacent normal bladder wall in the post-contrast series. The masses are only identified in the post-contrast series. The bladder masses cause a transmural loss of wall layering. One of the masses is located more dorsally to the left side in the vesical trigone region, and there are signs of bladder neck invasion; it measures approximately 3.7 cm in length, 1.0 cm in width, and 1.1 cm in height. The second one is seen ventrally and caudally and is contiguous to the more dorsal mass. It measures approximately 2.8cm in length, 0.6cm in width, and 1.3cm in height. The remainder of the bladder wall is normal.

**SEX**

Male Neutered

**AGE**

15 Years

Due to the location of the dorsal mass in the vesical trigone, bilateral partial urethral obstruction is seen. The pelvis and ureters are bilaterally moderately distended. The proximal left ureter measures approximately 1.0cm in diameter, and the distal ureter measures 0.8cm in diameter. The right ureter measures approximately 0.9cm in diameter, and the distal ureter measures 0.8cm in diameter.

**INTERPRETED BY**

Tilde Rodrigues Froes, DMV, MSc., Dr. Med Vet., Dipl. CBraRVet

The bladder is filled with homogeneous hypoattenuating fluid material. The prostatic urethral pathway and wall definition are normal, although mildly distended. The prostate gland is normal in size, shape, and attenuation and measures approximately 1.8cm by 2.6cm.

Bilaterally, the renal pelvis is dilated. The right renal pelvis measures 0.7 cm, and the left renal pelvis measures 0.6cm.

**HOSPITAL NAME**

Animal Clinic of Queens

The renal length is 7.1 cm in the right kidney and 6.6 cm in the left kidney.

The abdominal and retroperitoneal fat attenuation is normal.

The abdominal lymph nodes, including the iliac medial and sacral, are normal.

**REFERRING VET**

Dr. Thomas

Cranial to the left kidney is a rounded, heterogeneous, and irregular mineralized mass that measures approximately 2.5cm by 3.2cm. Mild fat stranding and pinpoint mineralized foci are also seen adjacently.

The descending colon and rectum contain gas admixed with heterogeneously soft tissue attenuating fecal material.

**INVOICE**

58081

The remainder of the collimated abdomen is normal.

The L7-S1 intervertebral disc space is mildly narrowed with incomplete bridging spondylosis deformans. Faint mineralization of the L7-S1 intervertebral disc is seen.

**DATE**

5-2-23



**PATIENT** The right coxofemoral joint is subluxated with periarticular osteophytes.

Tucker Gosinco Abundant fat stores are seen in the subcutaneous tissues and throughout the abdomen.

**COMPUTED TOMOGRAPHIC DIAGNOSIS**

**SPECIES**

K9

- Multifocal raised wall bladder thickness/mass compatible with neoplasia. Differential diagnosis includes transitional cell carcinoma, squamous cell carcinoma, and less likely leiomyoma or leiomyosarcoma.

**BREED**

Lab Mix

- The position of the large mass is in the vesical trigone, and there is consequent partial ureteral obstruction. Distal ureteral invasion is considered, bilaterally. However, the mass is more on the left side.

**SEX**

Male Neutered

- Bilateral renal hydronephrosis, mild.
- Left abdominal partially mineralized fat mass. The differential diagnosis includes bates body/nodular fat necrosis, chronic granuloma with dystrophic mineralization.
- Otherwise, normal abdomen.
- L7-S1 chronic intervertebral disc disease and associated spondylosis deformans, with or without cauda equina impingement.
- Right side coxofemoral subluxation and osteoarthritis.
- Excessive body condition score.

**AGE**

15 Years

**INTERPRETATION OF THE FINDINGS & FURTHER RECOMMENDATIONS**

The tomographic findings confirm the presence of urinary bladder masses in the vesical trigone with neck invasion. No evidence of abdominal lymphadenopathy, or signs of abdominal or skeletal metastasis are seen. There is a limitation of the partial resectability of the mass because of the position.

**INTERPRETED BY**

Tilde Rodrigues Froes, DMV, MSc., Dr. Med Vet., Dipl. CBraRVet

Histology is required for confirmation of the diagnosis. Ultrasound-guided urethral polypropylene traumatic catheterization can be performed. The transcutaneous transabdominal ultrasound-guided biopsy is not recommended, as seeding of the biopsy tract is a possible sequela. Other options are cystoscopy or more invasive exploratory laparotomy.

**HOSPITAL NAME**

Animal Clinic of Queens

**REFERRING VET**

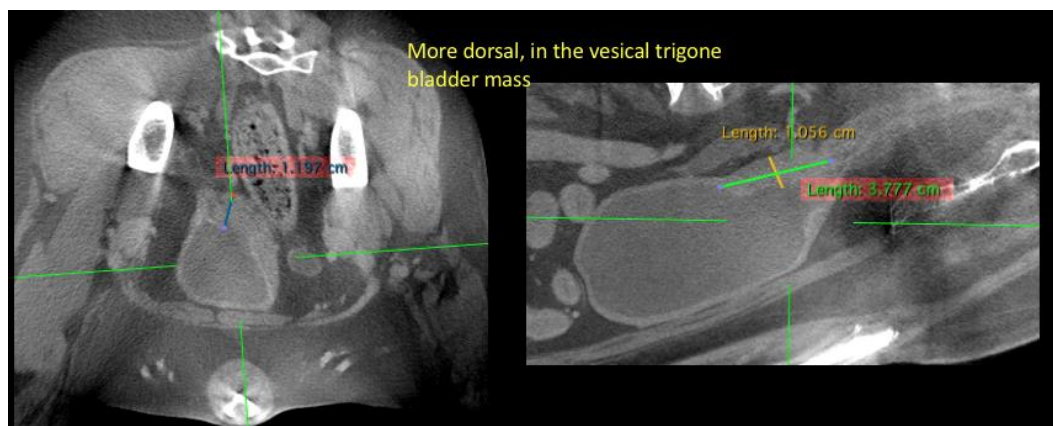
Dr. Thomas

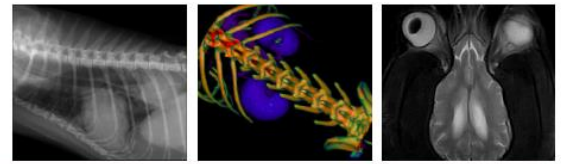
**INVOICE**

58081

**DATE**

5-2-23





**PATIENT**

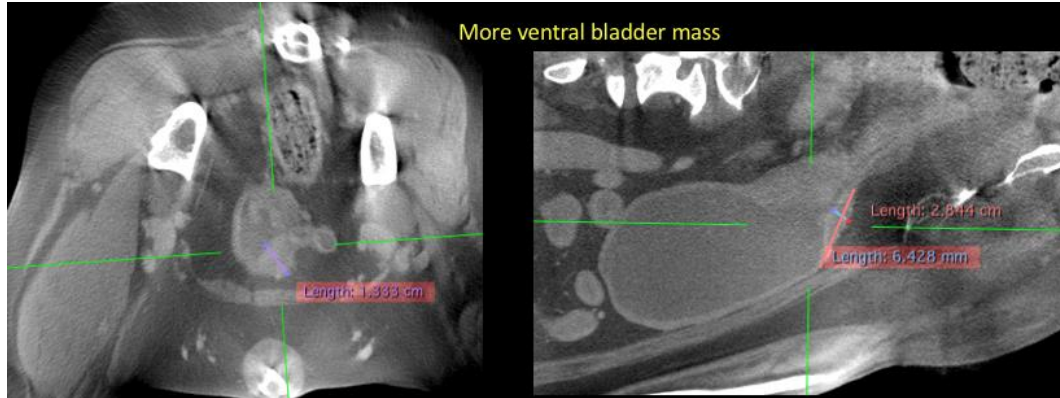
Tucker Gosinco

**SPECIES**

K9

**BREED**

Lab Mix



**SEX**

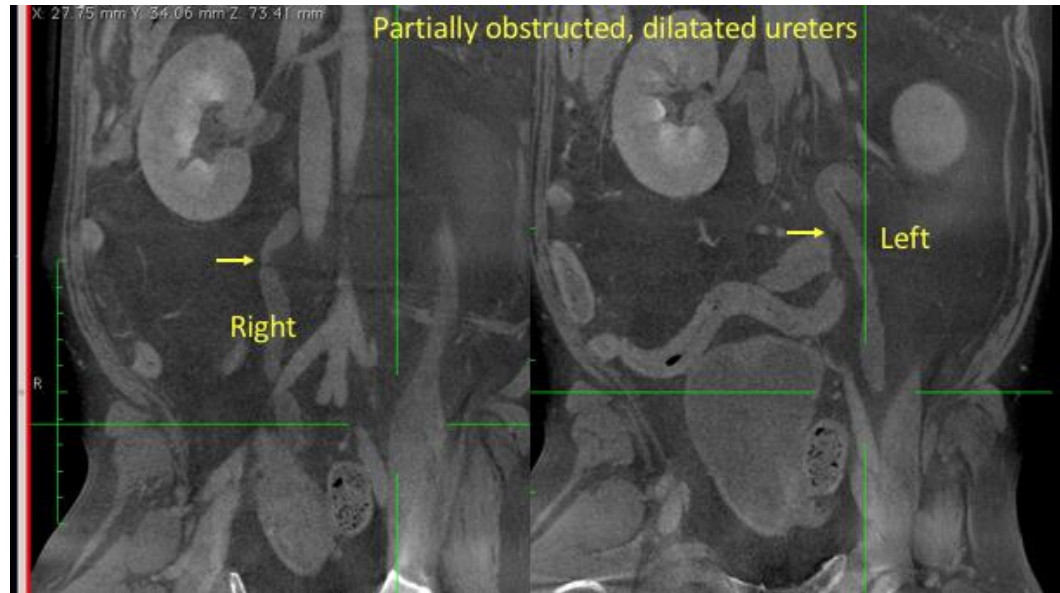Male Neutered

**AGE**

15 Years

**INTERPRETED BY**

Tilde Rodrigues Froes,  
DMV, MSc., Dr. Med  
Vet., Dipl. CBraRVet



**HOSPITAL NAME**

Animal Clinic of  
Queens

**REFERRING VET**

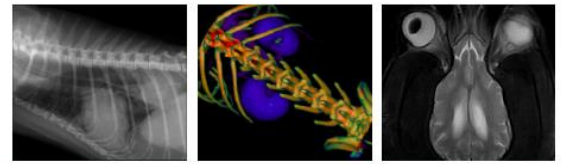
Dr. Thomas

**INVOICE**

58081

**DATE**

5-2-23



**PATIENT**

Tucker Gosinco

**SPECIES**

K9

**BREED**

Lab Mix

**SEX**

Male Neutered

**AGE**

15 Years

**INTERPRETED BY**

Tilde Rodrigues Froes,  
DMV, MSc., Dr. Med  
Vet., Dipl. CBraRVet

The information and recommendations provided are based on the images presented by the referring veterinarian. No evaluation can be communicated regarding pathology that was not visible in the image/video clips provided.

**HOSPITAL NAME**

Animal Clinics of  
Queens

Thank you for this referral. If the clinical or image interpretation does not parallel your findings or if I can be of any further assistance please contact me.

**Tilde Rodrigues Froes, DMV, MSc., Dr. Med.Vet., Dipl.CBraRVet**  
info@sonopath.com

**REFERRING VET**

Dr. Thomas

**INVOICE**

58081

**DATE**

5-2-23

