



PATIENT PRESENTING CLINICAL SIGNS

Sidney Rodriguez Sanchez The patient has splayed hind limbs more pronounced on the left, there is patellar clicking and instability on the left knee. No pain was elicited.

RADIOGRAPHIC STUDY OF THE PELVIC LIMBS

SPECIES

Canine

Radiographs of the pelvic limbs in two imaging planes are provided for review totaling five images. One ventral dorsal view, two lateral views focus on right limb and two lateral views focus on the left limb.

BREED

Miniature Poodle

RADIOGRAPHIC FINDINGS

Normal pelvis.

SEX

Female

The patellae are in normal position.
The stifle joints and fat-pad opacity are normal.

AGE

5 Months

The tarsocrural and tarsal joints are normal.
No traumatic or aggressive osseous lesions.
No asymmetric soft tissue swelling identified.

Normal juvenile open physes.

The caudal lumbar and lumbosacral spine collimated on the field are normal.

INTERPRETED BY

Tilde Rodrigues Froes, DMV, MSc., Dr. Med Vet., Dipl. CBraRVet

RADIOGRAPHIC DIAGNOSIS

- Normal stifle joints.
- Open juvenile physis.

INTERPRETATION OF THE FINDINGS & FURTHER RECOMMENDATIONS

HOSPITAL NAME

Paseos Veterinary Center

No signs of fracture or increased soft tissue volume in the left stifle considering the clinical history. If any future clinical signs or muscle mass atrophy is detected, considered as a next step approach, a distractor technique for evaluation of coxofemoral joint laxity. This may be useful in 9-12 months of age.

REFERRING VET

Dr. F. Ortiz, DVM

INVOICE

58077

DATE

5-2-23



PATIENT

Sidney Rodriguez
Sanchez

SPECIES

Canine

BREED

Miniature Poodle

SEX

Female

AGE

5 Months

INTERPRETED BY

Tilde Rodrigues Froes,
DMV, MSc., Dr. Med
Vet., Dipl. CBraRVet

HOSPITAL NAME

Paseos Veterinary
Center

REFERRING VET

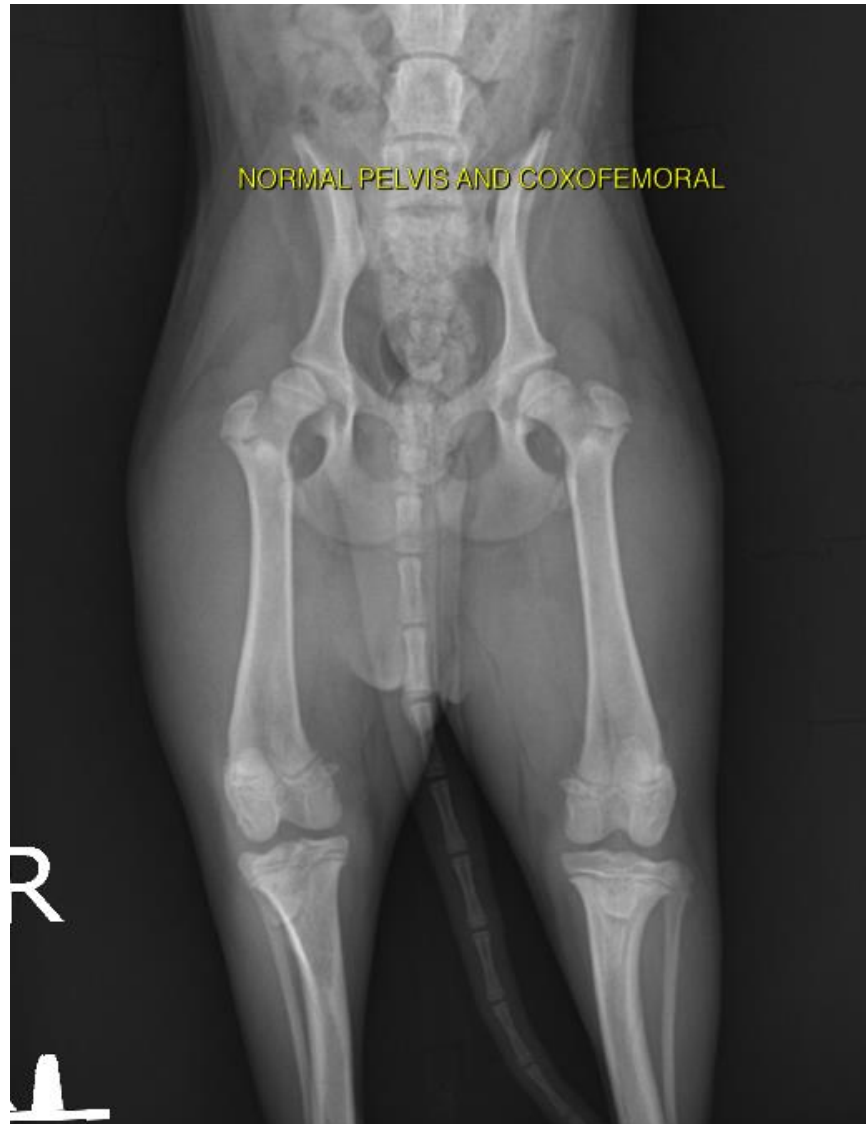Dr. F. Ortiz, DVM

INVOICE

58077

DATE

5-2-23





PATIENT

Sidney Rodriguez
Sanchez

SPECIES

Canine

BREED

Miniature Poodle

SEX

Female

AGE

5 Months

INTERPRETED BY

Tilde Rodrigues Froes,
DMV, MSc., Dr. Med
Vet., Dipl. CBraRVet

HOSPITAL NAME

Paseos Veterinary
Center

REFERRING VET

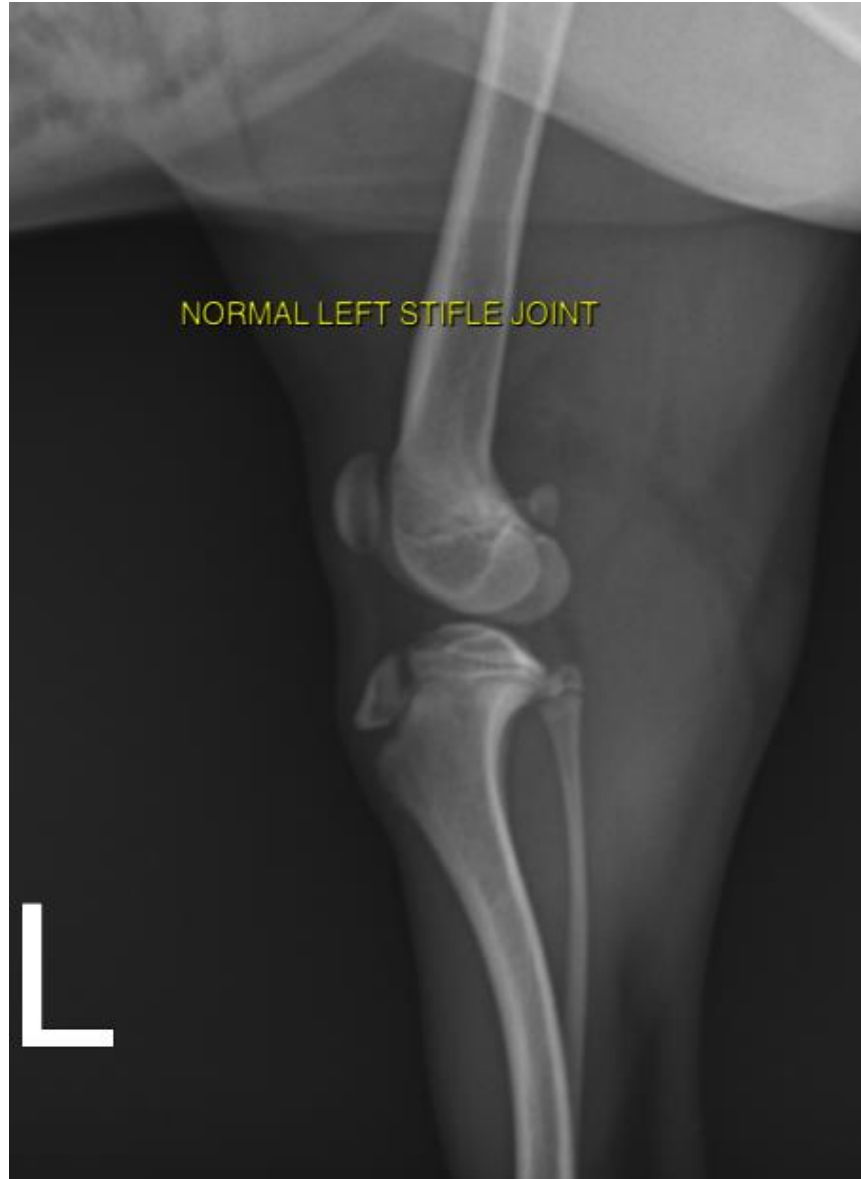
Dr. F. Ortiz, DVM

INVOICE

58077

DATE

5-2-23





PATIENT

Sidney Rodriguez
Sanchez

SPECIES

Canine

BREED

Miniature Poodle

SEX

Female

AGE

5 Months

INTERPRETED BY

Tilde Rodrigues Froes,
DMV, MSc., Dr. Med
Vet., Dipl. CBraRVet

HOSPITAL NAME

Paseos Veterinary
Center

REFERRING VET

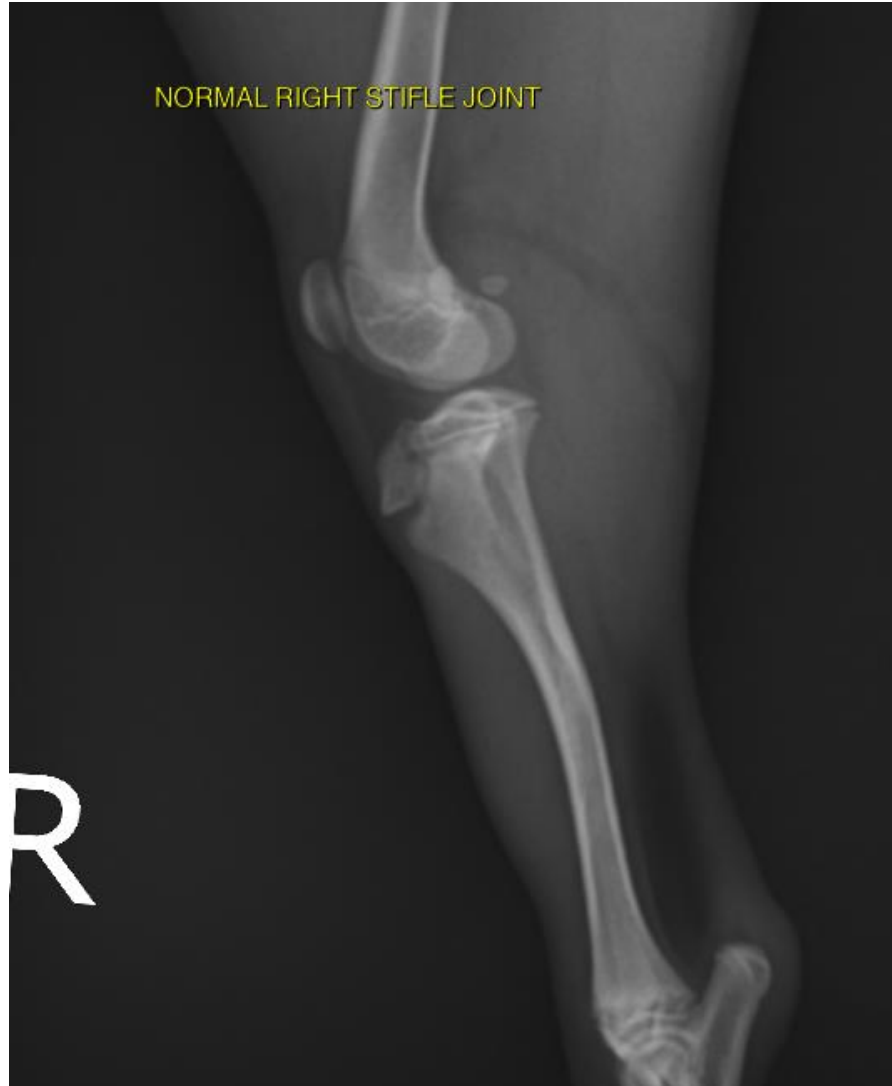Dr. F. Ortiz, DVM

INVOICE

58077

DATE

5-2-23



The information and recommendations provided are based on the images presented by the referring veterinarian. No evaluation can be communicated regarding pathology that was not visible in the image/video clips provided.

Thank you for this referral. If the clinical or image interpretation does not parallel your findings or if I can be of any further assistance please contact me.

Tilde Rodrigues Froes, DMV, MSc., Dr. Med.Vet., Dipl.CBraRVet
info@sonopath.com