



PATIENT PRESENTING CLINICAL SIGNS

Peppers Broom
 History of weight Loss Low energy Severe periodontal disease
 Abnormal PE/Chem/CBC/UA Results: CBC- Mild lymphopenia, likely attributable to stress. Chem panel- Mild Alk Phos elevation, and mild ALT elevation (less than twice the high end of normal limit).

SPECIES RADIOGRAPHIC STUDY OF THE THORAX AND ABDOMEN

Canine
 Orthogonal views of the thorax and abdomen are available for review totaling 3 images. Two lateral views and one ventrodorsal view, whole-body.

BREED RADIOGRAPHIC FINDINGS

Chihuahua **Abdomen**

SEX
 FS
 The hepatic silhouette is severely asymmetrically enlarged and mass-like, measuring approximately 8.3cm by 6.9cm. The mass has a round shape, heterogeneous soft tissue that is opaque, and multiple amorphous, linear, and irregular mineralized foci. Due to the mass-like lesion, the stomach is dorsally and caudally displaced, and the transverse colon is also caudally displaced.

AGE
 14 Years
 The visible portion of the spleen is normal in size, shape, and contour.

The stomach contains a moderate amount of gas admixed with homogeneous soft tissue opaque fluid material, which redistributes with the patient position.

INTERPRETED BY

Tilde Rodrigues Froes,
 DMV, MSc., Dr. Med
 Vet., Dipl. CBraRVet

The small intestines are normally distributed, of normal diameter, contain a moderate amount of gas and homogeneous soft tissue fluid material.

The colon contains a moderate amount of heterogeneous opaque fecal material and gas.

The abdominal serosal detail is normal. The retroperitoneal space is normal.

HOSPITAL NAME

Lacombe Veterinary
 Centre

The left renal silhouette is more clearly visible, and it is unremarkable. The right renal silhouette is partially visible, and unremarkable at this portion.

The urinary bladder is mildly filled with the apex in the plane of cranial L7 and is homogeneously soft tissue opaque.

REFERRING VET

Dr. Cindy Nowle

Thorax

The trachea is normal.

The cardiac silhouette, pulmonary vasculature, and parenchyma are normal.

INVOICE

58080

The pleural space and mediastinum are normal.

No evidence of soft tissue opaque pulmonary nodules or abnormal intrathoracic lymph nodes.

The thoracic wall and ribs are normal.

DATE

5-2-23



PATIENT The C4-C5, C5-C6 and C6-C7 intervertebral disc spaces are narrowed with associated spondylosis deformans.

Peppers Broom

T13 vertebral body is transitional with an absent right rib.

SPECIES The remainder of the musculoskeletal structures are unremarkable.

Canine

RADIOGRAPHIC DIAGNOSIS

BREED

Chihuahua

SEX

FS

AGE

14 Years

- Asymmetric hepatic enlargement with heterogeneous opacity: differential diagnosis includes hepatic neoplasms, for example, hepatocellular carcinoma, cholangiocarcinoma, and hemangiosarcoma. Less likely to be a benign neoplasm or abscess.
- Otherwise, normal abdomen.
- Normal thorax; no evidence of pulmonary metastatic disease or sternal lymphadenopathy.
- Multifocal, cervical chronic intervertebral disc disease, and spondylosis deformans with or without spinal or nerve root impingement.
- The T13 vertebral body is transitional with an absent right rib.

INTERPRETATION OF THE FINDINGS & FURTHER RECOMMENDATIONS

A hepatic mass is identified in the x-ray, and it is correlated to the clinical signs and laboratory results. The differential diagnosis includes hepatic neoplasm, less likely benign lesions. Gallbladder and biliary tract involvement are not possible to be evaluated by the radiographs. A biopsy is required for diagnosis. An abdominal ultrasound is recommended for further evaluation of the liver and gallbladder, and also to identify the possibility to perform a fine needle aspiration or guided biopsy.

INTERPRETED BY

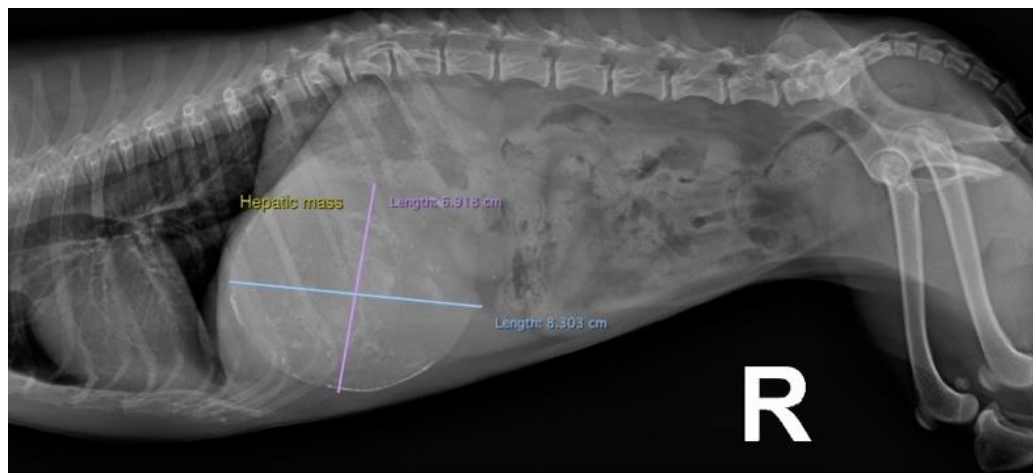
Tilde Rodrigues Froes,
DMV, MSc., Dr. Med
Vet., Dipl. CBraRVet

HOSPITAL NAME

Lacombe Veterinary
Centre

REFERRING VET

Dr. Cindy Nowle



INVOICE

58080

DATE

5-2-23



PATIENT

Peppers Broom

SPECIES

Canine

BREED

Chihuahua

SEX

FS

AGE

14 Years

INTERPRETED BY

Tilde Rodrigues Froes,
DMV, MSc., Dr. Med
Vet., Dipl. CBraRVet

HOSPITAL NAME

Lacombe Veterinary
Centre

REFERRING VET

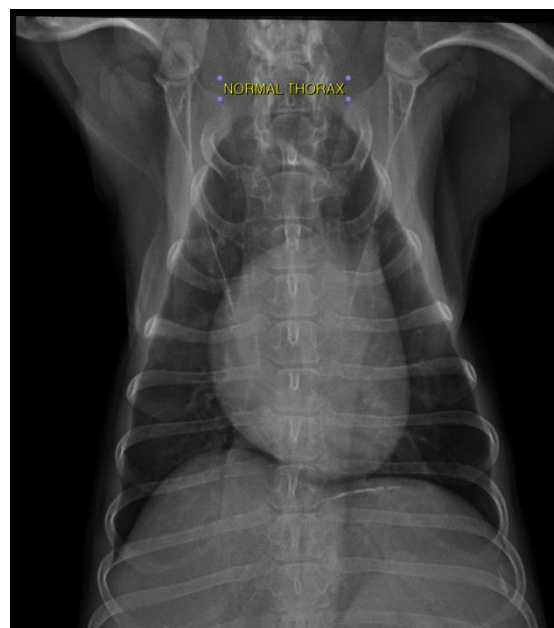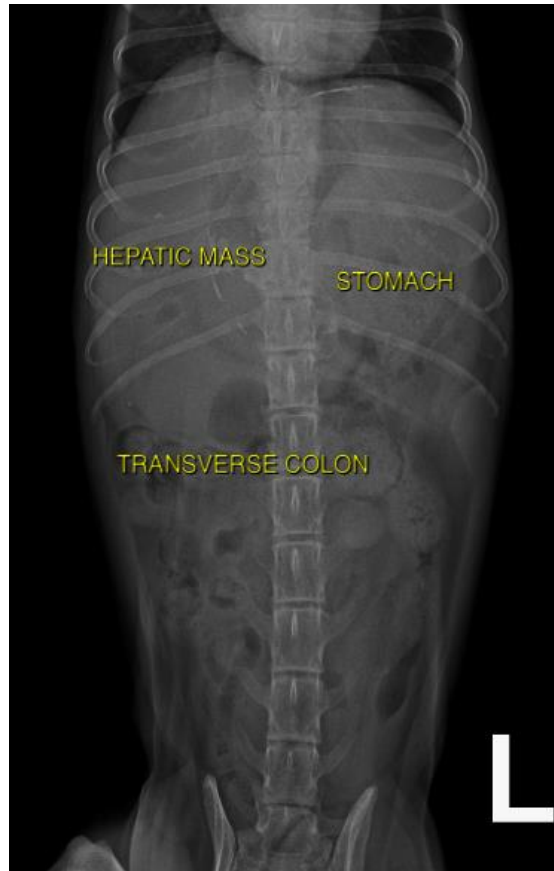Dr. Cindy Nowle

INVOICE

58080

DATE

5-2-23





PATIENT

Peppers Broom **The information and recommendations provided are based on the images presented by the referring veterinarian. No evaluation can be communicated regarding pathology that was not visible in the image/video clips provided.**

SPECIES

Canine Thank you for this referral. If the clinical or image interpretation does not parallel your findings or if I can be of any further assistance please contact me.

BREED

Chihuahua **Tilde Rodrigues Froes, DMV, MSc., Dr. Med.Vet., Dipl.CBraRVet**
info@sonopath.com

SEX

FS

AGE

14 Years

INTERPRETED BY

Tilde Rodrigues Froes,
DMV, MSc., Dr. Med
Vet., Dipl. CBraRVet

HOSPITAL NAME

Lacombe Veterinary
Centre

REFERRING VET

Dr. Cindy Nowle

INVOICE

58080

DATE

5-2-23