



PATIENT PRESENTING CLINICAL SIGNS

Gizmo Cleverton Puppy with intermittent neurologic signs - worse after eating. Elevated ALT and ALP. Low cholesterol, BUN and albumin. Glucose low end of normal. Concern for portosystemic shunt.
 Abnormal PE/Chem/CBC/UA Results: Elevated ALT and ALP. Low cholesterol, BUN and albumin.
 SPECIES Glucose low end of normal.

Canine **COMPUTED TOMOGRAPHIC STUDY OF THE ABDOMEN**

BREED A high-resolution pre-and post-contrast CT study of the abdomen are provided for review. Performed a CTA liver angiography with two phases scan, pre-contrast and post-contrast phase of full abdomen.

Yorkie Poo Mix **COMPUTED TOMOGRAPHIC FINDINGS**

SEX There is an anomalous shunting vessel that emerges from the right gastric vein, contributed with the splenic vein and feeding into the caudal vena cava at the level of the cranial pole of the right kidney. The portal vein cranial to the right gastric vein confluence severely decreases in size. The shunt vessel reaches a maximum diameter of approximately 0.62cm, and the portal vein in the porta hepatis reaches a maximum diameter of approximately 0.35cm.
 MI

AGE The hepatic and pre-hepatic caudal vena cava is distended.

7 Months The liver is moderately small in size, and the gastric axis is shifted cranially. The gallbladder is unremarkable, moderately hypoattenuating fluid distended.

INTERPRETED BY The kidneys are subjectively enlarged, with normal shape, and regular contour. One small linear mineral attenuating structure is seen in the left renal pelvis. It measures 0.7cm in length.

Tilde Rodrigues Froes, DMV, MSc., Dr. Med Vet., Dipl. CBraRVet A pinpoint mineral attenuating calculus is seen within the urinary bladder.

The spleen is normal size, homogeneously soft tissue attenuating, and uniformly contrast enhancing.

HOSPITAL NAME The stomach is normally distended and contains a small amount of homogeneous attenuating fluid material admixed and gas.

Animal Health Partners The duodenum and small intestine are mildly dilated and contain a small amount of homogeneous hypoattenuating fluid content and gas.

REFERRING VET The ascending and transverse colon are moderately distended and contains gas admixed with heterogeneous soft tissue attenuating fecal material. The descending colon is filled with gas.

Dr. Ashley Gold The pancreas and mesentery are normal.

INVOICE The abdominal lymph nodes and adrenal glands are normal.

58079 The left testicle is seen in the inguinal region, adjacently to the penis. The right testicle is in normal position.

DATE No other abnormalities are identified.

5-2-23



PATIENT COMPUTED TOMOGRAPHIC DIAGNOSIS

Gizmo Cleverton

- Right gastric caval extra-hepatic shunt with secondary microhepatia.
- Moderately reduced portal vein diameter in porta hepatis, portal vein functional hypoplasia secondary to PSS. Differential diagnosis primary portal vein hypoplasia.

SPECIES

Canine

- Bilaterally symmetric compensatory renomegaly.
- Single small nephrolithiasis in the left kidney.
- Pinpoint bladder sediments or microlithiasis.
- Left side ectopic testicle.

BREED

Yorkie Poo Mix

INTERPRETATION OF THE FINDINGS & FURTHER RECOMMENDATIONS

The suspected congenital portosystemic shunt is confirmed. Portal vein hypoplasia could be correlated to the shunt (functional); however, the reduced diameter is moderate, and portal vein morphological hypoplasia is considered. A small left kidney mineral nephrolithiasis is seen. A consult with a specialized center is recommended to discuss the best option for surgical treatment.

SEX

MI

AGE

7 Months

INTERPRETED BY

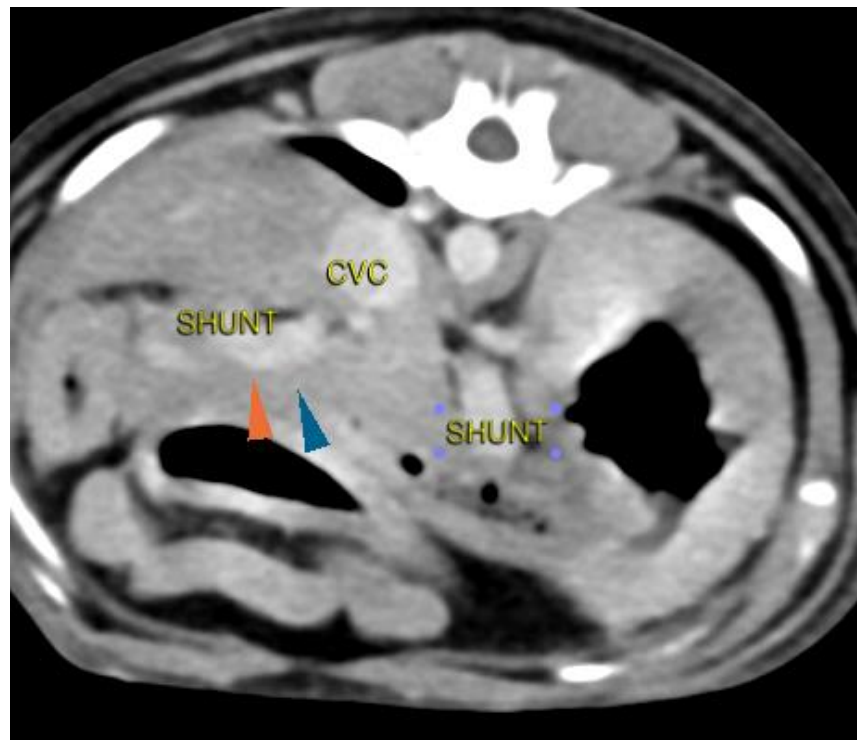
Tilde Rodrigues Froes, DMV, MSc., Dr. Med Vet., Dipl. CBraRVet

HOSPITAL NAME

Animal Health Partners

REFERRING VET

Dr. Ashley Gold



INVOICE

58079

DATE

5-2-23



PATIENT

Gizmo Cleverton

SPECIES

Canine

BREED

Yorkie Poo Mix

SEX

MI

AGE

7 Months

INTERPRETED BY

Tilde Rodrigues Froes,
DMV, MSc., Dr. Med
Vet., Dipl. CBraRVet

HOSPITAL NAME

Animal Health
Partners

REFERRING VET

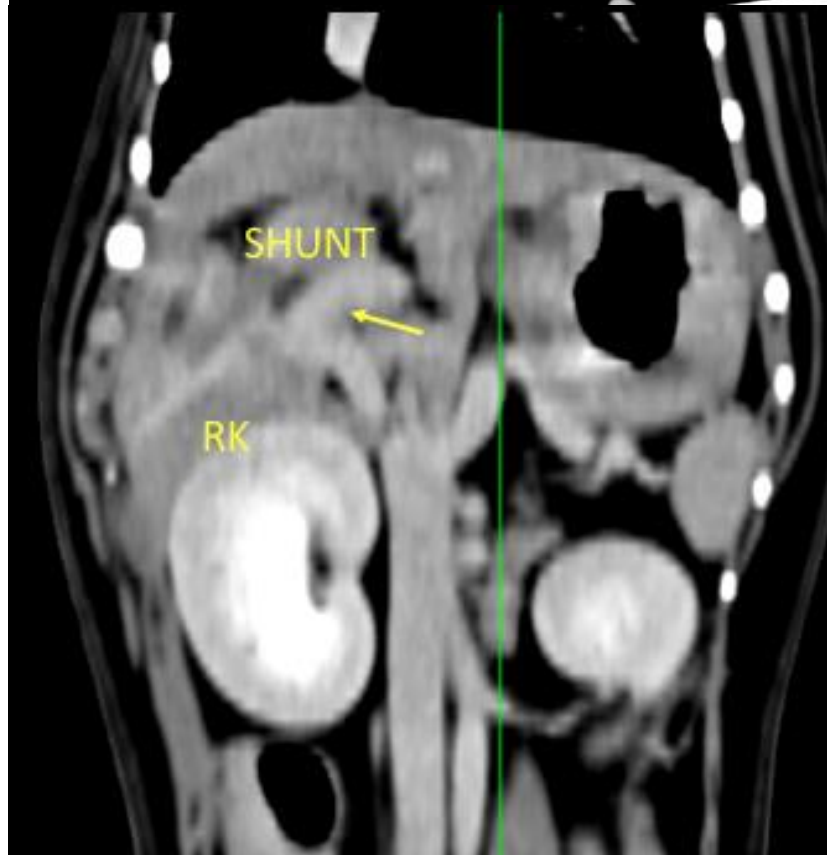
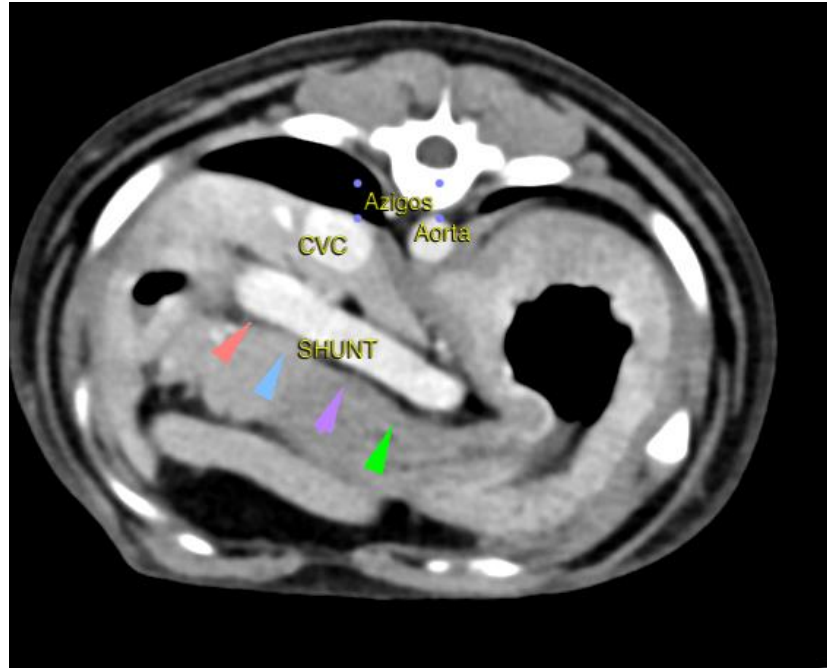
Dr. Ashley Gold

INVOICE

58079

DATE

5-2-23





PATIENT

Gizmo Cleverton

SPECIES

Canine

BREED

Yorkie Poo Mix

SEX

MI

AGE

7 Months

INTERPRETED BY

Tilde Rodrigues Froes,
DMV, MSc., Dr. Med
Vet., Dipl. CBraRVet

HOSPITAL NAME

Animal Health
Partners

REFERRING VET

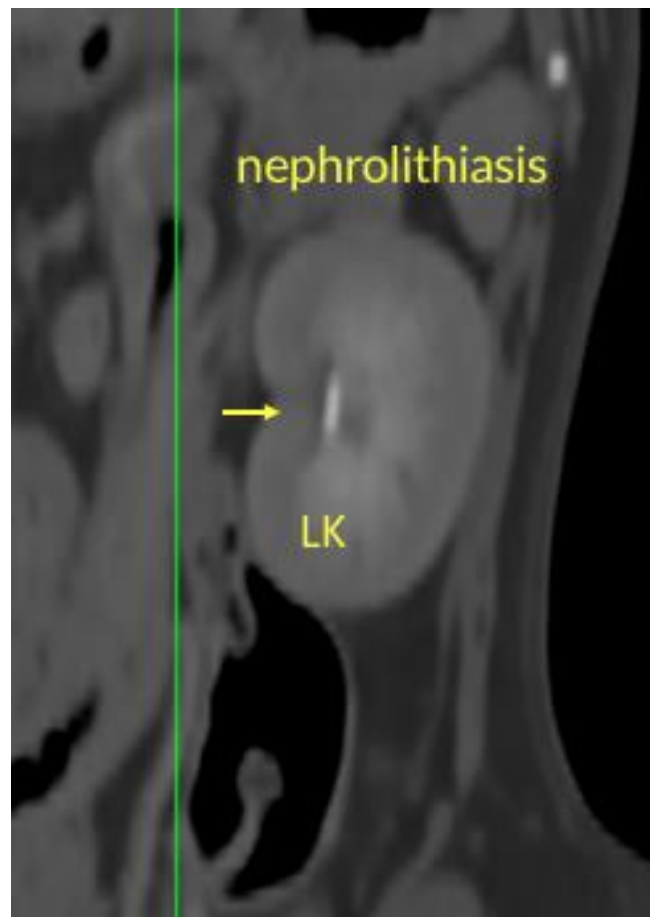
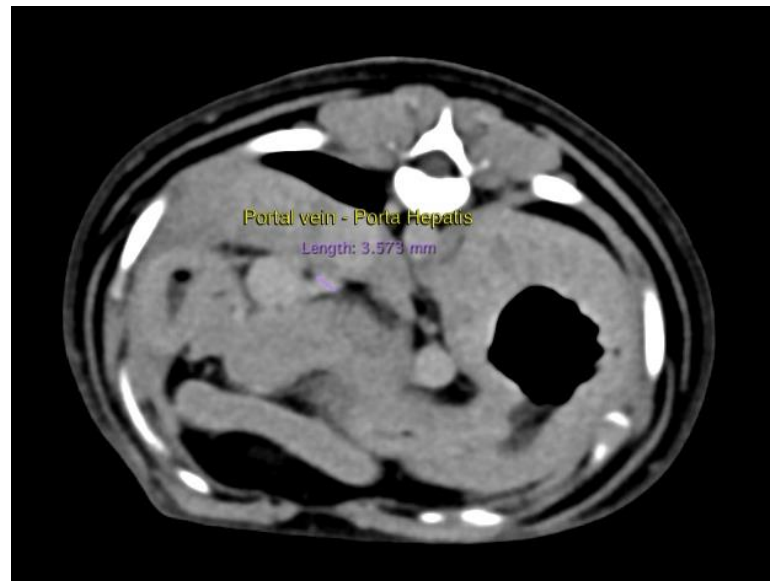
Dr. Ashley Gold

INVOICE

58079

DATE

5-2-23





PATIENT

Gizmo Cleverton

SPECIES

Canine

The information and recommendations provided are based on the images presented by the referring veterinarian. No evaluation can be communicated regarding pathology that was not visible in the image/video clips provided.

BREED

Yorkie Poo Mix

Thank you for this referral. If the clinical or image interpretation does not parallel your findings or if I can be of any further assistance please contact me.

Tilde Rodrigues Froes, DMV, MSc., Dr. Med.Vet., Dipl.CBraRVet
info@sonopath.com

SEX

MI

AGE

7 Months

INTERPRETED BY

Tilde Rodrigues Froes,
DMV, MSc., Dr. Med
Vet., Dipl. CBraRVet

HOSPITAL NAME

Animal Health
Partners

REFERRING VET

Dr. Ashley Gold

INVOICE

58079

DATE

5-2-23