

**Diagnostic Imaging**

Veterinary CT, Ultrasound & Teletology Services  
veterinarian referral only

**PATIENT PRESENTING CLINICAL SIGNS**

Malo Waugh  
Chronic lameness front leg  
Current Medications : Carprofen 75 mg

**SPECIES COMPUTED TOMOGRAPHIC STUDY OF THE THORACIC LIMBS**

Canine  
A pre- and post-contrast computed tomographic study of both elbow and shoulder joints was provided for review, totaling four series acquired in the transverse plane using a bone and soft tissue algorithm.

**BREED COMPUTED TOMOGRAPHIC FINDINGS**

Australian Shepherd

**LEFT THORACIC LIMB (ELBOW AND SHOULDER JOINTS)**

**SEX** The border of the left medial coronoid process is subtly hypoattenuating, with a suspected fissure line identified.

Male Neutered

The anconeal process is within normal limits.

**AGE** No significant periarticular osteophytic proliferation is observed.

3Y The humeroradial and humeroulnar articulations are congruent on multiplanar reformatted images.  
No evidence of joint effusion is identified.

**INTERPRETED BY**

Tilde Rodrigues Froes,  
DMV, MSc., Dr. Med  
Vet., Dipl. CBraRVet

The scapulohumeral joint, humerus, and scapula are unremarkable.

**RIGHT THORACIC LIMB (ELBOW AND SHOULDER JOINTS)**

The right medial coronoid process is within normal limits in contour and attenuation.

**HOSPITAL NAME**

Rockaway Animal  
Hospital

The anconeal process is within normal limits.

The humeroradial and humeroulnar articulations are congruent on multiplanar reformatted images.

The scapulohumeral joint, humerus, and scapula are unremarkable.

**REFERRING VET**

Dr. Harrs

**COMPUTED TOMOGRAPHIC DIAGNOSIS**

- Subtle hypoattenuation and suspected fissure line affecting the left medial coronoid process, compatible with medial compartmental disease.
- No CT abnormalities detected in the right elbow or bilateral shoulder joints.

**INVOICE**

75004

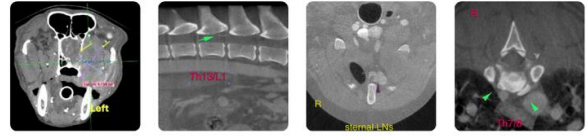
**INTERPRETATION OF THE FINDINGS & FURTHER RECOMMENDATIONS**

The tomographic findings support early or mild medial coronoid disease involving the left elbow, characterized by subtle hypoattenuation and a suspected fissure line of the medial coronoid process.

**DATE**

5-14-26

No evidence of secondary degenerative joint disease is identified at this time.



**Diagnostic Imaging**

Veterinary CT, Ultrasound & Telectology Services  
veterinarian referral only

**PATIENT**

Malo Waugh

Correlation with orthopedic examination and clinical localization of lameness is recommended. Arthroscopy may be considered for definitive evaluation and potential treatment if clinical signs persist despite conservative management.

**SPECIES**

Canine

**BREED**

Australian Shepherd

**SEX**

Male Neutered

**AGE**

3Y

**INTERPRETED BY**

Tilde Rodrigues Froes,  
DMV, MSc., Dr. Med  
Vet., Dipl. CBraRVet

**HOSPITAL NAME**

Rockaway Animal  
Hospital

**REFERRING VET**

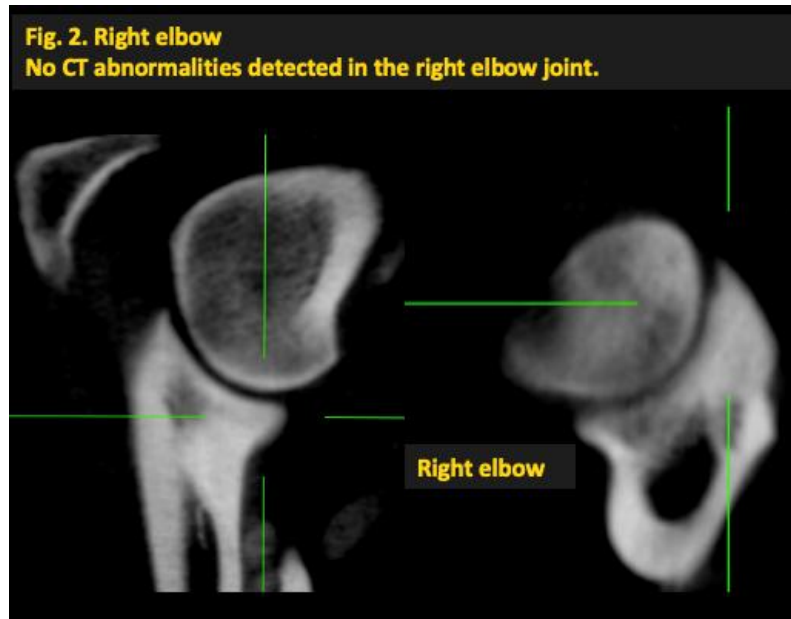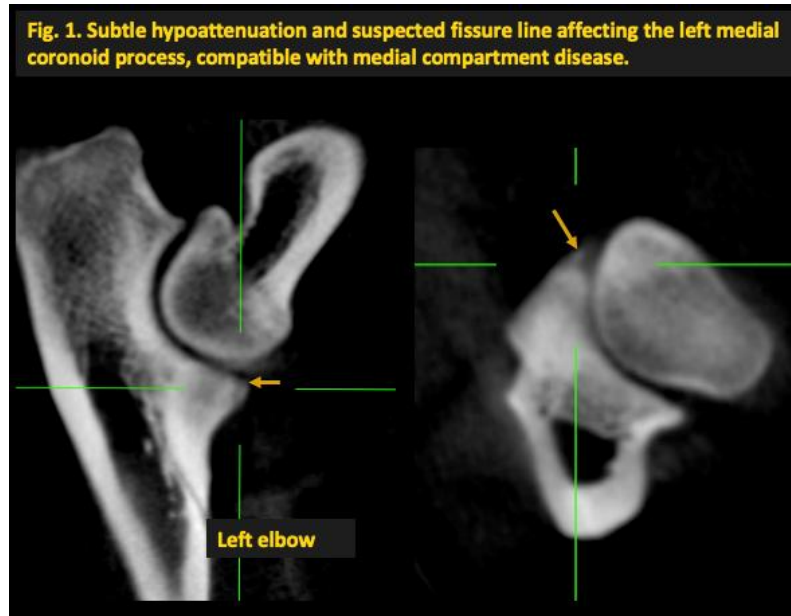
Dr. Harrs

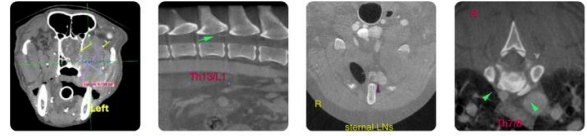
**INVOICE**

75004

**DATE**

5-14-26





**Diagnostic Imaging**

Veterinary CT, Ultrasound & Telectology Services  
veterinarian referral only

SonoPath.com | info@sonopath.com | 1 (800) 838-4268  
141 Main St, Andover, NJ 07821

**PATIENT**

Malo Waugh

**SPECIES**

Canine

**BREED**

Australian Shepherd

**SEX**

Male Neutered

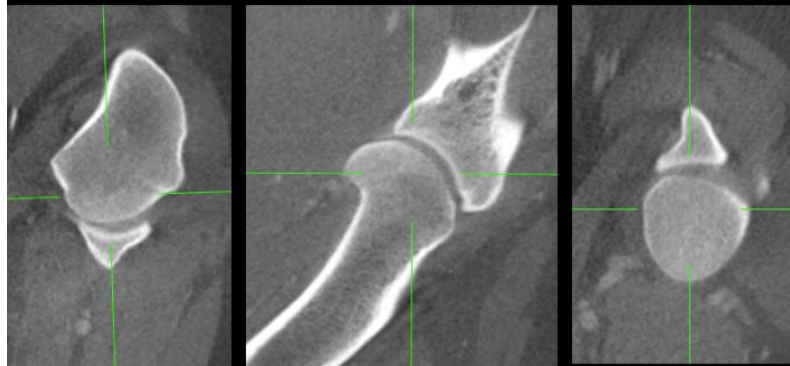
**AGE**

3Y

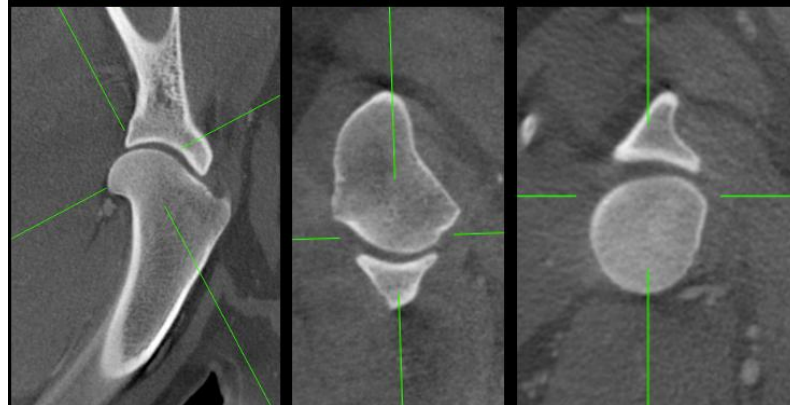
**INTERPRETED BY**

Tilde Rodrigues Froes,  
DMV, MSc., Dr. Med  
Vet., Dipl. CBraRVet

**Fig. 3. Left shoulder**  
Normal appearance of the left shoulder joint on CT examination.



**Fig. 4. Right shoulder**  
Normal appearance of the right shoulder joint on CT examination.



**HOSPITAL NAME**

Rockaway Animal  
Hospital

The information and recommendations provided are based on the images presented by the referring veterinarian. No evaluation can be communicated regarding pathology that was not visible in the image/video clips provided.

Thank you for this referral. If the clinical or image interpretation does not parallel your findings or if I can be of any further assistance please contact me.

**REFERRING VET**

Dr. Harrs

Tilde Rodrigues Froes, DMV, MSc., Dr. Med.Vet., Dipl.CBraRVet  
[info@sonopath.com](mailto:info@sonopath.com)

**INVOICE**

75004

**DATE**

5-14-26