



PATIENT

Fitz Rodriguez

SPECIES

Canine

BREED

Mixed Lg.

SEX

Male Neutered

AGE

9Y

WEIGHT

115

INTERPRETED BY

Tilde Rodrigues Froes,
DMV, MSc., Dr. Med
Vet., Dipl. CBraRVet

IMAGING PERFORMED BY

Dr. Abina Glennon

HOSPITAL NAME

New Bridge Veterinary
Practice

REFERRING VET

Dr. Abina Glennon

INVOICE

74983

DATE

5-13-26

PRESENTING CLINICAL SIGNS

Stops on walks- lays down for 20 mins before getting up
No murmur

RADIOGRAPHIC STUDY OF THE THORAX

Single right lateral projection.

RADIOGRAPHIC FINDINGS

The trachea is normal in diameter and position.

The cardiac silhouette is within expected radiographic limits for size and shape on the provided projection. (VHS = 10.2)

The pulmonary parenchyma is within normal limits of expansion and opacity.

The pulmonary vessels are within normal limits.

The pleural space and visible mediastinum are unremarkable.

The diaphragm, thoracic wall, and visible osseous structures are within normal radiographic limits.

RADIOGRAPHIC DIAGNOSIS

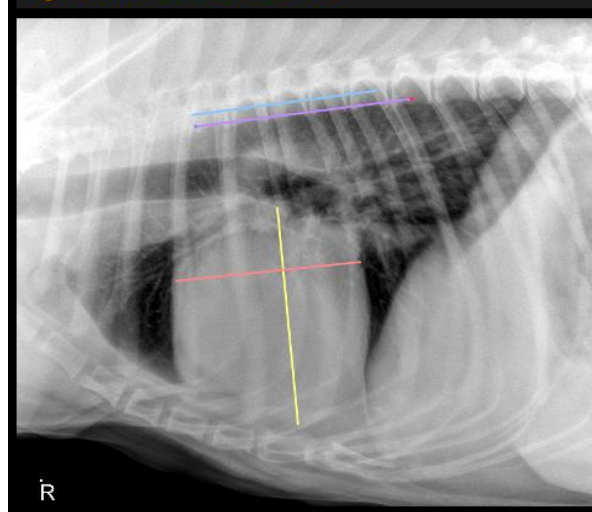
- No radiographic abnormalities identified on the provided image.

INTERPRETATION OF THE FINDINGS & FURTHER RECOMMENDATIONS

No radiographic abnormalities are identified on the provided image.

If clinical signs persist or progress, a complete three-view thoracic radiographic study is recommended for more comprehensive evaluation.

Fig. 1. Normal thorax. VHS – 10.2





PATIENT

Fitz Rodriguez

SPECIES

Canine

BREED

Mixed Lg.

SEX

Male Neutered

AGE

9Y

WEIGHT

115

INTERPRETED BY

Tilde Rodrigues Froes,
DMV, MSc., Dr. Med
Vet., Dipl. CBraRVet

IMAGING PERFORMED BY

Dr. Abina Glennon

HOSPITAL NAME

New Bridge Veterinary
Practice

REFERRING VET

Dr. Abina Glennon

INVOICE

74983

DATE

5-13-26

The information and recommendations provided are based on the images presented by the referring veterinarian. No evaluation can be communicated regarding pathology that was not visible in the image/video clips provided.

Thank you for this referral. If the clinical or image interpretation does not parallel your findings or if I can be of any further assistance, please contact me.

Tilde Rodrigues Froes, DMV, MSc., Dr. Med.Vet., Dipl.CBraRVet
info@sonopath.com