



PATIENT

Cooper Delonti

SPECIES

Canine

BREED

Basset Hound

SEX

MN

AGE

9

WEIGHT

30

INTERPRETED BY

Tilde Rodrigues Froes,
DMV, MSc., Dr. Med
Vet., Dipl. CBraRVet

IMAGING PERFORMED BY

Dr. Runde

HOSPITAL NAME

Northeast Veterinary
Referral Hospital

REFERRING VET

Dr. Runde

INVOICE

74980

DATE

5-13-26

PRESENTING CLINICAL SIGNS

Presented for a history of pulmonary mass noted on radiographs. Patient has a history of diabetes mellitus and bilateral cataracts. No obvious clinical signs are reported by the owners.
Abnormal PE/Chem/CBC/UA Results: blood sugar 162

COMPUTED TOMOGRAPHIC STUDY OF THE THORAX AND ABDOMEN

A pre- and post-contrast CT study of the thorax and abdomen is provided for review totaling 3 series. One pre-contrast series of the thorax (bone algorithm). One post-contrast series of the thorax (soft tissue algorithm). One post-contrast series of the abdomen (soft tissue algorithm).

COMPUTED TOMOGRAPHIC FINDINGS

THORAX

A rounded soft tissue attenuating mass is identified within the right middle lung lobe, measuring approximately 3.0 × 3.7 cm, located at the level of the right 5th to 7th intercostal spaces. The remaining pulmonary parenchyma demonstrates normal attenuation, with no evidence of additional pulmonary nodules or masses.

The trachea and main bronchi are within normal limits.

The cardiac silhouette and pulmonary vasculature are unremarkable, with adequate post-contrast vascular opacification.

The pleural space, diaphragm and thoracic esophagus are unremarkable.

The sternal, cranial mediastinal, and tracheobronchial lymph nodes are within normal limits.

Multiple costochondral degenerative changes and mild sternbral degenerative changes are present.

A small elongated homogeneous fat-attenuating mass is present within the ventral left thoracic wall, measuring approximately 4.3 × 2.1 cm.

ABDOMEN

The liver is homogeneous in attenuation and demonstrates uniform contrast enhancement, with normal size and shape. The gallbladder is within normal limits.

A moderately enlarged rounded soft tissue attenuating structure is identified between the splenic head, stomach, and abdominal wall, most consistent with an enlarged splenic lymph node, measuring approximately 1.3 × 1.4 cm. The remaining abdominal lymph nodes are within normal limits.

The kidneys are normal in size, shape, contour, and attenuation pre- and post-contrast. The renal pelves and ureters are within normal limits.

The urinary bladder is moderately distended with hypoattenuating fluid admixed with contrast material. The urinary bladder wall thickness is within normal limits.

The gastrointestinal tract is normally distended and anatomically distributed, without evidence of mural thickening or mass effect. The colon contains heterogeneous fecal material admixed with gas.



PATIENT

Cooper Delonti

SPECIES

Canine

BREED

Basset Hound

SEX

MN

AGE

9

WEIGHT

30

INTERPRETED BY

Tilde Rodrigues Froes,
DMV, MSc., Dr. Med
Vet., Dipl. CBraRVet

IMAGING PERFORMED BY

Dr. Runde

HOSPITAL NAME

Northeast Veterinary
Referral Hospital

REFERRING VET

Dr. Runde

INVOICE

74980

DATE

5-13-26

The pancreas and adrenal glands are within normal limits.

The serosal fat demonstrates normal attenuation.

The prostate is small and intrapelvic, compatible with neutered status.

Bilateral coxofemoral joint incongruity with mild periarticular osteophytosis is noted. A subchondral cyst is present at the margin of the left sacroiliac joint.

An in situ mineralized intervertebral disc is present at L7-S1.

COMPUTED TOMOGRAPHIC DIAGNOSIS

- Rounded soft tissue attenuating pulmonary mass within the right middle lung lobe. Differential diagnoses include primary pulmonary neoplasia (such as pulmonary adenocarcinoma), less likely metastatic disease, or pulmonary granuloma.
- Small, elongated fat-attenuating mass within the ventral left thoracic wall, most consistent with lipoma.
- Mild enlargement of a splenic lymph node. Primary differential diagnoses include reactive lymphadenitis, less likely serosal soft tissue mass.
- Mild bilateral coxofemoral osteoarthritis.
- Subchondral cyst involving the left sacroiliac joint.
- L7-S1 intervertebral disc mineralization.

INTERPRETATION OF THE FINDINGS & FURTHER RECOMMENDATIONS

The tomographic findings confirm the presence of a solitary rounded pulmonary mass located within the right middle lung lobe. The primary differential diagnoses include primary pulmonary neoplasia (e.g., adenocarcinoma, squamous cell carcinoma, or bronchioloalveolar carcinoma), although granulomatous disease remains a differential consideration.

No evidence of additional pulmonary nodules or thoracic lymphadenopathy is identified on this examination.

The mildly enlarged splenic lymph node may represent reactive change; however, metastatic involvement cannot be entirely excluded.

Thoracic ultrasonography-guided fine-needle aspiration may be feasible, as the lesion is closely associated with the thoracic wall at the level of the 5th-7th intercostal spaces. Oncologic consultation is recommended.



PATIENT

Cooper Delonti

SPECIES

Canine

BREED

Basset Hound

SEX

MN

AGE

9

WEIGHT

30

INTERPRETED BY

Tilde Rodrigues Froes, DMV, MSc., Dr. Med Vet., Dipl. CBraRVet

IMAGING PERFORMED BY

Dr. Runde

HOSPITAL NAME

Northeast Veterinary Referral Hospital

REFERRING VET

Dr. Runde

INVOICE

74980

DATE

5-13-26

Fig. 1. Rounded soft tissue attenuating pulmonary mass within the right middle lung lobe

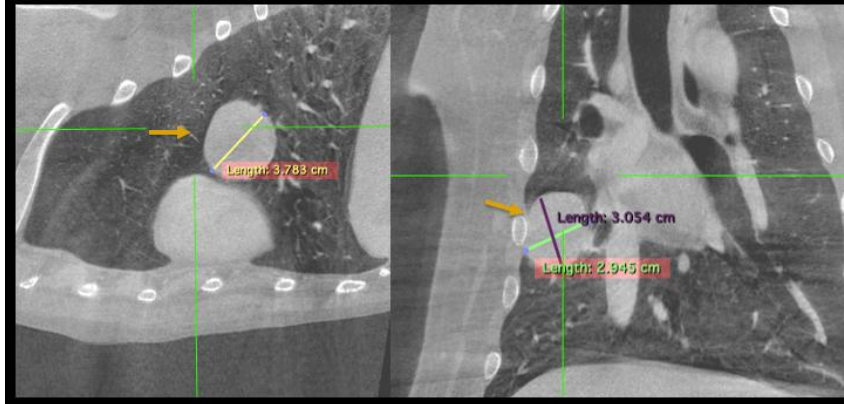


Fig. 2. Moderately enlarged rounded soft tissue attenuating structure located between the splenic head, stomach, and abdominal wall.

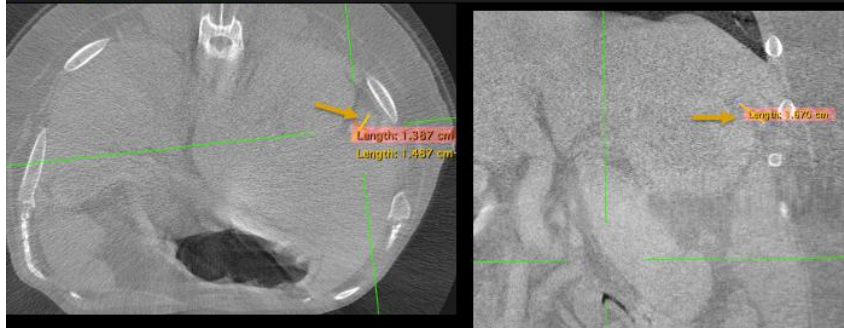
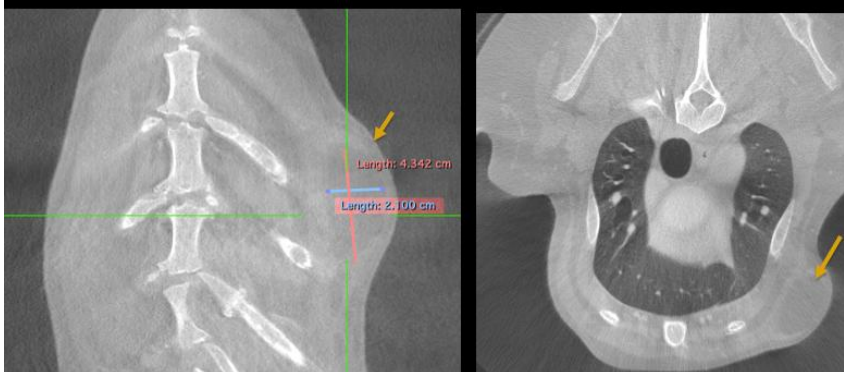

Fig. 3. Small elongated homogeneous fat-attenuating mass within the ventral left thoracic wall





Teleradiology

Educational Teleconsultation Services™

PATIENT

Cooper Delonti

SPECIES

Canine

BREED

Basset Hound

SEX

MN

AGE

9

WEIGHT

30

INTERPRETED BY

Tilde Rodrigues Froes,
DMV, MSc., Dr. Med
Vet., Dipl. CBraRVet

IMAGING PERFORMED BY

Dr. Runde

HOSPITAL NAME

Northeast Veterinary
Referral Hospital

REFERRING VET

Dr. Runde

INVOICE

74980

DATE

5-13-26

The information and recommendations provided are based on the images presented by the referring veterinarian. No evaluation can be communicated regarding pathology that was not visible in the image/video clips provided.

Thank you for this referral. If the clinical or image interpretation does not parallel your findings or if I can be of any further assistance, please contact me.

Tilde Rodrigues Froes, DMV, MSc., Dr. Med.Vet., Dipl.CBraRVet
info@sonopath.com