



PATIENT

Teak Kudwa

SPECIES

Canine

BREED

Fox Terrier

SEX

Male Neutered

AGE

4Y

WEIGHT

15.7lbs

INTERPRETED BY

Tilde Rodrigues Froes,
DMV, MSc., Dr. Med
Vet., Dipl. CBraRVet

IMAGING PERFORMED BY

Dr. Burge

HOSPITAL NAME

Wilson Veterinary
Hospital

REFERRING VET

Dr. Dincau

INVOICE

74516

DATE

4-8-26

PRESENTING CLINICAL SIGNS

Chronic coughing, especially when excited, for a few months.

Significant increased exercise intolerance and dyspnea in the last 2 weeks.

Radiographs of the neck showed complete loss of visual of the trachea around the thoracic inlet - unable to determine if there is a mass effect in the area or severe tracheal collapse

COMPUTED TOMOGRAPHIC STUDY OF THE NECK

A pre- and post-contrast CT study of the neck was provided for review, totaling 2 series. One pre-contrast series acquired using a bone algorithm and one post-contrast series acquired using a soft tissue algorithm.

COMPUTED TOMOGRAPHIC FINDINGS

There is marked reduction in dorsoventral diameter of the caudal cervical trachea, extending into the thoracic trachea with slightly lesser severity distally toward the carina. The most severe narrowing is centered at the level of C6-T1, where the degree of luminal collapse is compatible with grade 4 tracheal collapse. There is no evidence of focal mural thickening, intraluminal fluid accumulation, or adjacent extramural mass effect.

The left principal bronchus is only partially included in the field of view; however, the visible portion also appears narrowed.

The thyroid cartilage, cricoid cartilage, and hyoid apparatus are within normal limits.

The medial retropharyngeal lymph nodes are within normal limits.

The mandibular and parotid salivary glands are unremarkable.

The thyroid glands are unremarkable.

The cervical esophagus is unremarkable.

The cervical spine and cervicothoracic osseous structures included in the study are unremarkable.

There is marked fat accumulation within the dorsal and ventral subcutaneous cervicothoracic soft tissues, extending into the cranial mediastinal region.

COMPUTED TOMOGRAPHIC DIAGNOSIS

- Severe tracheal narrowing/collapse involving the caudal cervical trachea and extending into the thoracic trachea, with the most severe segment at C6-T1, compatible with grade 4 tracheal collapse.
- Suspected concurrent narrowing of the left principal bronchus (partially evaluated).
- No CT evidence of a cervical or thoracic inlet extramural mass effect causing the tracheal narrowing within the scanned field.
- Marked cervicothoracic and cranial mediastinal fat deposition.



PATIENT

Teak Kudwa

SPECIES

Canine

BREED

Fox Terrier

SEX

Male Neutered

AGE

4Y

WEIGHT

15.7lbs

INTERPRETED BY

Tilde Rodrigues Froes,
DMV, MSc., Dr. Med
Vet., Dipl. CBraRVet

**IMAGING
PERFORMED BY**

Dr. Burge

HOSPITAL NAME

Wilson Veterinary
Hospital

REFERRING VET

Dr. Dincau

INVOICE

74516

DATE

4-8-26

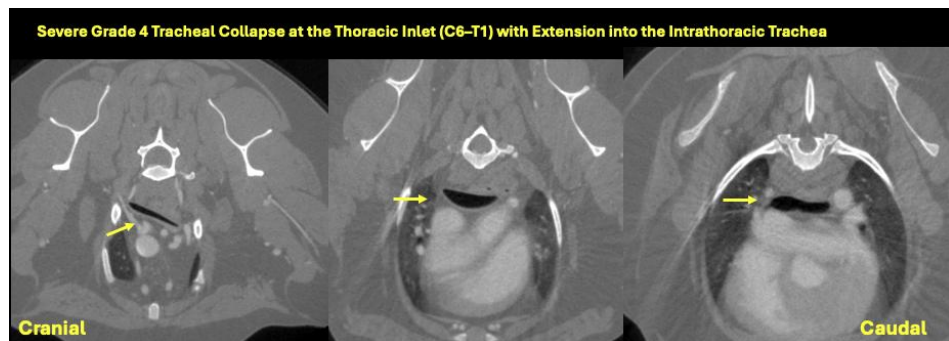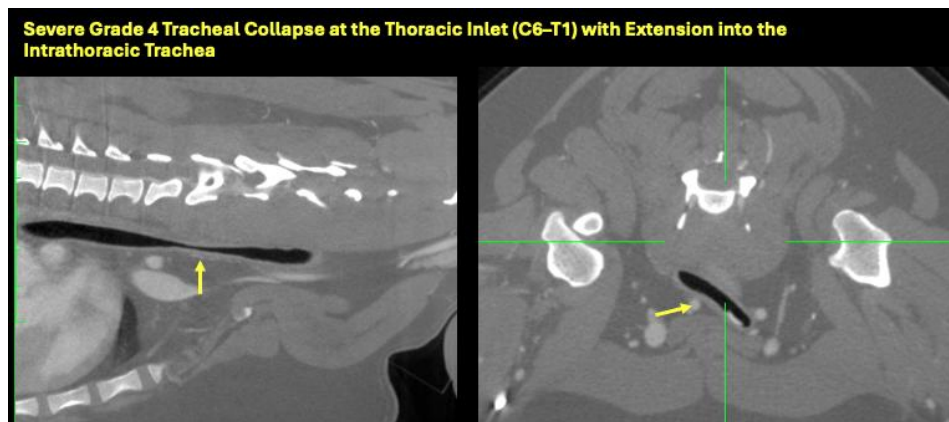
INTERPRETATION OF THE FINDINGS & FURTHER RECOMMENDATIONS

The tomographic findings support severe tracheal collapse, most pronounced at the thoracic inlet (C6 – T1), extending through the intrathoracic trachea toward the carina. These findings explain the reported history of chronic cough, exercise intolerance, and recent dyspnea.

There is also suspected concurrent collapse of the left principal bronchus; however, this region is only partially included in the field of view and therefore cannot be fully characterized on the present study.

A combination of tracheobronchoscopy and/or fluoroscopic evaluation is recommended for definitive grading and to assess the extent of mainstem bronchial involvement, particularly given the dynamic nature of tracheal collapse.

Clinical correlation is advised to determine whether the patient may benefit from medical management. If severe or refractory clinical signs persist, interventional airway evaluation may be warranted.





PATIENT

Teak Kudwa

SPECIES

Canine

BREED

Fox Terrier

SEX

Male Neutered

AGE

4Y

WEIGHT

15.7lbs

INTERPRETED BY

Tilde Rodrigues Froes,
DMV, MSc., Dr. Med
Vet., Dipl. CBraRVet

IMAGING PERFORMED BY

Dr. Burge

HOSPITAL NAME

Wilson Veterinary
Hospital

REFERRING VET

Dr. Dincau

INVOICE

74516

DATE

4-8-26

The information and recommendations provided are based on the images presented by the referring veterinarian. No evaluation can be communicated regarding pathology that was not visible in the image/video clips provided.

Thank you for this referral. If the clinical or image interpretation does not parallel your findings or if I can be of any further assistance, please contact me.

Tilde Rodrigues Froes, DMV, MSc., Dr. Med.Vet., Dipl.CBraRVet
info@sonopath.com