



PATIENT

Rue Bustamante &
Clemente

SPECIES

Feline

BREED

DSH

SEX

Female Spayed

AGE

6M

WEIGHT

9.1lbs

INTERPRETED BY

Tilde Rodrigues Froes,
DMV, MSc., Dr. Med
Vet., Dipl. CBraRVet

IMAGING PERFORMED BY

Jennifer and Chelsea

HOSPITAL NAME

Northvale Veterinary
Clinic

REFERRING VET

Dr. Stefanie Simon

INVOICE

74518

DATE

4-8-26

PRESENTING CLINICAL SIGNS

Panting for the past 24 hours intermittently. Echocardiogram performed as well today by SonoPath.

RADIOGRAPHIC STUDY OF THE THORAX

Orthogonal views of the thorax are available for review totaling three images. One ventrodorsal view. One right lateral and one left lateral views.

RADIOGRAPHIC FINDINGS

The trachea is normal in position and diameter.

A mild diffuse bronchial pulmonary pattern is present, more evident in the caudodorsal lung regions.

Pulmonary vessels are within normal limits in size and distribution.

The cardiac silhouette is within normal limits in size and contour (VHS approximately 7.9).

Mild fat opacity is present within the cranial mediastinum/pericardial region.

The pleural space is unremarkable.

The diaphragm, ribs, and thoracic wall are within normal limits.

The 7th sternebra is shortened, and there is mild pectus excavatum (incidental).

The visible cranial abdomen is unremarkable.

RADIOGRAPHIC DIAGNOSIS

- Mild diffuse bronchial pulmonary pattern. Differential diagnoses include mild inflammatory lower airway disease (e.g., early inflammatory bronchitis, infectious bronchitis or feline asthma).
- Incidental mild pectus excavatum and sternebra variation.

INTERPRETATION OF THE FINDINGS & FURTHER RECOMMENDATIONS

The radiographic findings are mild bronchial pulmonary pattern, which may be consistent with early or mild lower airway disease, including inflammatory or allergic conditions such as feline asthma.

There is no radiographic evidence of cardiomegaly or cardiogenic pulmonary disease to explain the reported panting. Correlation with the echocardiographic findings is recommended for comprehensive cardiac assessment, due to better sensibility.

If clinical signs persist, further evaluation of the lower airways (e.g., bronchoalveolar lavage) may be considered.



PATIENT

Rue Bustamante &
Clemente

SPECIES

Feline

BREED

DSH

SEX

Female Spayed

AGE

6M

WEIGHT

9.1lbs

INTERPRETED BY

Tilde Rodrigues Froes,
DMV, MSc., Dr. Med
Vet., Dipl. CBraRVet

IMAGING PERFORMED BY

Jennifer and Chelsea

HOSPITAL NAME

Northvale Veterinary
Clinic

REFERRING VET

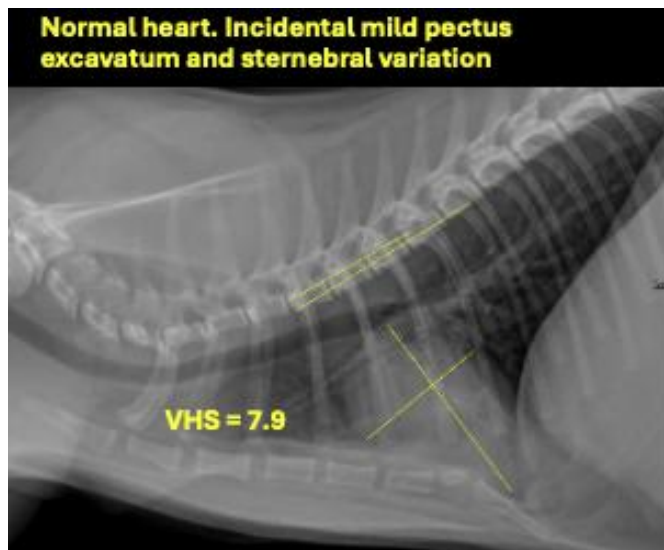
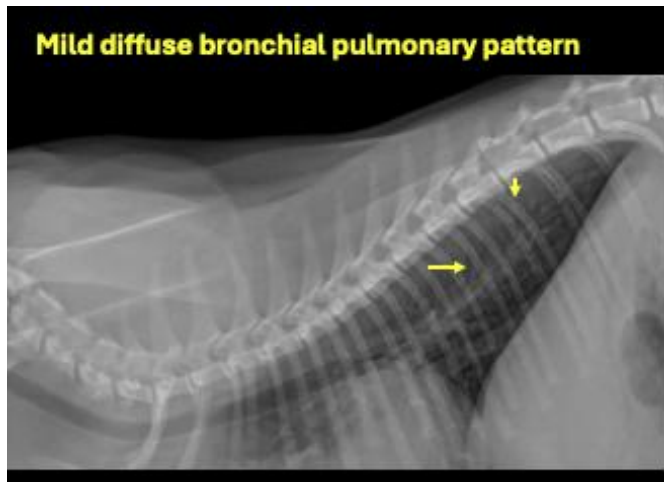
Dr. Stefanie Simon

INVOICE

74518

DATE

4-8-26



The information and recommendations provided are based on the images presented by the referring veterinarian. No evaluation can be communicated regarding pathology that was not visible in the image/video clips provided.

Thank you for this referral. If the clinical or image interpretation does not parallel your findings or if I can be of any further assistance, please contact me.

Tilde Rodrigues Froes, DMV, MSc., Dr. Med.Vet., Dipl.CBraRVet
info@sonopath.com