



PATIENT PRESENTING CLINICAL SIGNS

Peanut Shuttleworth

Started coughing over the weekend. Was placed on Doxycycline and Hycodan. Coughing has somewhat improved, but not resolved. X-rays performed today (4/6/23). Had off on diarrhea. O has noticed spitting up with foam. Temperature was normal at 102.4. The concern on radiographs is there might be a nodule in the lower right lung lobe. The pyloric outlet seems very prominent, especially on the left lateral view.

SPECIES

Canine

Abnormal PE/Chem/CBC/UA Results: CBC showed some dehydration.

RADIOGRAPHIC STUDY OF THE THORAX

BREED

Royal Potcake

Orthogonal views of the thorax are provided for review totaling five images. Three ventrodorsal views, one right lateral view, and one left lateral view.

RADIOGRAPHIC FINDINGS

SEX

The thoracic trachea is normal.

FS

A moderate diffuse bronchial pattern and unstructured interstitial pulmonary pattern is seen, as well as areas of more coalescent interstitial appearance. Also, a mild patchy alveolar pattern is seen in the cranial subsegment of the left cranial lung lobe.

AGE

5

The cardiac silhouette and pulmonary vasculature are normal. (VHS = 10.1)

The mediastinum and pleural space are normal.

INTERPRETED BY

Tilde Rodrigues Froes, DMV, MSc., Dr. Med Vet., Dipl. CBraRVet

The stomach is moderately distended, contains a moderate amount of gas and heterogeneous soft tissue ingesta, which redistributes with the patient's position. The antrum-pyloric region contains variable gas content and no abnormal distention. No evidence of radiopaque foreign material.

The duodenum is variably dilated with gas between the views.

RADIOGRAPHIC DIAGNOSIS

HOSPITAL NAME

Pet Med Plus

- Moderate generalized bronchial, interstitial pattern with tree-in-bud appearance. Differential diagnosis includes allergic lower airway disease, chronic bronchitis, eosinophilic bronchitis, infectious bronchitis, a concurrent focal pneumonia, or pulmonary atelectasis in the cranial lung lobe.

REFERRING VET

Dr. Donita McElroy

- Normal heart.
- Moderate distended duodenum and stomach, aerophagy, or gastrointestinal ileus, no evidence of mechanical gastrointestinal obstruction or radiopaque foreign material.

INTERPRETATION OF THE FINDINGS & FURTHER RECOMMENDATIONS

INVOICE

57669

The detected pulmonary changes are correlated with the clinical respiratory signs. Because of the coalescent interstitial appearance of some areas and peribronchial pattern (tree in bud appearance) and the summation artifact that is correlated to the caudal vena cava and adjacent vessels, a mimicking image of the pulmonary soft tissue nodule is identified as described in the patient history.

DATE

4-6-23



PATIENT

Continuing medical therapy is suggested. If the patient does not improve, a bronchoalveolar lavage may be useful in obtaining samples for cytology, culture, and sensitivity.

Peanut Shuttleworth

SPECIES

Canine

BREED

Royal Potcake

SEX

FS

AGE

5

INTERPRETED BY

Tilde Rodrigues Froes,
DMV, MSc., Dr. Med
Vet., Dipl. CBraRVet

HOSPITAL NAME

Pet Med Plus

REFERRING VET

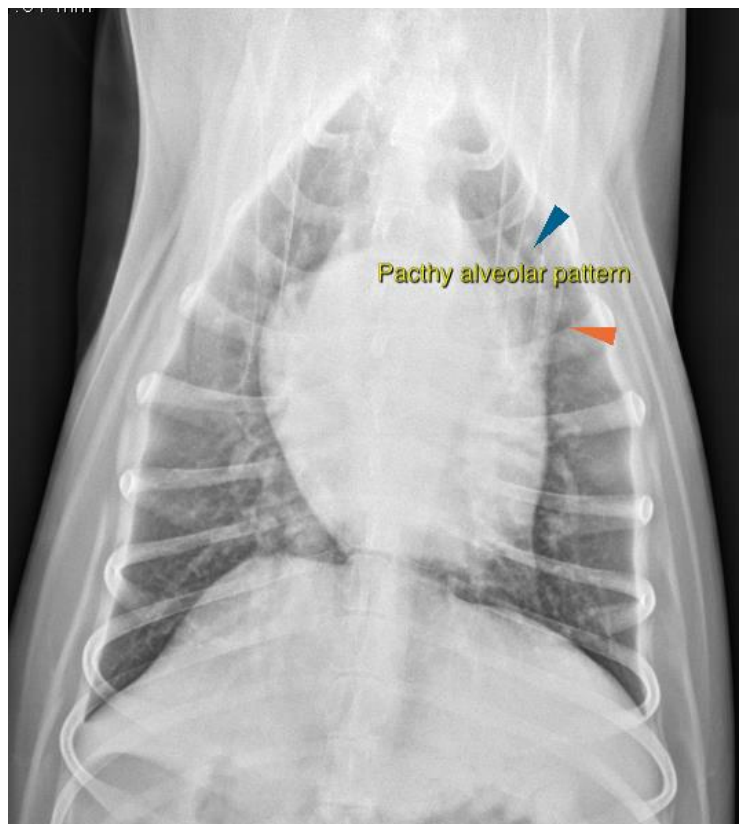
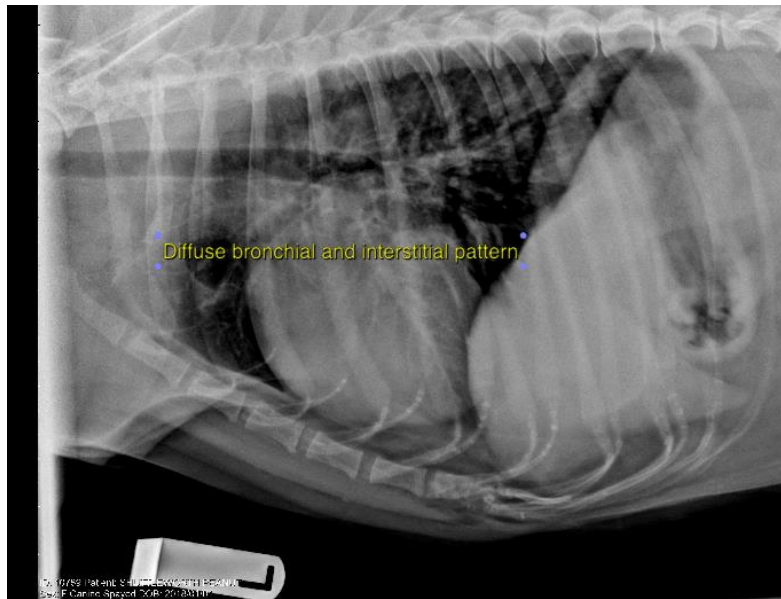
Dr. Donita McElroy

INVOICE

57669

DATE

4-6-23





PATIENT

Peanut Shuttleworth

SPECIES

Canine

BREED

Royal Potcake

SEX

FS

AGE

5

INTERPRETED BY

Tilde Rodrigues Froes,
DMV, MSc., Dr. Med
Vet., Dipl. CBraRVet

HOSPITAL NAME

Pet Med Plus

REFERRING VET

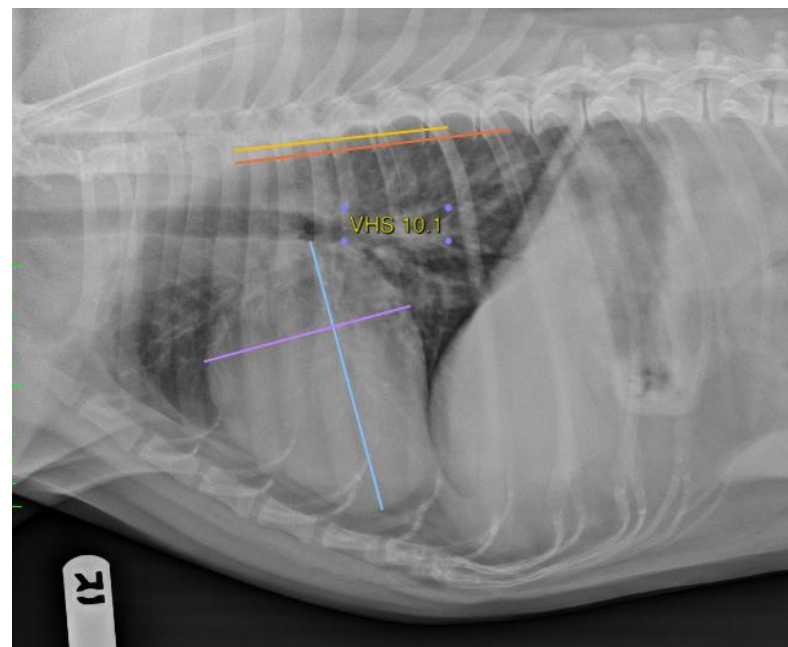
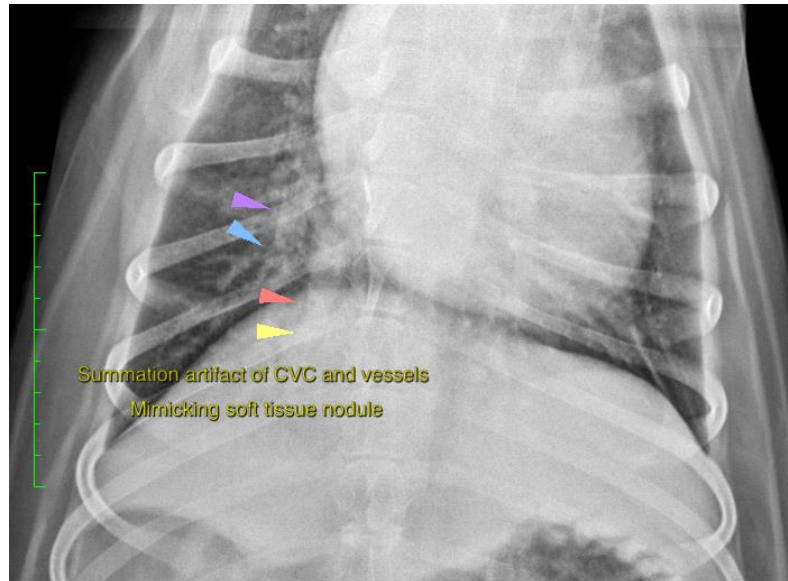
Dr. Donita McElroy

INVOICE

57669

DATE

4-6-23





PATIENT

Peanut Shuttleworth

The information and recommendations provided are based on the images presented by the referring veterinarian. No evaluation can be communicated regarding pathology that was not visible in the image/video clips provided.

SPECIES

Canine

Thank you for this referral. If the clinical or image interpretation does not parallel your findings or if I can be of any further assistance please contact me.

Tilde Rodrigues Froes, DMV, MSc., Dr. Med.Vet., Dipl.CBraRVet
info@sonopath.com

BREED

Royal Potcake

SEX

FS

AGE

5

INTERPRETED BY

Tilde Rodrigues Froes,
DMV, MSc., Dr. Med
Vet., Dipl. CBraRVet

HOSPITAL NAME

Pet Med Plus

REFERRING VET

Dr. Donita McElroy

INVOICE

57669

DATE

4-6-23