



PATIENT PRESENTING CLINICAL SIGNS

Fluffy Mackie present for recurrent ear infections post cat boarding - commenced dec22 - non responsive to topicals
Abnormal PE/Chem/CBC/UA Results: chem/t4/cbc pending

SPECIES COMPUTED TOMOGRAPHIC STUDY OF THE HEAD AND CERVICAL SOFT TISSUE

Feline A high-resolution pre- and post-contrast CT study of the head and cervical soft tissue are provided for review.

BREED COMPUTED TOMOGRAPHIC FINDINGS

Maine Coon The left tympanic bulla is entirely filled with a predominantly hypoattenuating fluid material; however, a periphery of mixed soft tissue attenuation and enhancement is also seen. There is also an expansile appearance and mild hyperostosis; however, there is no evidence of osteolytic changes. Also, the proximal portion of the horizontal auditory canal is filled with hypoattenuating fluid material.

SEX

Female The right tympanic bulla is partially filled with a hypoattenuating fluid material; there is no evidence of an expansile appearance, hyperostosis, or osteolytic changes. The right-side auditory canal is air-filled and normal.

AGE

8 No evidence of sclerosis of the petrous part of the temporal bone and no signs of meningeal enhancement are seen.

INTERPRETED BY

Tilde Rodrigues Froes, DMV, MSc., Dr. Med Vet., Dipl. CBraRVet

Mild hypoattenuating fluid accumulation material within the right nasal cavity is noted, however, no evidence of turbinate destruction or asymmetry is seen. The left nasal cavity is normal. The sphenoidal and frontal sinuses are normal.

The nasopharynx and choana are normal.

The hyoid apparatus is normal.

HOSPITAL NAME

Advanced Veterinary Imaging

The retrobulbar spaces are normal.

The cribriform plate is normal.

Other osseous structures of the calvarium are normal.

REFERRING VET

Eamon

The triadans 101 and 201 are absent.

The left retropharyngeal lymph node is moderately enlarged and mildly heterogeneous. LRFL measures approximately 0.86cm thickened. The left retropharyngeal lymph node is normal in size. LRLF measures approximately 0.37cm thickened. The mandibular lymph nodes are unremarkable.

INVOICE

57633

Multifocal spondylosis deformans is seen in the thoracic spine.

On the edge of the exam, bilateral periarticular ossification of the elbow joints is seen (> left).

DATE

4-5-23

Otherwise, the collimated thorax is normal.



PATIENT

Fluffy Mackie

COMPUTED TOMOGRAPHIC DIAGNOSIS

- Bilateral chronic otitis media (> left side). Because of the peripheral enhancement and expansile lesion on the left side, a tympanokeratoma is included in the differential diagnosis.
- Left side retropharyngeal lymphadenitis, reactive.
- Mild fluid accumulation within the right nasal cavity, mild nondestructive rhinitis.
- Absence of the triadans 101 and 201.
- Multifocal thoracic spondylosis deformans.
- Bilateral elbow osteoarthritis.

SPECIES

Feline

BREED

Maine Coon

SEX

Female

AGE

8

INTERPRETATION OF THE FINDINGS & FURTHER RECOMMENDATIONS

The tomographic findings of bullae indicate otitis media, and the causes could be allergic, bacterial, or fungal. The tomographic exam has low sensitivity to determine if the tympanic membrane is intact or not. Consider correlation with the otoscopy exam. The peripheral enhancement in the left bulla could just be correlated to inflammation, no clear mass effect is seen; however, a small tympanokeratoma is not completely excluded. A cytology exam and culture are also suggested to better guide the next therapeutic approach.

Correlate the oral/dental finding with a dental exam.

INTERPRETED BY

Tilde Rodrigues Froes, DMV, MSc., Dr. Med Vet., Dipl. CBraRVet

HOSPITAL NAME

Advanced Veterinary Imaging

REFERRING VET

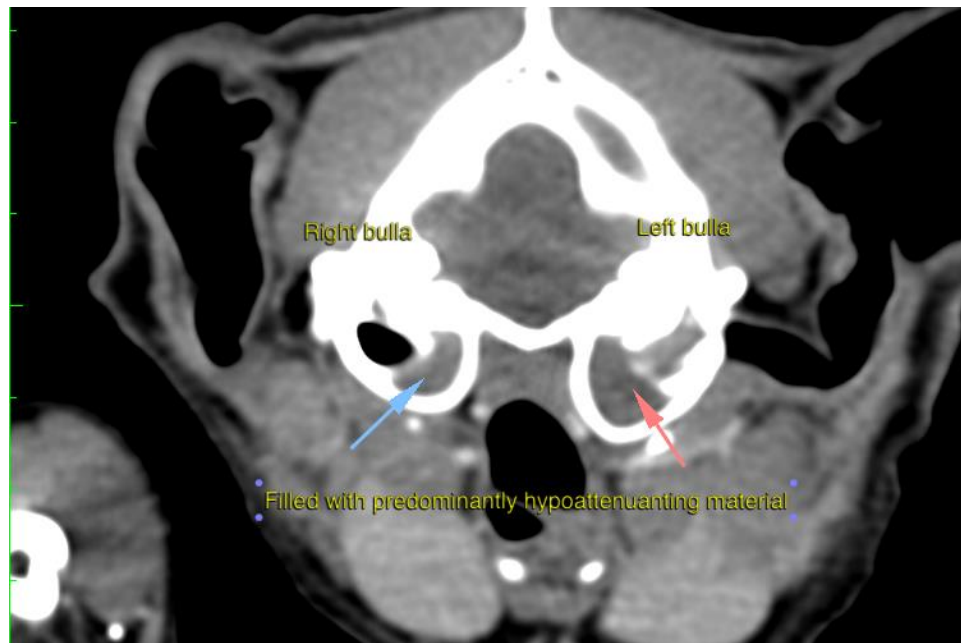
Eamon

INVOICE

57633

DATE

4-5-23





PATIENT

Fluffy Mackie

SPECIES

Feline

BREED

Maine Coon

SEX

Female

AGE

8

INTERPRETED BY

Tilde Rodrigues Froes,
DMV, MSc., Dr. Med
Vet., Dipl. CBraRVet

HOSPITAL NAME

Advanced Veterinary
Imaging

REFERRING VET

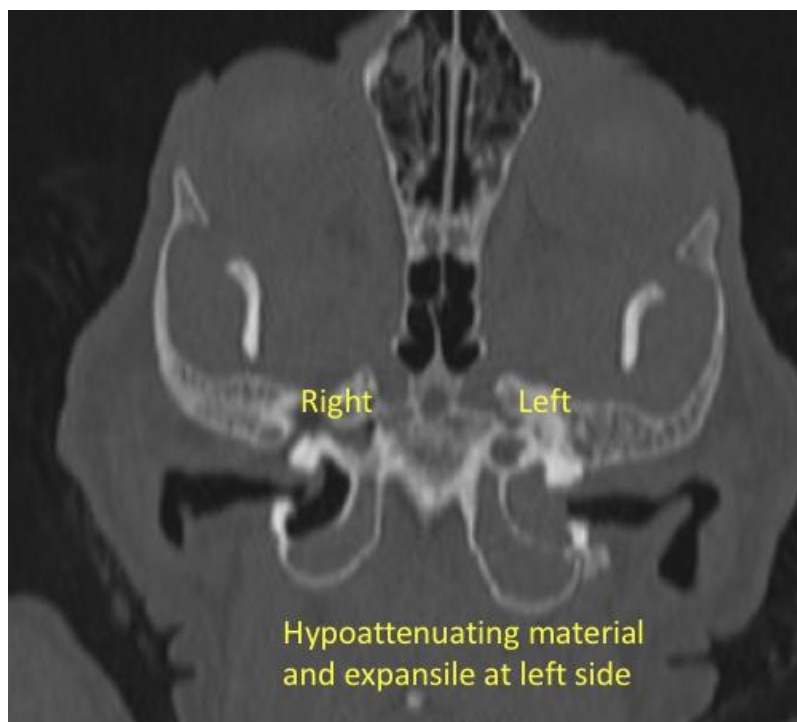
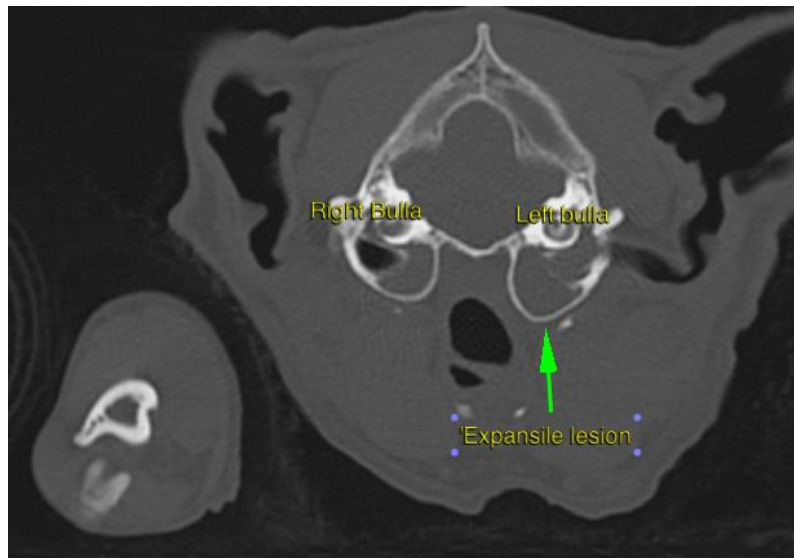
Eamon

INVOICE

57633

DATE

4-5-23





PATIENT

Fluffy Mackie

SPECIES

Feline

BREED

Maine Coon

SEX

Female

AGE

8

INTERPRETED BY

Tilde Rodrigues Froes,
DMV, MSc., Dr. Med
Vet., Dipl. CBraRVet

HOSPITAL NAME

Advanced Veterinary
Imaging

REFERRING VET

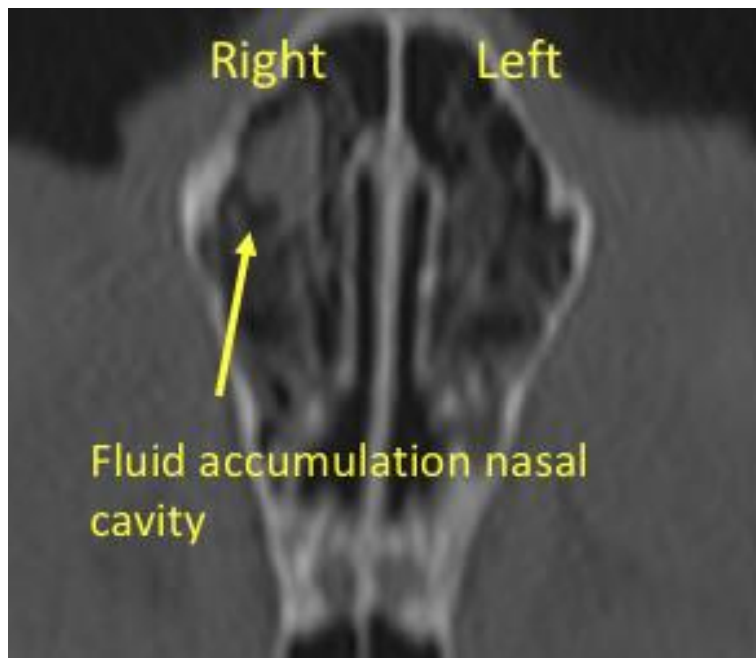
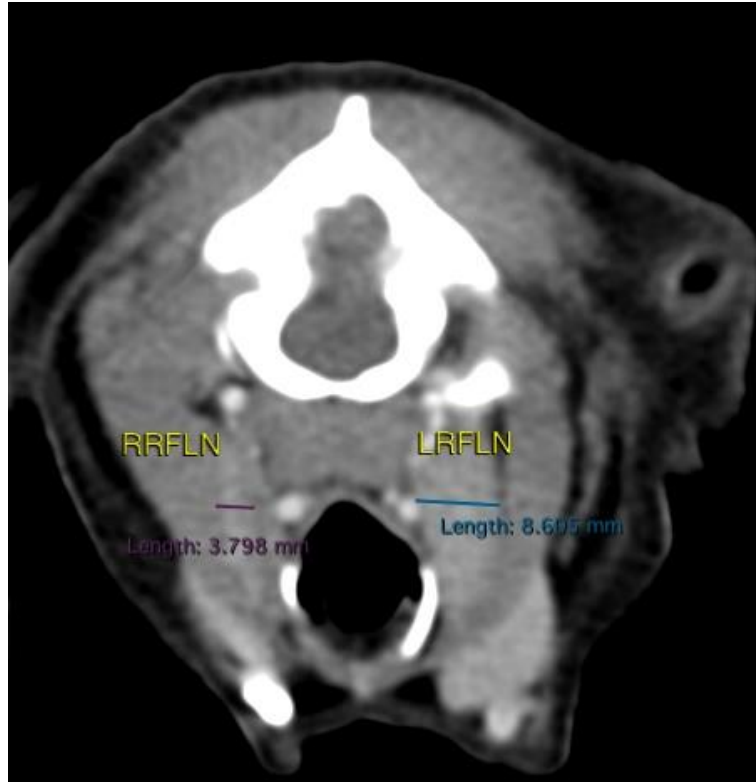
Eamon

INVOICE

57633

DATE

4-5-23





PATIENT

Fluffy Mackie

The information and recommendations provided are based on the images presented by the referring veterinarian. No evaluation can be communicated regarding pathology that was not visible in the image/video clips provided.

SPECIES

Feline

Thank you for this referral. If the clinical or image interpretation does not parallel your findings or if I can be of any further assistance please contact me.

BREED

Maine Coon

Tilde Rodrigues Froes, DMV, MSc., Dr. Med.Vet., Dipl.CBraRVet
info@sonopath.com

SEX

Female

AGE

8

INTERPRETED BY

Tilde Rodrigues Froes,
DMV, MSc., Dr. Med
Vet., Dipl. CBraRVet

HOSPITAL NAME

Advanced Veterinary
Imaging

REFERRING VET

Eamon

INVOICE

57633

DATE

4-5-23