



## PATIENT

Kobe Torres

## SPECIES

Canine

## BREED

Bichon

## SEX

M

## AGE

11

## WEIGHT

24

## INTERPRETED BY

Tilde Rodrigues Froes,  
DMV, MSc., Dr. Med  
Vet., Dipl. CBraRVet

## IMAGING PERFORMED BY

JD Veterinary Imaging  
Center

## HOSPITAL NAME

Juana Diaz Animal  
Hospital

## REFERRING VET

Dr Jose Rivera Torres

## INVOICE

74837

## DATE

4-30-26

## PRESENTING CLINICAL SIGNS

acute onset of rear paralysis, deep pain still present.

## COMPUTED TOMOGRAPHIC STUDY OF THE SPINE

A non-contrast CT study of the thoracic and lumbar spine was provided for review, comprising six series. Images were acquired in transverse plane using bone and soft tissue algorithms, extending from the level of T7.

## COMPUTED TOMOGRAPHIC FINDINGS

### THORACIC AND LUMBAR SPINE

The vertebral column alignment. Vertebral bodies are normal in size, shape, and attenuation.

Normal lumbar vertebral count is identified (L1–L7). The sacrum is unremarkable.

At the T13–L1 intervertebral space, there is a moderate volume of mixed-attenuation extradural material containing mineralized foci, located along the ventral and left lateral aspect of the vertebral canal. This material is also displaced cranially, occupies approximately 30% of the vertebral canal diameter, and results in moderate spinal cord compression.

At T11–T12, L4–L5, and L6–L7, small volumes of mineral-attenuating extradural material are present along the ventral vertebral canal, without significant spinal cord compression.

At L7–S1, a small volume of mineral-attenuating extradural material is identified ventrally, with slight extension toward the right neurovascular foramen, suggesting possible mild nerve root impingement.

Multifocal in situ mineralization of intervertebral discs is noted throughout the thoracolumbar and lumbar spine.

The paraspinal soft tissues are otherwise symmetric and within normal limits.

Few small soft tissue attenuating nodules are identified within the dorsal cutaneous and subcutaneous tissues, dispersed, compatible with cutaneous/subcutaneous micronodules.

## COMPUTED TOMOGRAPHIC DIAGNOSIS

- Moderate extradural lesion at T13–L1 (ventral-left side), most consistent with intervertebral disc herniation, resulting in moderate spinal cord compression.
- Additional multifocal small foci of disc herniations are identified within T11–T12, L4–L5, and L6–L7, without or minimally spinal cord compressions.
- L7–S1 mild disc herniation with possible right-sided nerve root impingement.
- Multifocal intervertebral disc in-situ nuclear mineralization, consistent with degenerative chondroid disease.
- Marked urinary bladder distension, which may be secondary to neurogenic dysfunction.
- Few small cutaneous/subcutaneous nodules along the dorsal region, nonspecific (e.g., sebaceous cysts, follicular lesions, or other benign cutaneous nodules).



**PATIENT**

Kobe Torres

**SPECIES**

Canine

**BREED**

Bichon

**SEX**

M

**AGE**

11

**WEIGHT**

24

**INTERPRETED BY**

Tilde Rodrigues Froes,  
DMV, MSc., Dr. Med  
Vet., Dipl. CBraRVet

**IMAGING  
PERFORMED BY**

JD Veterinary Imaging  
Center

**HOSPITAL NAME**

Juana Diaz Animal  
Hospital

**REFERRING VET**

Dr Jose Rivera Torres

**INVOICE**

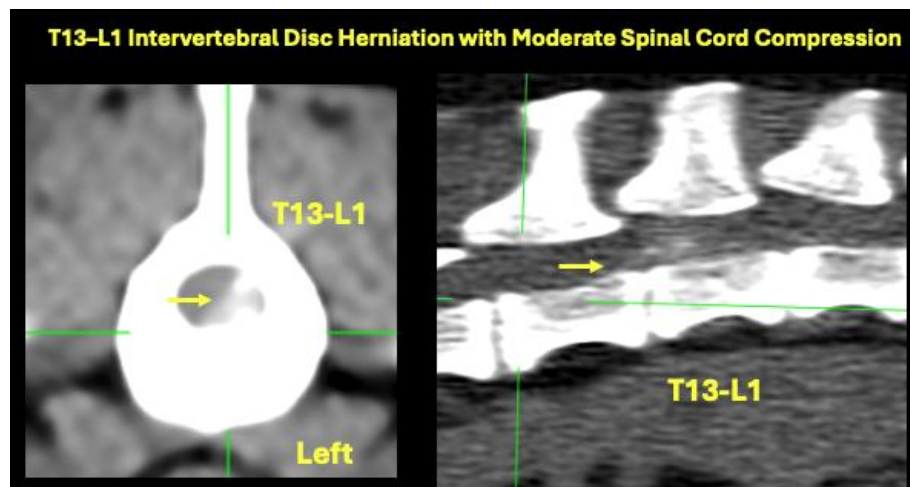
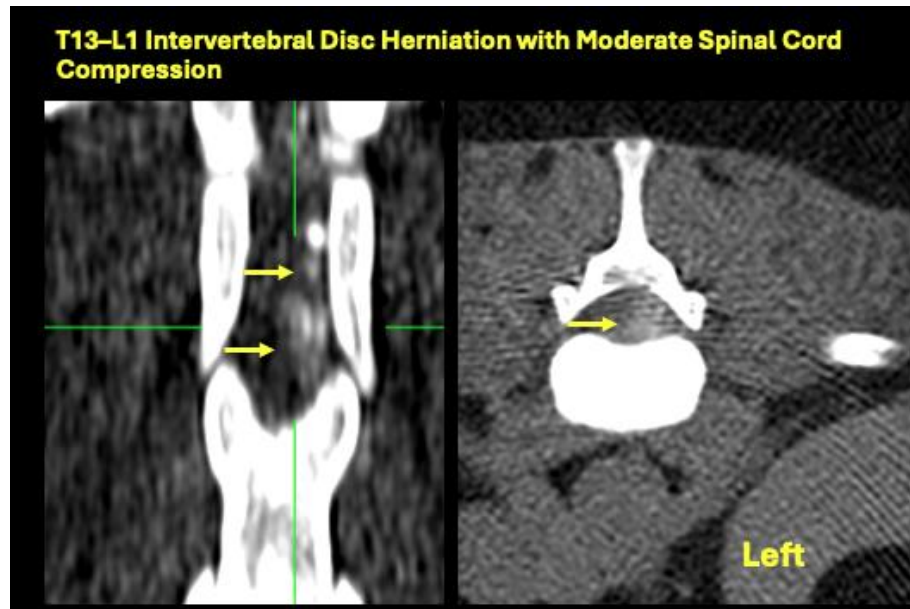
74837

**DATE**

4-30-26

**INTERPRETATION OF THE FINDINGS & FURTHER RECOMMENDATIONS**

The CT findings demonstrate multifocal intervertebral disc herniations of variable volume and attenuation characteristics. The most clinically significant lesion is at T13-L1, intervertebral disc herniation causing moderate spinal cord compression. Correlate these findings with the neurological exam. Surgical decompression should be considered.





## PATIENT

Kobe Torres

## SPECIES

Canine

## BREED

Bichon

## SEX

M

## AGE

11

## WEIGHT

24

## INTERPRETED BY

Tilde Rodrigues Froes,  
DMV, MSc., Dr. Med  
Vet., Dipl. CBraRVet

## IMAGING PERFORMED BY

JD Veterinary Imaging  
Center

## HOSPITAL NAME

Juana Diaz Animal  
Hospital

## REFERRING VET

Dr Jose Rivera Torres

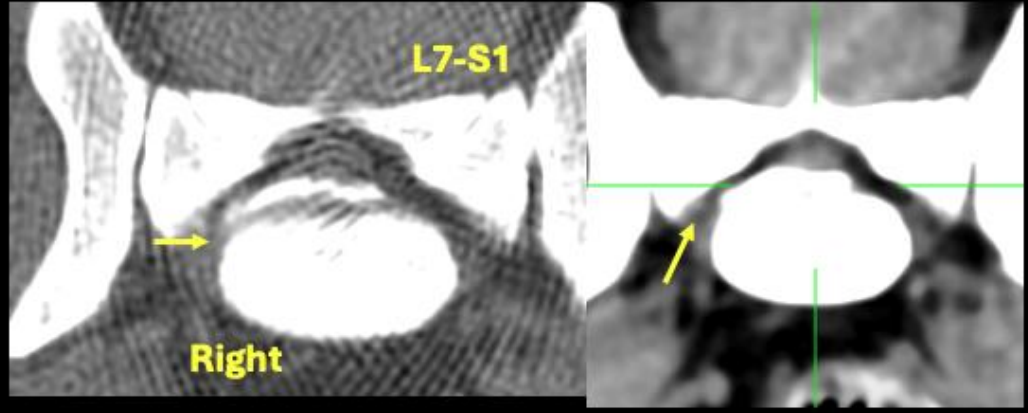
## INVOICE

74837

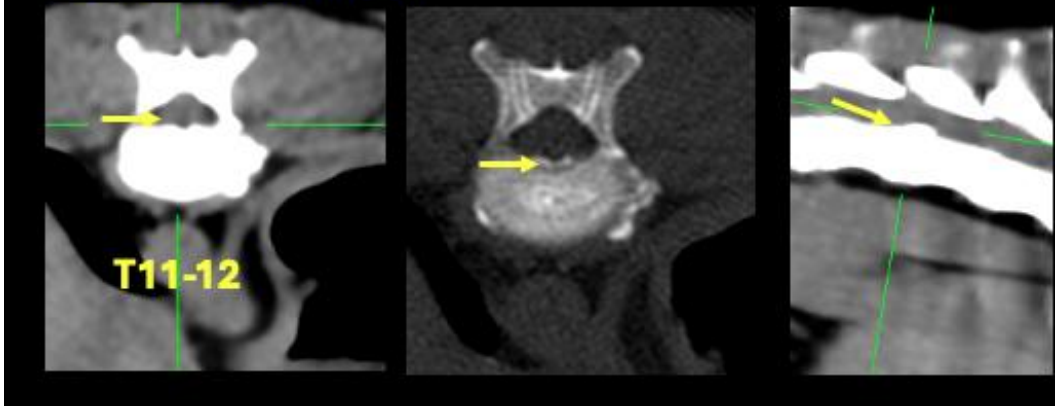
## DATE

4-30-26

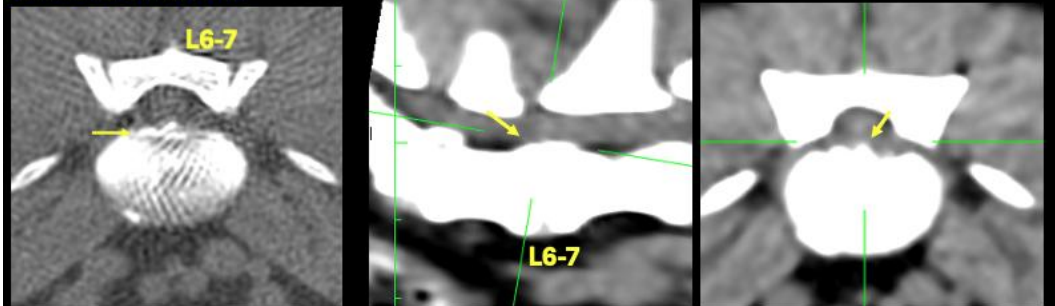
### L7-S1 mild disc herniation with possible right-sided nerve root impingement.



### Mild Intervertebral Disc Herniations at T11-12, minimal or without spinal cord compression



### Mild Intervertebral Disc Herniations at L6-7, minimal or without spinal cord compression





## PATIENT

Kobe Torres

## SPECIES

Canine

## BREED

Bichon

## SEX

M

## AGE

11

## WEIGHT

24

## INTERPRETED BY

Tilde Rodrigues Froes,  
DMV, MSc., Dr. Med  
Vet., Dipl. CBraRVet

## IMAGING PERFORMED BY

JD Veterinary Imaging  
Center

## HOSPITAL NAME

Juana Diaz Animal  
Hospital

## REFERRING VET

Dr Jose Rivera Torres

## INVOICE

74837

## DATE

4-30-26

The information and recommendations provided are based on the images presented by the referring veterinarian. No evaluation can be communicated regarding pathology that was not visible in the image/video clips provided.

Thank you for this referral. If the clinical or image interpretation does not parallel your findings or if I can be of any further assistance, please contact me.

**Tilde Rodrigues Froes, DMV, MSc., Dr. Med.Vet., Dipl.CBraRVet**  
[info@sonopath.com](mailto:info@sonopath.com)