



PATIENT PRESENTING CLINICAL SIGNS

Shia B Castillo Obesity and evaluation of hip.

RADIOGRAPHIC STUDY OF PELVIC LIMBS

SPECIES

Canine

Orthogonal views of the pelvic limbs are provided for review totaling 3 images. Two lateral views and one ventrodorsal view of the pelvis and pelvic limbs.

RADIOGRAPHIC FINDINGS

BREED

Chihuahua

There is an incongruency in the right coxofemoral joint, with approximately 40% coverage of the femoral head by the respective dorsal acetabular margin.

The left coxofemoral joint is congruent.

SEX

Female Spayed

The stifle joints and fat-pad opacities are normal, however a position artifactual of the patellae are seen in the craniocaudal view.

The tarsocrural and tarsal joints are normal.

No aggressive, acute traumatic, chronic degenerative osseous abnormalities.

AGE

1 Year

No soft tissue swelling, or discrepancies in the volume of the pelvic muscle mass.

The collimated lumbar and lumbosacral spine are normal.

The collimated caudal abdomen is normal.

INTERPRETED BY

Tilde Rodrigues Froes, DMV, MSc., Dr. Med Vet., Dipl. CBraRVet

Abundant fat stores are seen in the subcutaneous tissues.

RADIOGRAPHIC DIAGNOSIS

- Right side incongruency of the coxofemoral joint, without secondary degenerative changes.
- Excessive body condition score.

HOSPITAL NAME

Paseos Veterinary Center

INTERPRETATION OF THE FINDINGS & FURTHER RECOMMENDATIONS

Correlate the signs of the right coxofemoral incongruency with the orthopedical clinical signs. There is no evident asymmetry between the muscular mass volumes in the pelvic limbs. There is no evidence of an aggressive osseous lesion.

REFERRING VET

Dr. F. Ortiz

INVOICE

58010

DATE

4-27-23



PATIENT

Shia B Castillo

SPECIES

Canine

BREED

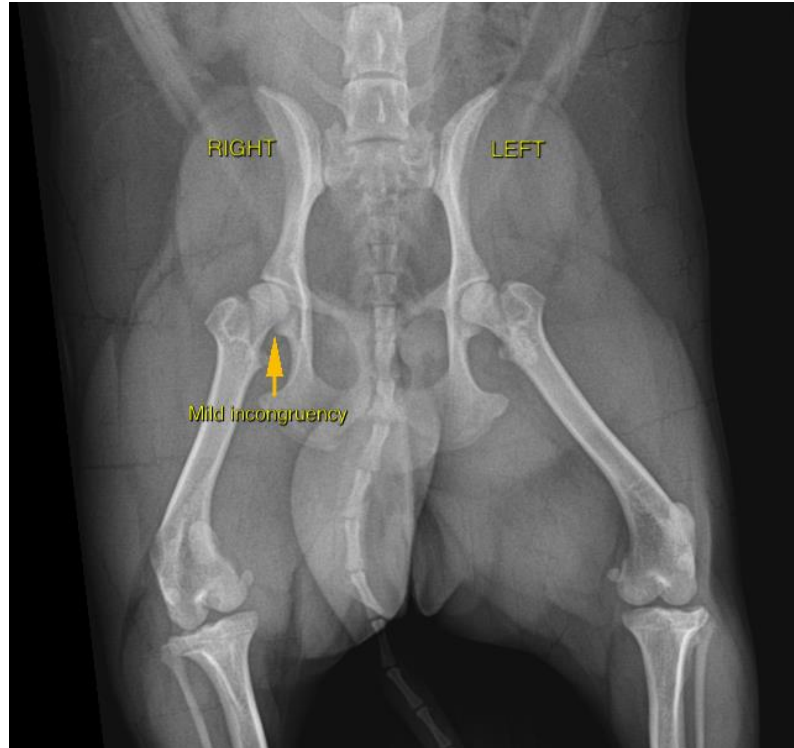
Chihuahua

SEX

Female Spayed

AGE

1 Year



INTERPRETED BY

Tilde Rodrigues Froes,
DMV, MSc., Dr. Med
Vet., Dipl. CBraRVet

HOSPITAL NAME

Paseos Veterinary
Center

REFERRING VET

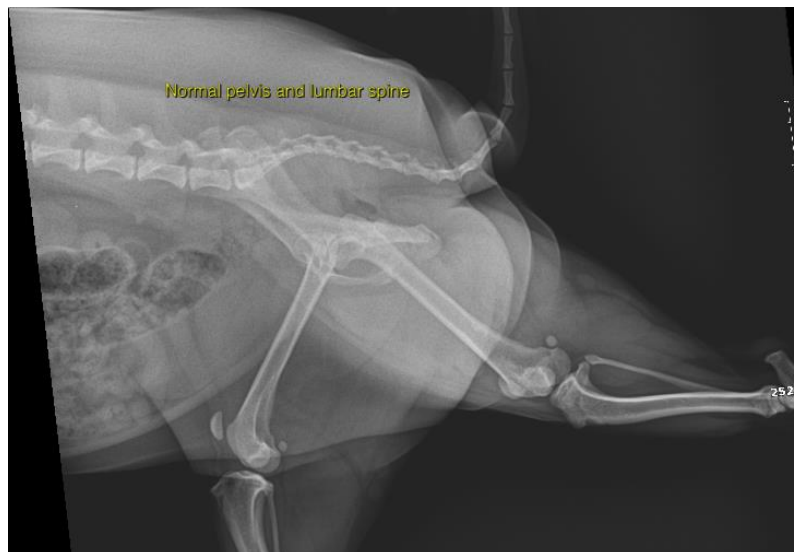
Dr. F. Ortiz

INVOICE

58010

DATE

4-27-23





PATIENT

Shia B Castillo

The information and recommendations provided are based on the images presented by the referring veterinarian. No evaluation can be communicated regarding pathology that was not visible in the image/video clips provided.

SPECIES

Canine

Thank you for this referral. If the clinical or image interpretation does not parallel your findings or if I can be of any further assistance please contact me.

Tilde Rodrigues Froes, DMV, MSc., Dr. Med.Vet., Dipl.CBraRVet
info@sonopath.com

BREED

Chihuahua

SEX

Female Spayed

AGE

1 Year

INTERPRETED BY

Tilde Rodrigues Froes,
DMV, MSc., Dr. Med
Vet., Dipl. CBraRVet

HOSPITAL NAME

Paseos Veterinary
Center

REFERRING VET

Dr. F. Ortiz

INVOICE

58010

DATE

4-27-23