



PATIENT PRESENTING CLINICAL SIGNS

Chiqui Lopez Chronic nasal congestion

COMPUTED TOMOGRAPHIC STUDY OF THE HEAD

SPECIES A pre- and post-contrast CT study of the head is provided for review. One head series pre-contrast and one post-contrast.

Canine

COMPUTED TOMOGRAPHIC FINDINGS

BREED There is diffuse mucosal thickening of the nasal turbinates within the nasal cavities. Mild to moderate loss of turbinate architecture is seen bilaterally and asymmetrically. Associated multifocal hypoattenuating fluid material accumulation is seen, more on the right side. No mass effect is seen.

Chihuahua

SEX

There is mild hypoattenuating fluid material within the choana.

Spayed Female

The choana, nasopharynx and larynx are normal.

The cribriform plate is intact.

AGE

There is no evidence of hyperostosis or osteolytic lesions of the adjacent bones.

9 Years

The frontal sinuses are filled partially or completely by hypoattenuating fluid material, more right side.

INTERPRETED BY

The pharynx and larynx are normal.

Tilde Rodrigues Froes, DMV, MSc., Dr. Med Vet., Dipl. CBraRVet

All teeth are present. Focal maxillary alveolar bone disease is seen adjacent to the triadan 104 and an oronasal communication is seen. There is mild horizontal and vertical bone loss along the teeth.

The tympanic bullae and auditory external canals are normal.

HOSPITAL NAME

The retrobulbar spaces and globes are intact.

Mobile Pet Imaging

The temporomandibular joints are bilaterally congruent.

REFERRING VET

The brain attenuation is unremarkable, no mass effect is seen.

Meaux

The medial retropharyngeal and mandibular lymph nodes are unremarkable.

COMPUTED TOMOGRAPHIC DIAGNOSIS

INVOICE

57999

- Mild to moderate bilaterally destructive rhinitis and moderate multifocal nasal fluid accumulation. The lesions are more prominent on the right.
- Mild to moderate periodontal disease, focal tooth root reabsorption at the triadan 104 with focal small oronasal communication.
- Concurrent sinusitis, bilateral.

DATE

4-26-23



PATIENT INTERPRETATION OF THE FINDINGS & FURTHER RECOMMENDATIONS

Chiqui Lopez The differential diagnosis for the mild to moderate destructive rhinitis includes bacterial, viral, and lymphocytic plasmocytic. Early infectious fungal disease cannot be ruled out. An association of the nasal flush biopsy is suggested.

SPECIES Canine Mild periodontal disease and tooth reabsorption at triadan 104 is seen. A correlation with periodontal disease and infectious rhinitis could occur. A dental exam, with confirmed oronasal communication, and an odontology treatment is suggested in association with rhinitis treatment.

BREED

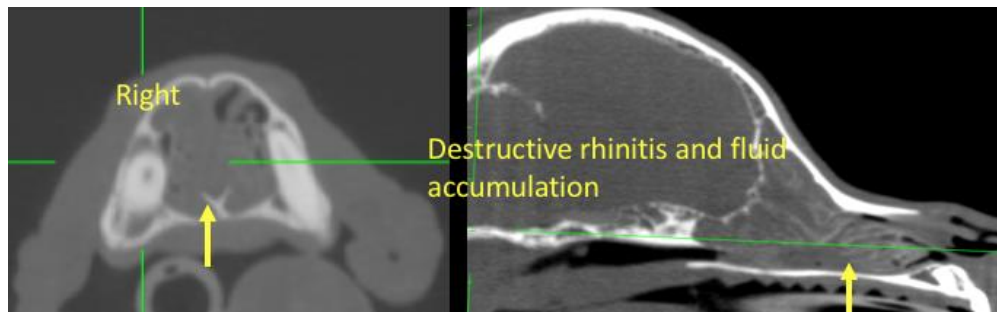
Chihuahua

SEX

Spayed Female

AGE

9 Years



INTERPRETED BY

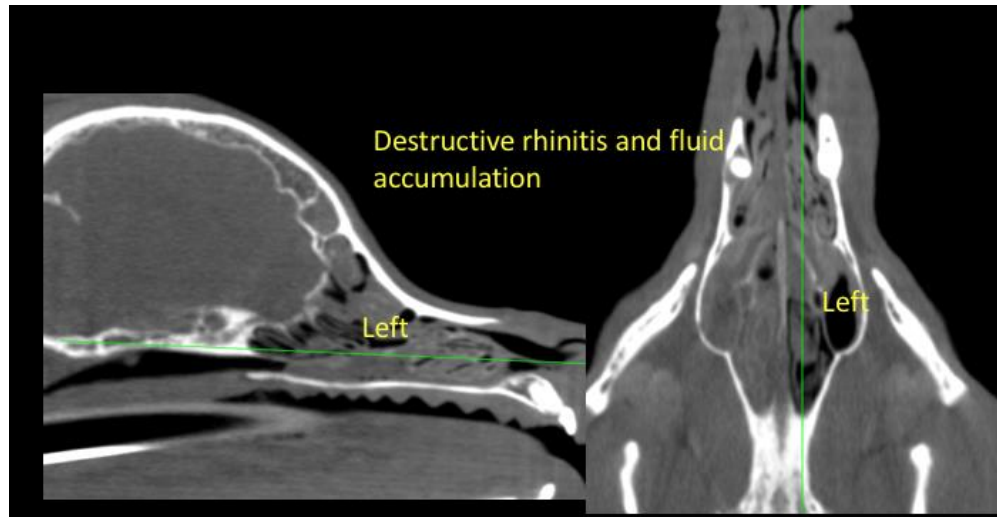
Tilde Rodrigues Froes, DMV, MSc., Dr. Med Vet., Dipl. CBraRVet

HOSPITAL NAME

Mobile Pet Imaging

REFERRING VET

Meaux



INVOICE

57999

DATE

4-26-23



PATIENT

Chiqui Lopez

SPECIES

Canine

BREED

Chihuahua

SEX

Spayed Female

AGE

9 Years

The information and recommendations provided are based on the images presented by the referring veterinarian. No evaluation can be communicated regarding pathology that was not visible in the image/video clips provided.

INTERPRETED BY

Tilde Rodrigues Froes,
DMV, MSc., Dr. Med
Vet., Dipl. CBraRVet

Thank you for this referral. If the clinical or image interpretation does not parallel your findings or if I can be of any further assistance please contact me.

Tilde Rodrigues Froes, DMV, MSc., Dr. Med.Vet., Dipl.CBraRVet
info@sonopath.com

HOSPITAL NAME

Mobile Pet Imaging

REFERRING VET

Meaux

INVOICE

57999

DATE

4-26-23

