



PATIENT

Radar Brock

SPECIES

Canine

BREED

Australian Shepherd
Mix

SEX

MN

AGE

10Y

WEIGHT

57lbs

INTERPRETED BY

Tilde Rodrigues Froes,
DMV, MSc., Dr. Med
Vet., Dipl. CBraRVet

IMAGING PERFORMED BY

Kaila Wojkiewicz

HOSPITAL NAME

Animal Health Care
Denver

REFERRING VET

Cathryn Sayer

INVOICE

74760

DATE

4-22-26

PRESENTING CLINICAL SIGNS

Mass suddenly noted on hard palate, no symptoms
Abnormal PE/Chem/CBC/UA Results: Normal BW

COMPUTED TOMOGRAPHIC STUDY OF THE HEAD

A pre- and post-contrast CT study of the head are provided for review totaling 2 series. One pre-contrast series of the head bone algorithm. One post-contrast series of the head, bone algorithm.

COMPUTED TOMOGRAPHIC FINDINGS

A large, broad-based, elongated soft tissue mass is identified within the caudal hard palate, predominantly on the left side, at the level of the absent Triadan 208-209 teeth. The lesion demonstrates mild contrast enhancement and measures approximately 2.1 × 2.1 × 1.9 cm.

There is focal thinning of the adjacent hard palate bone contiguous with the mass. However, no overt aggressive osseous destruction is identified.

The left medial retropharyngeal lymph node is subjectively enlarged compared to the contralateral side.

The mandibular lymph nodes are unremarkable.

The following teeth are absent: Triadan 108, 109, 110, 208, 209, and 210.

The nasal cavities and turbinates are within normal limits.

The cribriform plate is intact.

The oropharynx and nasopharynx are within normal limits.

The frontal sinuses are unremarkable.

No evidence of intracranial mass effect.

The tympanic cavities and external auditory canals are within normal limits.

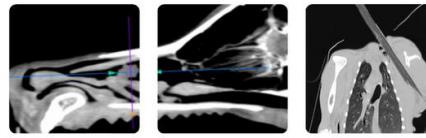
The globes and retrobulbar spaces are within normal limits.

The temporomandibular joints are bilaterally congruent.

The mandibular, parotid and zygomatic salivary glands are unremarkable.

COMPUTED TOMOGRAPHIC DIAGNOSIS

- A large, elongated, broad-based, mild contrast-enhancing soft tissue mass affecting the caudal hard palate, predominantly on the left side, associated with adjacent bone thinning. Differential diagnoses include oral neoplasia, less likely benign proliferative lesion
- Mild enlargement of the left medial retropharyngeal lymph node, which may represent reactive lymphadenitis or possible metastatic involvement.
- Multiple missing teeth (Triadan 108, 109, 110, 208, 209, 210).



PATIENT

Radar Brock

SPECIES

Canine

BREED

Australian Shepherd
Mix

SEX

MN

AGE

10Y

WEIGHT

57lbs

INTERPRETED BY

Tilde Rodrigues Froes,
DMV, MSc., Dr. Med
Vet., Dipl. CBraRVet

**IMAGING
PERFORMED BY**

Kaila Wojkiewicz

HOSPITAL NAME

Animal Health Care
Denver

REFERRING VET

Cathryn Sayer

INVOICE

74760

DATE

4-22-26

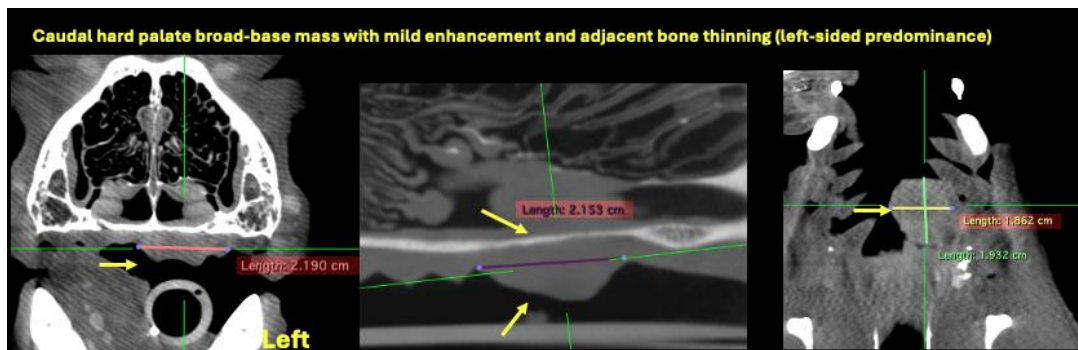
INTERPRETATION OF THE FINDINGS & FURTHER RECOMMENDATIONS

The CT findings demonstrate a broad-based, space-occupying lesion within the caudal hard palate, exhibiting mild contrast enhancement and associated focal bone thinning. Although there is no evidence of marked aggressive osteolysis, the broad-based nature of the mass makes precise delineation of its margins challenging. Differential diagnoses include oral neoplasia (e.g., malignant melanoma, squamous cell carcinoma, fibrosarcoma), with a benign proliferative lesion considered less likely.

Mild enlargement of the left medial retropharyngeal lymph node raises concern for reactive lymphadenitis or early metastatic involvement.

Cytological and/or histopathological confirmation is required for a definitive diagnosis. An incisional biopsy of the lesion is also suggested.

Further staging, including thoracic imaging, is recommended if a malignant process is confirmed.



The information and recommendations provided are based on the images presented by the referring veterinarian. No evaluation can be communicated regarding pathology that was not visible in the image/video clips provided.

Thank you for this referral. If the clinical or image interpretation does not parallel your findings or if I can be of any further assistance, please contact me.

Tilde Rodrigues Froes, DMV, MSc., Dr. Med.Vet., Dipl.CBraRVet
info@sonopath.com