



PATIENT PRESENTING CLINICAL SIGNS

Josie Bryant Initial episode of suspect kennel cough in Dec 2022; responded well to Doxycycline and Temaril-P. Recurrence in March 2023; responded well to short-course Pred and Doxy. Symptoms have returned recently. Dog is happy/healthy, crazy puppy! Blood work is being submitted as well.

SPECIES RADIOGRAPHIC STUDY OF THE THORAX

Canine Orthogonal views of the thorax are provided for review totaling 4 images. Three lateral views, right and left, one ventrodorsal view of the thorax.

BREED RADIOGRAPHIC FINDINGS

Lab The thoracic trachea is normal.
The cardiac silhouette and pulmonary vasculature are normal.

SEX The pulmonary parenchyma is adequate in volume expansion and normal opacity.

Female A thin soft tissue triangle-shaped opaque structure is seen within the cranial mediastinum, cranial to the cardiac silhouette.

AGE The pleural space is normal.

8 Months The thoracic wall and ribs are normal.

INTERPRETED BY The collimated musculoskeletal structures are unremarkable.

Tilde Rodrigues Froes, DMV, MSc., Dr. Med. The collimated abdominal structures are unremarkable.

Vet., Dipl. CBraRVet

RADIOGRAPHIC DIAGNOSIS

- Visible thymus, incidental and correlated to incomplete juvenile involution.
- Normal pulmonary parenchyma.
- No evidence of thoracic abnormalities.

HOSPITAL NAME

Gentle Doctor Animal Hospital

INTERPRETATION OF THE FINDINGS & FURTHER RECOMMENDATIONS

The absence of thoracic radiographic abnormalities does not exclude acute infectious or inflammatory tracheitis/bronchitis, as most affected patients appear radiographically normal, and this is often a diagnosis of exclusion. If signs do not respond adequately to treatment, repeat thoracic radiographs in 7-10 days could be considered to reassess the lungs.

REFERRING VET

Miranda Thomasen

INVOICE

57910

DATE

4-20-23



PATIENT

Josie Bryant

SPECIES

Canine

BREED

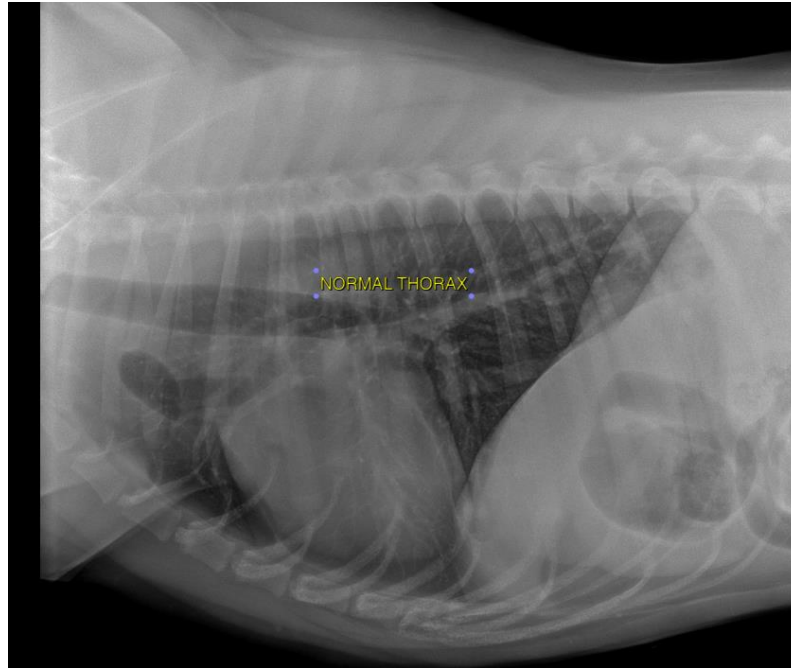
Lab

SEX

Female

AGE

8 Months



INTERPRETED BY

Tilde Rodrigues Froes,
DMV, MSc., Dr. Med
Vet., Dipl. CBraRVet

HOSPITAL NAME

Gentle Doctor Animal
Hospital

REFERRING VET

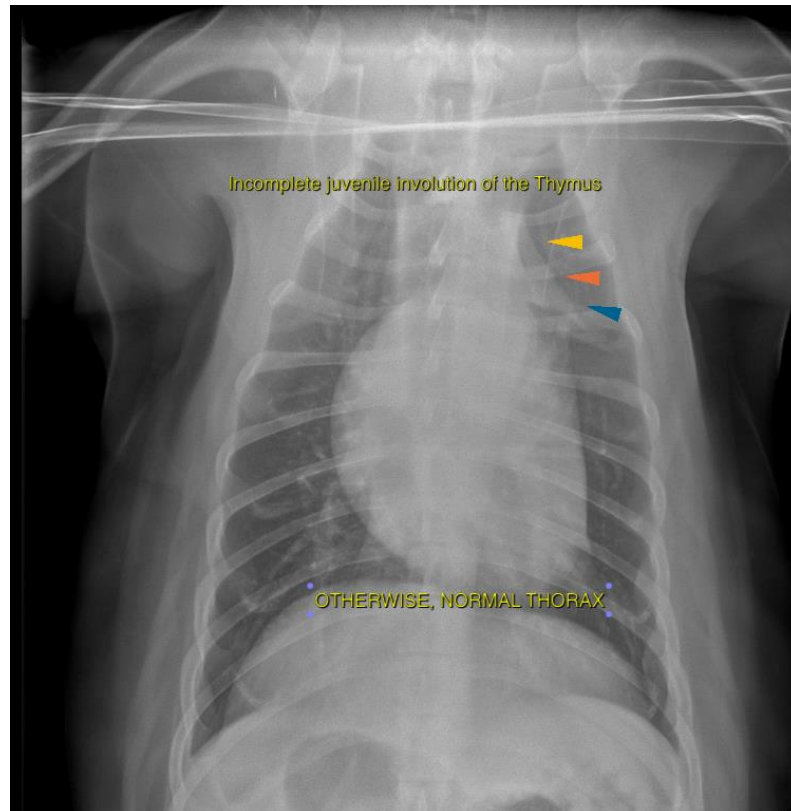
Miranda Thomasen

INVOICE

57910

DATE

4-20-23





PATIENT

Josie Bryant

SPECIES

Canine

The information and recommendations provided are based on the images presented by the referring veterinarian. No evaluation can be communicated regarding pathology that was not visible in the image/video clips provided.

BREED

Lab

Thank you for this referral. If the clinical or image interpretation does not parallel your findings or if I can be of any further assistance please contact me.

Tilde Rodrigues Froes, DMV, MSc., Dr. Med.Vet., Dipl.CBraRVet
info@sonopath.com

SEX

Female

AGE

8 Months

INTERPRETED BY

Tilde Rodrigues Froes,
DMV, MSc., Dr. Med
Vet., Dipl. CBraRVet

HOSPITAL NAME

Gentle Doctor Animal
Hospital

REFERRING VET

Miranda Thomasen

INVOICE

57910

DATE

4-20-23