



PATIENT PRESENTING CLINICAL SIGNS

Calypso Ritter Lameness right hind several weeks, was holding it up but is now toe-touching. Abnormal PE/Chem/CBC/UA Results: On PE right stifle effusion and cranial drawer appreciated under sedation. Remainder of exam WNL. Cbc/chem and coags pending.

SPECIES

Canine

RADIOGRAPHIC STUDY OF PELVIC LIMBS

Orthogonal views of the pelvic limbs are provided for review totaling 4 images. One lateral view of the right stifle, one lateral view of the left stifle, and two ventrodorsal views of the pelvis and pelvic limbs.

BREED

Pit Mix

RADIOGRAPHIC FINDINGS

Right Pelvic Limb

SEX There is articular swelling of the right stifle joint and increased volume extending caudally, medially, and cranially from normal margins, and is compressing the caudal 40% of the infrapatellar fat pad. The proximal tibia is cranially translocated in relation to the distal femur.

Spayed Female

Mild periarticular ossification is seen at the margins of the right patella. On the craniocaudal views, the patella is centrally located and superimposed in the respective femoral trochlea.

AGE

2 Years

The tarsocrural and tarsal joints are normal.

Left Pelvic Limb

INTERPRETED BY

Tilde Rodrigues Froes, DMV, MSc., Dr. Med Vet., Dipl. CBraRVet

There is articular swelling of the left stifle joint and increased volume extending caudally, medially, and cranially from normal margins, and is compressing the caudal 20-30% of the infrapatellar fat pad. The proximal tibia is cranially translocated in relation to the distal femur.

No evidence of periarticular ossification in the stifle joint is seen. On the craniocaudal views, the patella is centrally located and superimposed in the respective femoral trochlea.

HOSPITAL NAME

Northshore Veterinary Hospital

The tarsocrural and tarsal joints are normal.

The pelvis and the coxofemoral joints are normal.

RADIOGRAPHIC DIAGNOSIS

REFERRING VET

Sophie Lee, DVM

- Bilateral stifle joint synovial swelling, right side mild secondary osteoarthritis and subluxation are consistent with partial tear or complete rupture of the cranial cruciate ligament. Differential diagnosis includes concurrent inflammatory joint effusion. The joint synovial swelling is more prominent in the right side.

INVOICE

57905

DATE

4-19-23

INTERPRETATION OF THE FINDINGS & FURTHER RECOMMENDATIONS

The radiographic findings of the right stifle joint are correlated with the patient's history. However, stifle joint swelling is also identified on the left side. Correlate the radiographic findings with specific orthopedic exams, for example, the tibial thrust and cranial drawer. Surgical consultation is suggested for evaluation for further surgical approaches. There is no evident asymmetry between the muscular mass volumes in the pelvic limbs. There is no evidence of an aggressive osseous lesion.



PATIENT

Calypso Ritter

SPECIES

Canine

BREED

Pit Mix

SEX

Spayed Female

AGE

2 Years

INTERPRETED BY

Tilde Rodrigues Froes,
DMV, MSc., Dr. Med
Vet., Dipl. CBraRVet

HOSPITAL NAME

Northshore
Veterinary Hospital

REFERRING VET

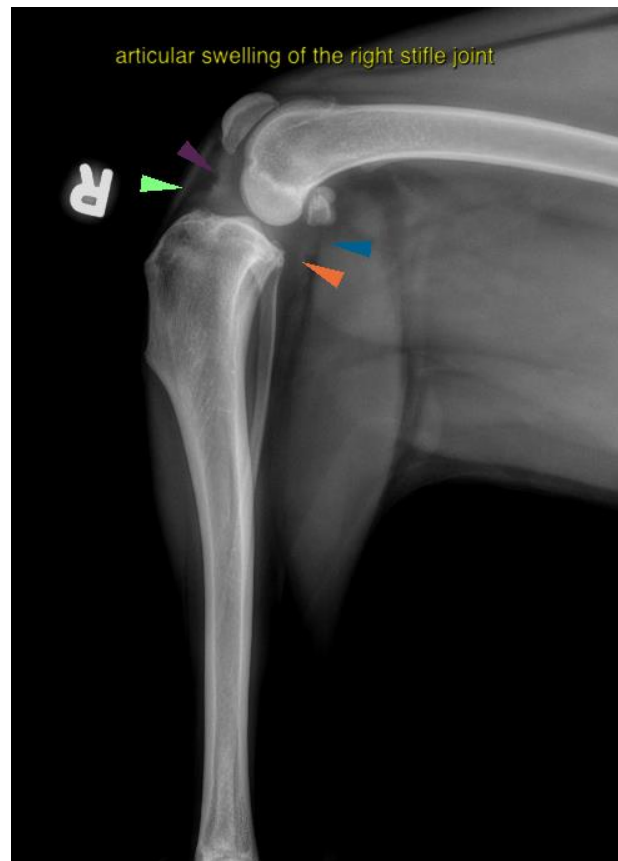
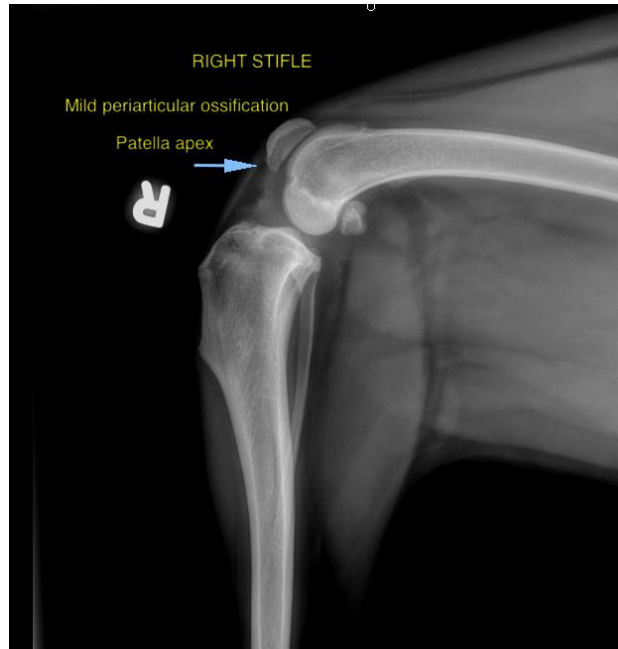
Sophie Lee, DVM

INVOICE

57905

DATE

4-19-23





PATIENT

Calypso Ritter

SPECIES

Canine

BREED

Pit Mix

SEX

Spayed Female

AGE

2 Years

INTERPRETED BY

Tilde Rodrigues Froes,
DMV, MSc., Dr. Med
Vet., Dipl. CBraRVet

HOSPITAL NAME

Northshore
Veterinary Hospital

REFERRING VET

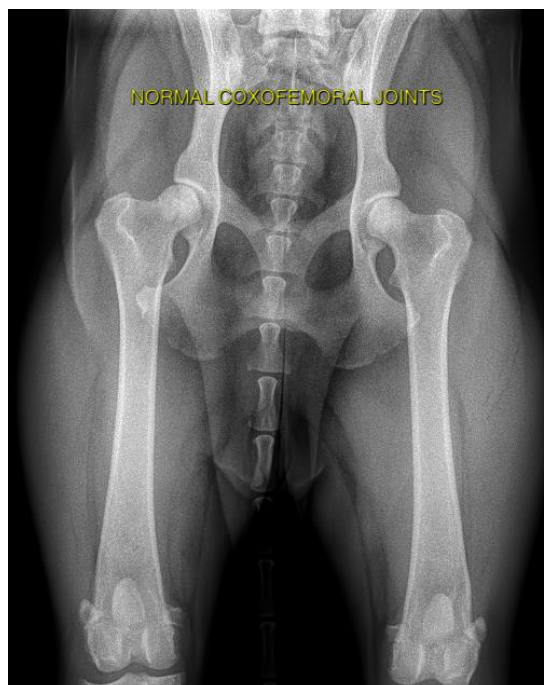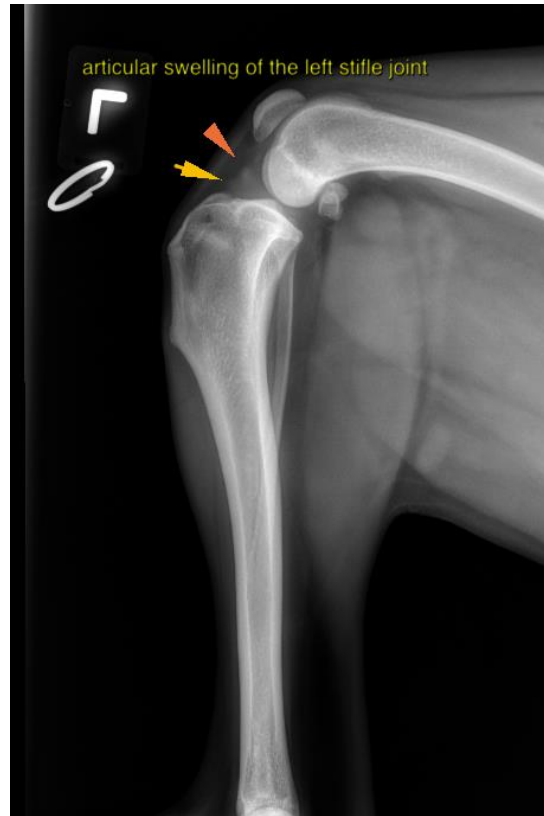
Sophie Lee, DVM

INVOICE

57905

DATE

4-19-23





PATIENT

Calypso Ritter

The information and recommendations provided are based on the images presented by the referring veterinarian. No evaluation can be communicated regarding pathology that was not visible in the image/video clips provided.

SPECIES

Canine

Thank you for this referral. If the clinical or image interpretation does not parallel your findings or if I can be of any further assistance please contact me.

BREED

Pit Mix

Tilde Rodrigues Froes, DMV, MSc., Dr. Med.Vet., Dipl.CBraRVet
info@sonopath.com

SEX

Spayed Female

AGE

2 Years

INTERPRETED BY

Tilde Rodrigues Froes,
DMV, MSc., Dr. Med
Vet., Dipl. CBraRVet

HOSPITAL NAME

Northshore
Veterinary Hospital

REFERRING VET

Sophie Lee, DVM

INVOICE

57905

DATE

4-19-23