



## PATIENT

Finn Schweit

## PRESENTING CLINICAL SIGNS

Right Carpal mass rule out benign versus malignant

## SPECIES

Canine

## COMPUTED TOMOGRAPHIC STUDY OF THE RIGHT THORACIC LIMB – CARPAL REGION

Single post-contrast CT series of the right antebrachial and carpal region.

## BREED

Lab Mix

## COMPUTED TOMOGRAPHIC FINDINGS

### RIGHT ANTEBRACHIAL CARPAL REGION

#### SEX

There is an expansive, mildly irregular soft tissue mass centered in the mediodorsal aspect of the distal antebrachium and carpal region.

MN

#### AGE

6

The lesion demonstrates a heterogeneous internal architecture, with a multiloculated/multicameral appearance characterized by multiple hypoattenuating nodular areas after the post-contrast series. The contrast medium partially outlines and accumulates within adjacent synovial recesses/bursae, contributing to a visible complex internal pattern. Due to the poorly defined margins, precise measurement is limited; however, the lesion measures at least 3.6 × 2.8 cm.

#### WEIGHT

32.7

The mass appears predominantly extra-articular; however, clear delineation between the lesion and the joint capsule/tendon sheaths is limited due to image quality and technique.

## INTERPRETED BY

Tilde Rodrigues Froes,  
DMV, MSc., Dr. Med  
Vet., Dipl. CBraRVet

Topographically, the lesion involves or closely associates with the region of the palmar radiocarpal ligament, abductor pollicis longus muscle, and oblique extensor muscle.

There is no evidence of osseous involvement, including absence of cortical lysis, subchondral cystic change, or periosteal reaction.

## IMAGING PERFORMED BY

David

## COMPUTED TOMOGRAPHIC DIAGNOSIS

- Expansile, multiloculated soft tissue mass in the mediodorsal antebrachial/carpal region, without CT evidence of bone involvement. Differential diagnoses include Synovial-origin lesion (e.g., synovial proliferative disorder) soft tissue neoplasia (e.g., hamartoma, liposarcoma, synovial cell sarcoma, periarticular sarcoma, or other mesenchymal tumor).

## HOSPITAL NAME

Animal Surgical Center  
- Oceanside

## INTERPRETATION OF THE FINDINGS & FURTHER RECOMMENDATIONS

The described lesion is a complex soft tissue mass with multicameral characteristics and apparent association with periarticular synovial structures. The absence of bone lysis is a favorable feature; however, it does not exclude malignancy.

## REFERRING VET

Infernuso

## INVOICE

74580

Recommendations: Consider repeat excisional biopsy with musculoskeletal ultrasound guidance. Surgical excision of the lesion may be attempted; however, difficulty in achieving clean margins should be anticipated with some adhesences.

## DATE

4-14-26

Consider MRI for improved soft tissue characterization and more accurate assessment of joint and tendon sheath involvement.



## PATIENT

Finn Schweit

## SPECIES

Canine

## BREED

Lab Mix

## SEX

MN

## AGE

6

## WEIGHT

32.7

## INTERPRETED BY

Tilde Rodrigues Froes,  
DMV, MSc., Dr. Med  
Vet., Dipl. CBraRVet

## IMAGING PERFORMED BY

David

## HOSPITAL NAME

Animal Surgical Center  
- Oceanside

## REFERRING VET

Inferuso

## INVOICE

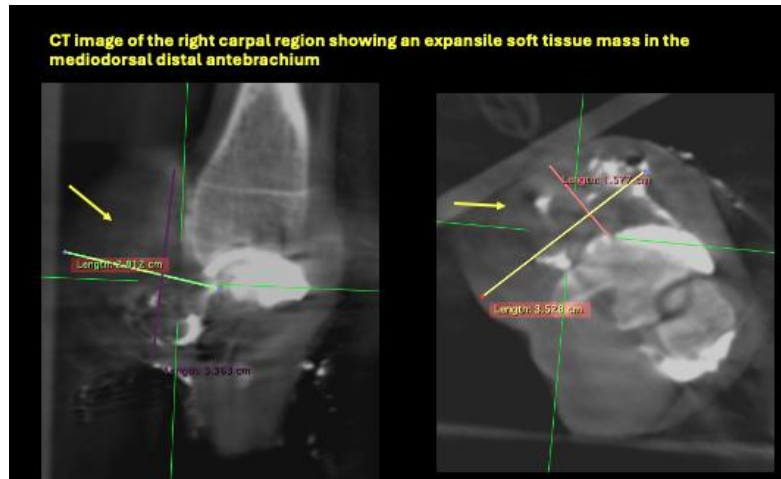
74580

## DATE

4-14-26

## TECHNICAL COMMENTS

Moderate beam-hardening artifact, low contrast resolution, and absence of pre-contrast imaging reduce diagnostic accuracy.



The information and recommendations provided are based on the images presented by the referring veterinarian. No evaluation can be communicated regarding pathology that was not visible in the image/video clips provided.

Thank you for this referral. If the clinical or image interpretation does not parallel your findings or if I can be of any further assistance, please contact me.

Tilde Rodrigues Froes, DMV, MSc., Dr. Med.Vet., Dipl.CBraRVet  
[info@sonopath.com](mailto:info@sonopath.com)