



**PATIENT PRESENTING CLINICAL SIGNS**

Turbo Anjum Limping on right hind for a few days  
 Abnormal PE/Chem/CBC/UA Results: BW unavailable

**SPECIES RADIOGRAPHIC STUDY OF THE PELVIS AND PELVIC LIMBS**

Feline Orthogonal views of the pelvis and pelvic limbs are provided for review totaling 4 images. Two ventrodorsal views, one lateral view focus on the right pelvic limb, stifle. One craniocaudal view focus on the tarsocrural and tarsal joints.

**BREED RADIOGRAPHIC FINDINGS**

Domestic Medium Hair There is discontinuity and mild malalignment of the right femur at the level of the proximal physis consistent with a fracture. Both fragments are in contact but there is mild proximal displacement and mild rotation between the head and neck. The right femoral head remains in place within the acetabulum.

**SEX**

The pelvis and left coxofemoral joint are normal.

Female spayed

The stifle joints are normal.

**AGE**

The tarsocrural, tarsal, metatarsal, interphalangeal joints, and digits of the pes are normal. No evidence of soft tissue swelling.

13 Months

The collimated lumbar and lumbosacral spine are normal.

The collimated abdomen is unremarkable.

**INTERPRETED BY**

Tilde Rodrigues Froes, DMV, MSc., Dr. Med Vet., Dipl. CBraRVet

**RADIOGRAPHIC DIAGNOSIS**

- Right proximal femoral physeal fracture with mild displacement. Differential diagnosis: associated with traumatic event.

**INTERPRETATION OF THE FINDINGS & FURTHER RECOMMENDATIONS**

The radiographic findings are correlated to the clinical signs. Surgical orthopedical consult is suggested with interim management with pain medications and anti-inflammatories.

**HOSPITAL NAME**

St. Catherine's Animal Hospital

**REFERRING VET**

Dr. Boctor

**INVOICE**

57753

**DATE**

4-11-23



**PATIENT**

Turbo Anjum

**SPECIES**

Feline

**BREED**

Domestic Medium  
Hair

**SEX**

Female spayed

**AGE**

13 Months

**INTERPRETED BY**

Tilde Rodrigues Froes,  
DMV, MSc., Dr. Med  
Vet., Dipl. CBraRVet

**HOSPITAL NAME**

St. Catherine's Animal  
Hospital

**REFERRING VET**

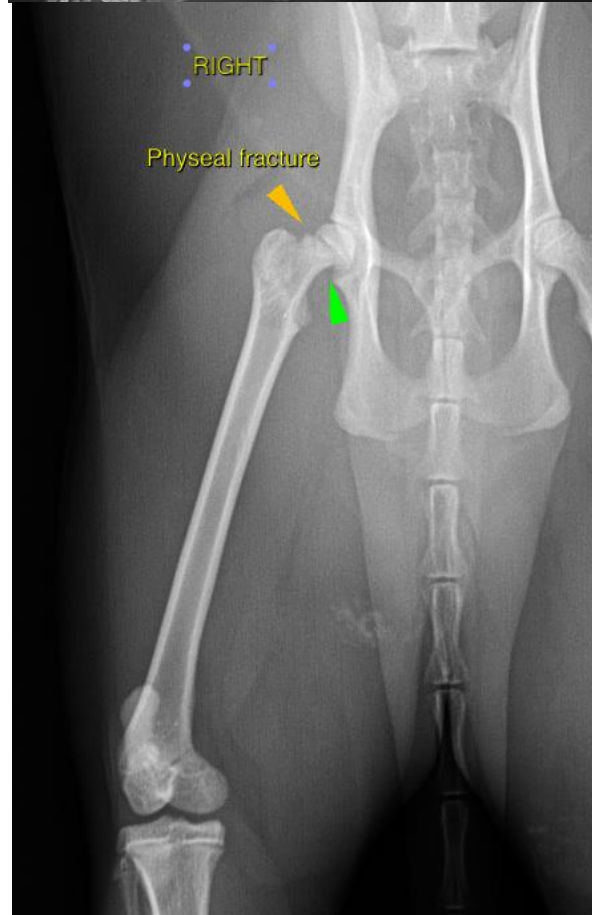
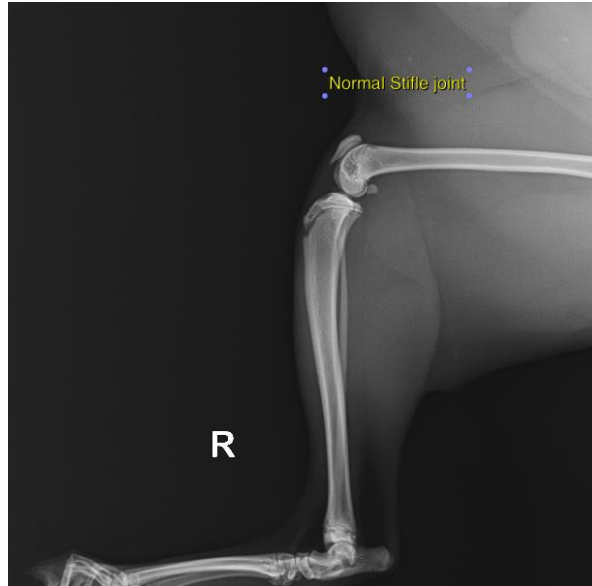
Dr. Boctor

**INVOICE**

57753

**DATE**

4-11-23





**PATIENT**

Turbo Anjum

**SPECIES**

Feline

**BREED**

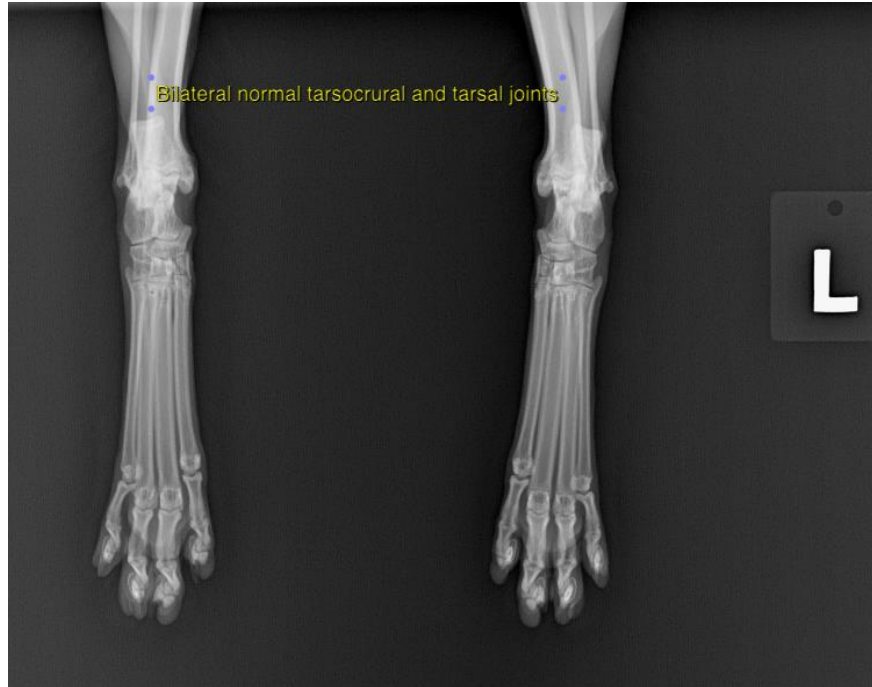Domestic Medium  
Hair

**SEX**

Female spayed

**AGE**

13 Months



**INTERPRETED BY**

Tilde Rodrigues Froes,  
DMV, MSc., Dr. Med  
Vet., Dipl. CBraRVet

The information and recommendations provided are based on the images presented by the referring veterinarian. No evaluation can be communicated regarding pathology that was not visible in the image/video clips provided.

Thank you for this referral. If the clinical or image interpretation does not parallel your findings or if I can be of any further assistance please contact me.

**HOSPITAL NAME**

St. Catherine's Animal  
Hospital

Tilde Rodrigues Froes, DMV, MSc., Dr. Med.Vet., Dipl.CBraRVet  
info@sonopath.com

**REFERRING VET**

Dr. Boctor

**INVOICE**

57753

**DATE**

4-11-23