



PATIENT PRESENTING CLINICAL SIGNS

Dude Cyran Sneezing and nasal discharge.
Abnormal PE/Chem/CBC/UA Results: Mass noted on Right nostril.

SPECIES COMPUTED TOMOGRAPHIC STUDY OF THE HEAD AND CERVICAL SOFT TISSUE

Feline A high-resolution post-contrast CT study of the cervical soft tissue and head are provided for review. One post-contrast series.

BREED COMPUTED TOMOGRAPHIC FINDINGS

DSH A small, mildly enhancing on the post-contrast series, circumferential soft tissue attenuating mass is seen at the rostral portion of the right nostril. The mass causes mild reduction in the air passage. The mass measures approximately 0.5cm x 0.6cm in diameter.

SEX The remainder of the nasal planum is normal.

Neutered Male The nasal cavities, nasal turbinates, and frontal sinuses are unremarkable.

The nasopharynx and choana are unremarkable.

AGE The tympanic bullae and external auditory canals are bilaterally normal.

9 Years, 3 Months The teeth present within normal limits.

INTERPRETED BY The remainder of the bone structures of the head and face are normal.

Tilde Rodrigues Froes, DMV, MSc., Dr. Med. Bilaterally, the retropharyngeal lymph nodes and maxillary lymph nodes are normal.

Vet., Dipl. CBraRVet The collimated thorax is unremarkable.

HOSPITAL NAME The thyroid glands are normal in size, shape, and contour.

Mobile Pet Imaging The temporomandibular joints are bilaterally congruent.

No mass effect in the brain.

REFERRING VET No other abnormalities are identified.

Meaux **COMPUTED TOMOGRAPHIC DIAGNOSIS**

- INVOICE**
- Small soft tissue attenuating mass in the rostral portion of the right nostril causing moderately reduced focal nasal air passage. Differential diagnosis includes neoplasm, for example, squamous cell carcinoma or melanoma.
 - Otherwise, normal nasal cavity.
- 57730

DATE **INTERPRETATION OF THE FINDINGS & FURTHER RECOMMENDATIONS**
Other differential diagnosis is cutaneous lymphoma, fibrosarcoma, mast cell tumor, or fibroma. As performed, a biopsy is required for the diagnosis.

4-11-23

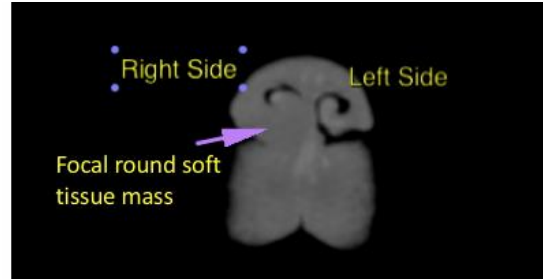
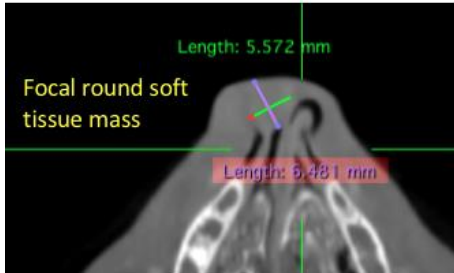


PATIENT

Dude Cyran

SPECIES

Feline



BREED

DSH

SEX

Neutered Male

AGE

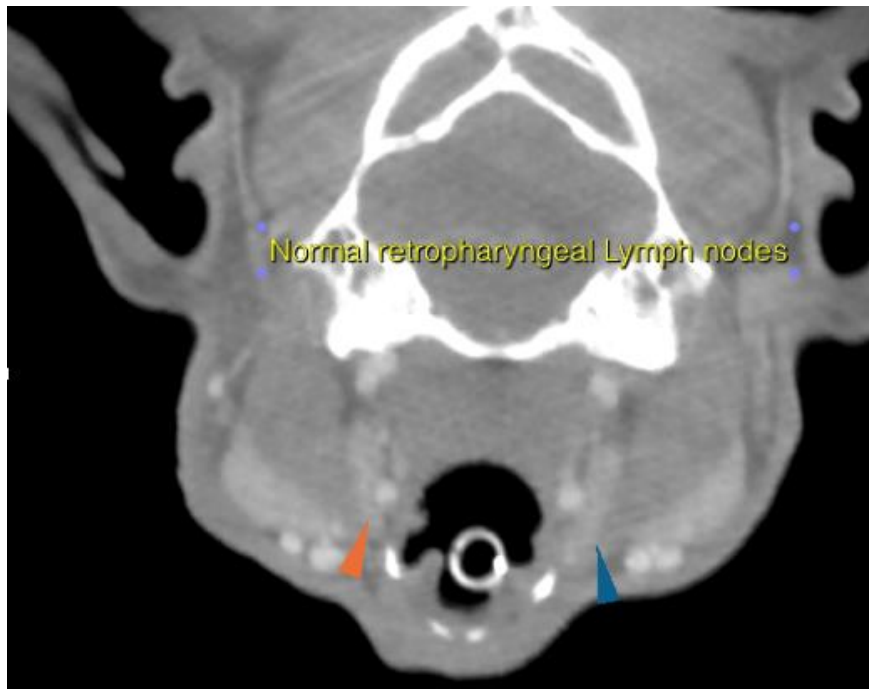
9 Years, 3 Months

INTERPRETED BY

Tilde Rodrigues Froes,
DMV, MSc., Dr. Med
Vet., Dipl. CBraRVet

HOSPITAL NAME

Mobile Pet Imaging



REFERRING VET

Meaux

INVOICE

57730

DATE

4-11-23



PATIENT

Dude Cyran

SPECIES

Feline

BREED

DSH

SEX

Neutered Male

AGE

9 Years, 3 Months

INTERPRETED BY

Tilde Rodrigues Froes,
DMV, MSc., Dr. Med
Vet., Dipl. CBraRVet

HOSPITAL NAME

Mobile Pet Imaging

REFERRING VET

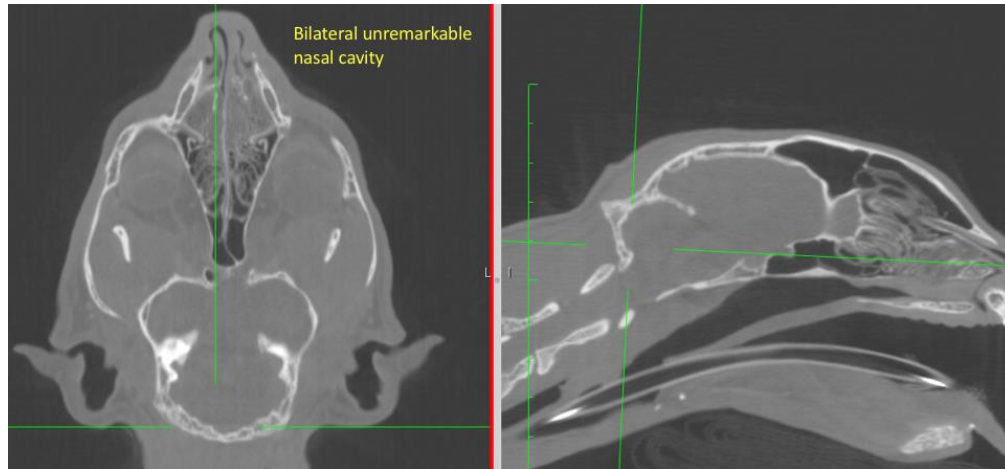
Meaux

INVOICE

57730

DATE

4-11-23



The information and recommendations provided are based on the images presented by the referring veterinarian. No evaluation can be communicated regarding pathology that was not visible in the image/video clips provided.

Thank you for this referral. If the clinical or image interpretation does not parallel your findings or if I can be of any further assistance please contact me.

Tilde Rodrigues Froes, DMV, MSc., Dr. Med.Vet., Dipl.CBraRVet
info@sonopath.com