



**PATIENT PRESENTING CLINICAL SIGNS**

Baby Reynolds intermittent signs of IVDD

**SPECIES COMPUTED TOMOGRAPHIC STUDY OF THE SPINE**

Canine A pre- post-contrast CT study of the cervical, thoracic, thoracolumbar, lumbar, and lumbosacral spine are provided for review. One pre-contrast series of the cervical spine, one pre-contrast series of the total spine. One post-contrast series of the cervical spine and one post-contrast series of the cervical and cervicothoracic spine.

**BREED COMPUTED TOMOGRAPHIC FINDINGS**

Maltese Mix SPINE (C1-C7, T1-T13 and L1-Sacrum).

**SEX** Seven cervical, thirteen thoracic, seven lumbar vertebrae and L7-S1 are seen.

FS Centered on the mid to caudal extremity of C7 vertebral body is a permeative osteolytic lesion, and mild loss of the left side cortical border.

**AGE** The bone attenuation of the L3 vertebral body presents with mild heterogeneity and minor cystic lesions.

10 Years At the level of C4-C5, within the ventral aspect of the vertebral canal, there is a mild amount of heterogeneous hyperattenuating material with minor dorsal displacement and compression of the spinal cord.

**INTERPRETED BY**

Tilde Rodrigues Froes, DMV, MSc., Dr. Med Vet., Dipl. CBraRVet The remainder of the vertebral bodies are normal in size, shape and attenuation. Normal spine alignment, the dens is intact.

On the collimated abdomen:

**HOSPITAL NAME**

Animal Medical Center of Mt. Pleasant The liver is diffusely enlarged, bulb shape, and normal attenuation. No masses are identified. The right kidney is severely decreased in size as compared to the left, with mild pelvic dilatation. The ureters are normal. Otherwise, normal abdomen.

**REFERRING VET**

Epstein On the collimated thorax: No evidence of mediastinal lymph node enlargement. Normal lung parenchyma, no evidence of pulmonary nodules.

**INVOICE**

57729 The lumen of the left main bronchus is moderately reduced, collapse (grade 2/3).

**DATE**

4-11-23



**PATIENT COMPUTED TOMOGRAPHIC DIAGNOSIS**

- PATIENT** Baby Reynolds
- SPECIES** Canine
- BREED** Maltese Mix
- Monostotic aggressive osteolytic lesion of the caudal extremity of the C7 vertebral body. The differential diagnosis includes neoplasm, for example plasmacytoma or metastatic lesion of unknown origin.
- Equivocal osteolytic lesions or hypoattenuating fat deposition in the L3 vertebral body.
- Mild volume of extradural material causing minor spinal cord compression consistent with intervertebral disc herniation at C4-C5.
- Right kidney hypoplasia, chronic renal disease. The differential diagnosis includes concurrent chronic pyelonephritis.
- Hepatomegaly, no masses. The differential diagnosis includes metabolic hepatopathy, hepatitis or infiltrative neoplasia, for example round cell tumor.
- Dynamic left sided bronchial collapse, correlated with possible respiratory clinical sign.

**INTERPRETATION OF THE FINDINGS & FURTHER RECOMMENDATIONS**

**SEX** Another possible differential diagnosis, if an association of the monostotic aggressive osteolytic lesion of the caudal extremity of the C7 vertebral body with an equivocal osteolytic change in the L3 vertebral body were considered true, would include multiple myeloma. Therefore, a FNA or biopsy is required for diagnosis. An MRI could be considered as a next approach for better explanation of the multifocal bone lesions.

**AGE** No evidence of pulmonary metastatic lesion or enlarged mediastinal lymph nodes.

10 Years

**INTERPRETED BY**

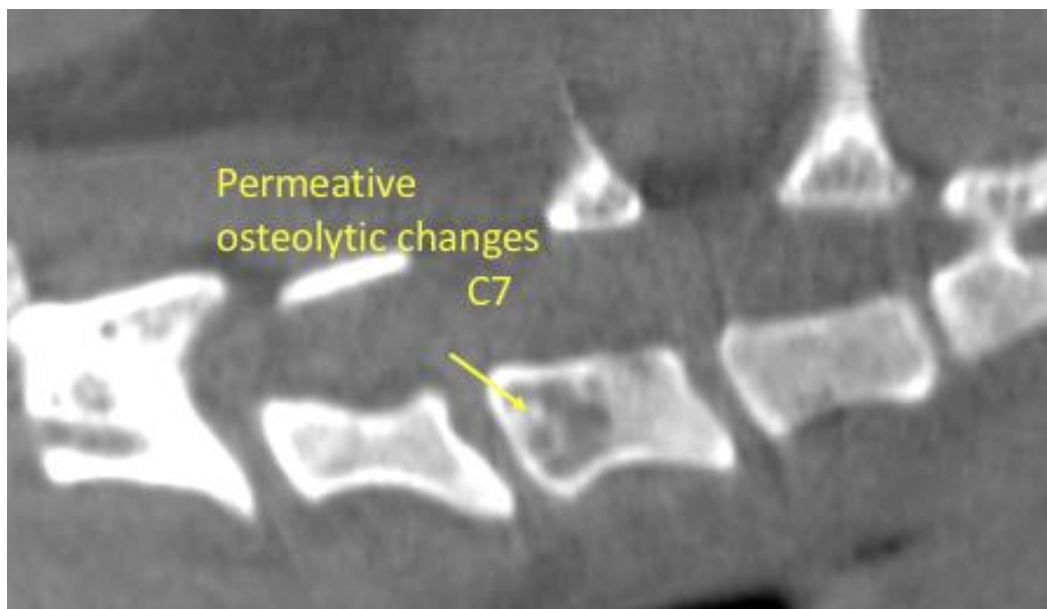
Tilde Rodrigues Froes,  
DMV, MSc., Dr. Med  
Vet., Dipl. CBraRVet

**HOSPITAL NAME**

Animal Medical  
Center of Mt.  
Pleasant

**REFERRING VET**

Epstein



**INVOICE**

57729

**DATE**

4-11-23

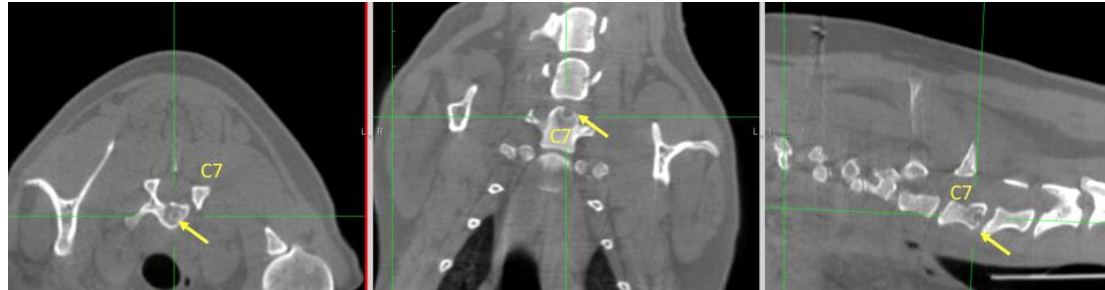

**PATIENT**

Baby Reynolds

**SPECIES**

Canine



**BREED**

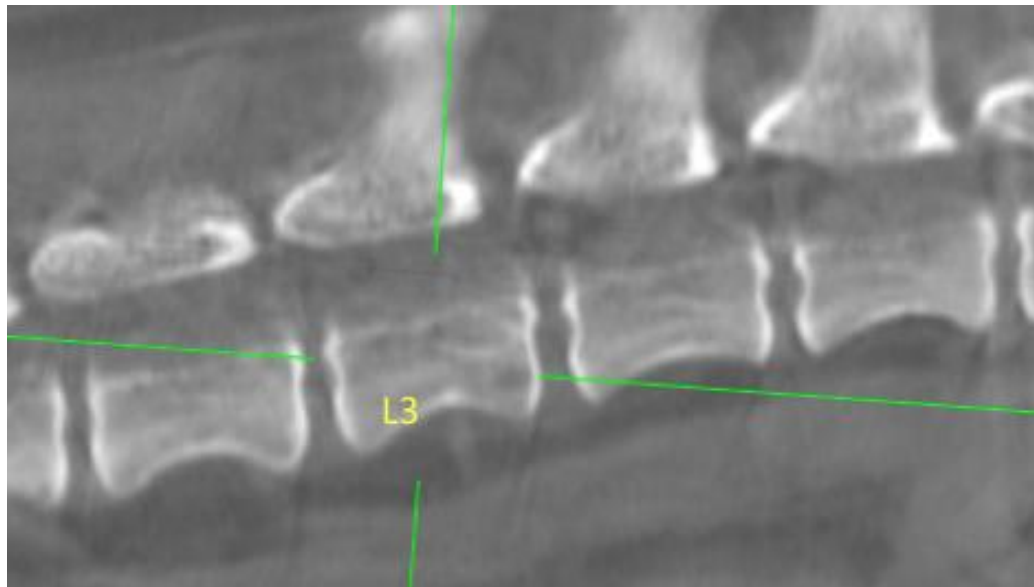
Maltese Mix

**SEX**

FS

**AGE**

10 Years

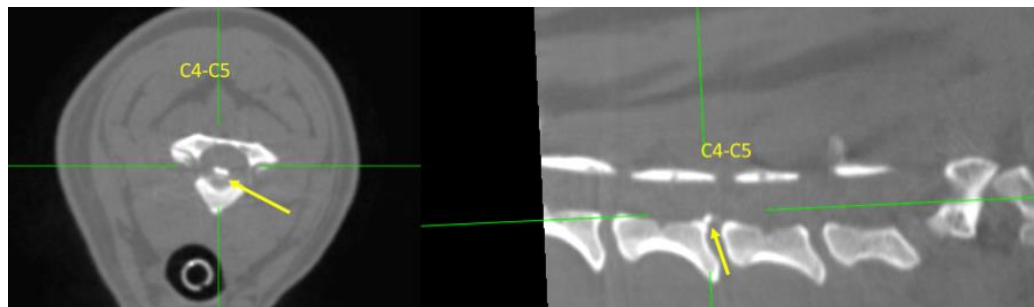


**INTERPRETED BY**

Tilde Rodrigues Froes,  
DMV, MSc., Dr. Med  
Vet., Dipl. CBraRVet

**HOSPITAL NAME**

Animal Medical  
Center of Mt.  
Pleasant



**REFERRING VET**

Epstein

**INVOICE**

57729

**DATE**

4-11-23



**PATIENT**

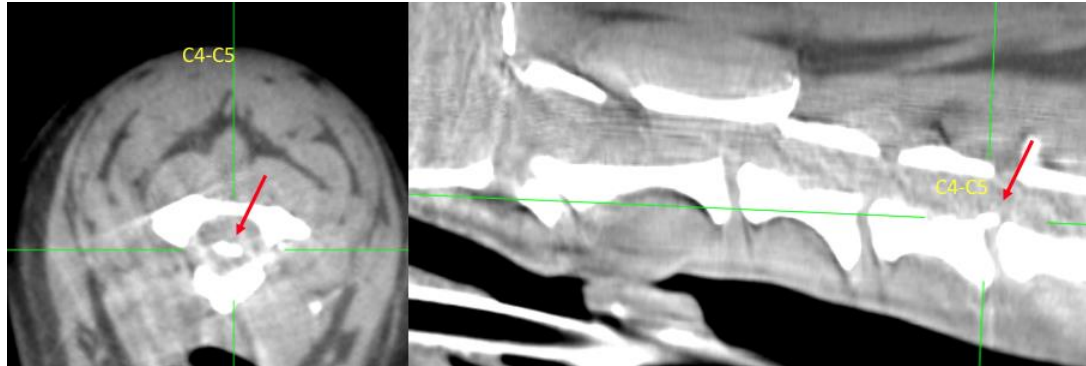
Baby Reynolds

**SPECIES**

Canine

**BREED**

Maltese Mix



**SEX**

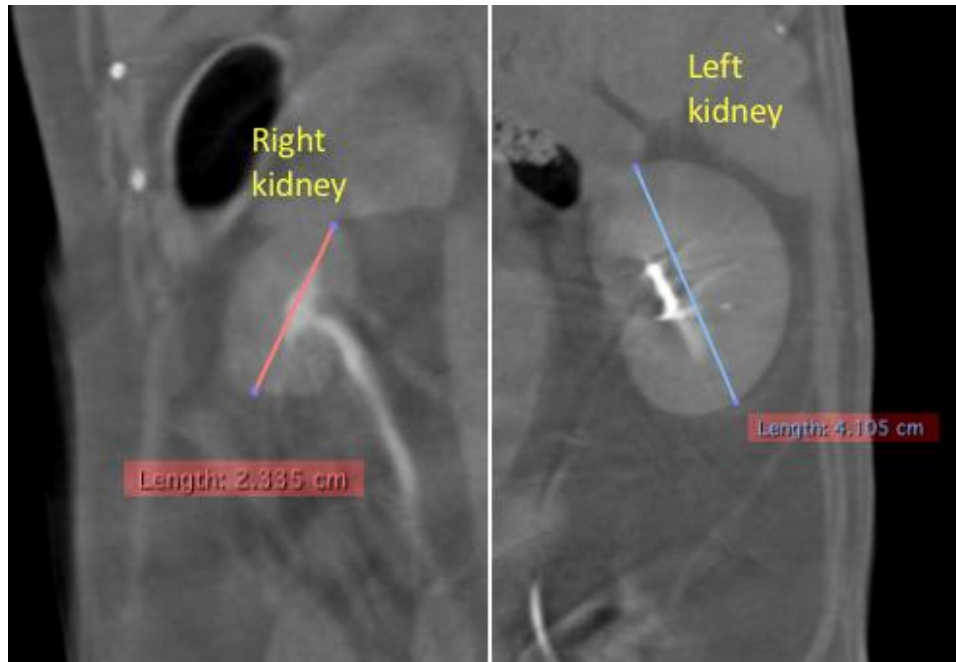
FS

**AGE**

10 Years

**INTERPRETED BY**

Tilde Rodrigues Froes,  
DMV, MSc., Dr. Med  
Vet., Dipl. CBraRVet



**HOSPITAL NAME**

Animal Medical  
Center of Mt.  
Pleasant

**REFERRING VET**

Epstein

The information and recommendations provided are based on the images presented by the referring veterinarian. No evaluation can be communicated regarding pathology that was not visible in the image/video clips provided.

Thank you for this referral. If the clinical or image interpretation does not parallel your findings or if I can be of any further assistance please contact me.

**INVOICE**

57729

Tilde Rodrigues Froes, DMV, MSc., Dr. Med.Vet., Dipl.CBraRVet  
info@sonopath.com

**DATE**

4-11-23