



PATIENT PRESENTING CLINICAL SIGNS

Cleo Cutler
 RIGHT TPLO surgery February 2022, seen for complications at the site 3/2022, was found to have significant infection in the joint and bone. TPLO plate was removed 2 months post placement and P did well following this. Came up acutely limping on the right hind limb two weeks ago with no improvement.

SPECIES
Canine
 Abnormal PE/Chem/CBC/UA Results: Laxity palpated in the right knee joint with pain. Normal palpation of right knee. Obtaining joint fluid today and sending out for culture.

BREED
Boxer Mix
RADIOGRAPHIC STUDY OF PELVIC LIMBS.
 Orthogonal views of the pelvic limbs are provided for review totaling 4 images. One lateral view of the right pelvic limb focuses on stifle joint. One lateral view of the left pelvic limb focuses on stifle joint. On VD dorsal view of pelvis and pelvic limbs.

SEX RADIOGRAPHIC FINDINGS

Female Spayed
Right Pelvic Limb

There is articular swelling of the right stifle joint, as well as volume increase, extending caudally, medially, and cranially from normal margins, and is compressing the caudal 40% of the infrapatellar fat pad.

AGE
5 Years
 The proximal tibia is mildly cranially translocated in relation to the distal femur.

Moderate periarticular ossification is seen at the margins of the right patella, femoral trochlear ridges, tibial condyles, and sesamoids of the gastrocnemius.

INTERPRETED BY
Tilde Rodrigues Froes, DMV, MSc., Dr. Med Vet., Dipl. CBraRVet
 Subchondral bone cyst formation and sclerosis of the femoral and tibial condyles are noted.

Mild thickening of the patellar ligament is seen.

The tarsocrural, tarsal, and tarsometatarsal joints are normal.

HOSPITAL NAME
Petroglyph Animal Hospital
 The popliteal lymph node is normal.

There is decrease in right pelvic limb muscle mass volume in comparison to the left side.

Left Pelvic Limb

REFERRING VET
Whitney Jones
 There is an articular swelling of the left stifle joint, as well as volume increase, extending caudally and cranially from normal margins, and is compressing the caudal 20% of the infrapatellar fat pad. No evidence of periarticular ossification.

The tarsocrural, tarsal, and tarsometatarsal joints are normal.

INVOICE
57121
 The pelvis and coxofemoral joints are normal.

The collimated caudal lumbar and lumbosacral spine are normal, visible on the VD view.

DATE
3-7-23



PATIENT **RADIOGRAPHIC DIAGNOSIS**

Cleo Cutler • Moderate secondary right stifle osteoarthritis, healing tibial plateau osteotomy, no visible metallic implant, joint synovial swelling. Differential diagnosis includes inflammatory joint effusion, possible meniscal tear, and patellar desmitis. No evidence of aggressive osseous bone lesions.

SPECIES

Canine • Right side muscular mass disuse atrophy.
 • Mild left stifle joint synovial swelling. Differential diagnosis includes soft tissue trauma, inflammatory joint effusion, partial tear of the cranial cruciate ligament, positional artifact.
 • Normal pelvis and coxofemoral joints.

BREED

Boxer Mix

INTERPRETATION OF THE FINDINGS & FURTHER RECOMMENDATIONS

No evidence of aggressive osseous bone lesions are seen in the right stifle joint that indicate septic arthritis, and no evidence of popliteal lymph node enlargement. The findings are correlated to the secondary changes, osteoarthritis, and concurrent patellar desmitis; a possible consequence of the previous stifle instability and surgery. Association with joint effusion analysis is recommended because there is a lag behind the clinical course of acute septic arthritis and radiographic findings.

SEX

Female Spayed

AGE

5 Years

Correlate the left stifle radiographic findings with orthopedical exam results, for example, tibial thrust and cranial drawer.

INTERPRETED BY

Tilde Rodrigues Froes,
 DMV, MSc., Dr. Med
 Vet., Dipl. CBraRVet

HOSPITAL NAME

Petroglyph Animal
 Hospital

REFERRING VET

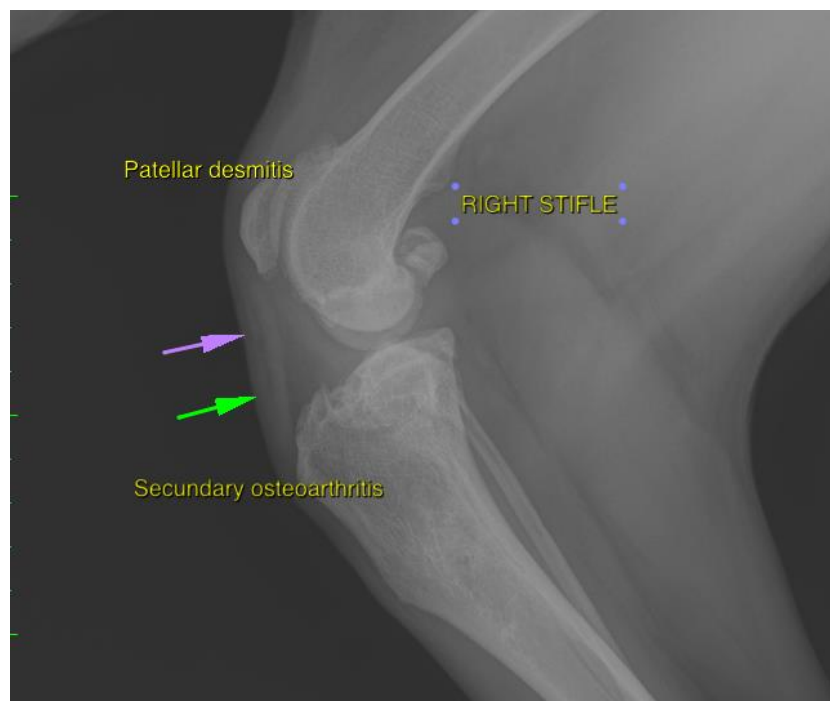
Whitney Jones

INVOICE

57121

DATE

3-7-23





PATIENT

Cleo Cutler

SPECIES

Canine

BREED

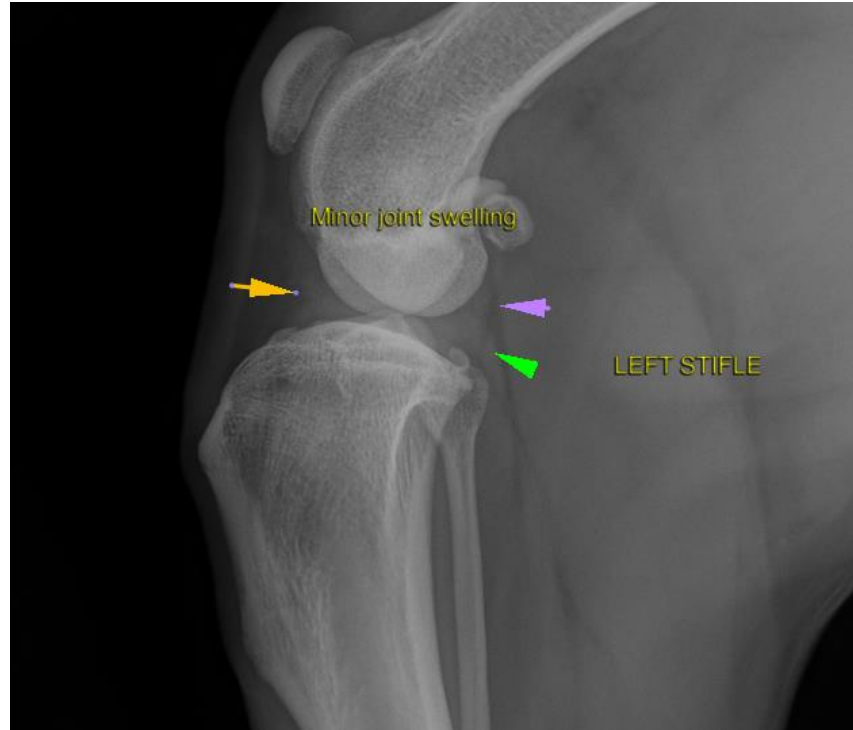
Boxer Mix

SEX

Female Spayed

AGE

5 Years



INTERPRETED BY

Tilde Rodrigues Froes,
DMV, MSc., Dr. Med
Vet., Dipl. CBraRVet

The information and recommendations provided are based on the images presented by the referring veterinarian. No evaluation can be communicated regarding pathology that was not visible in the image/video clips provided.

Thank you for this referral. If the clinical or image interpretation does not parallel your findings or if I can be of any further assistance please contact me.

HOSPITAL NAME

Petroglyph Animal
Hospital

Tilde Rodrigues Froes, DMV, MSc., Dr. Med.Vet., Dipl.CBraRVet
info@sonopath.com

REFERRING VET

Whitney Jones

INVOICE

57121

DATE

3-7-23