



PATIENT PRESENTING CLINICAL SIGNS

Mandoo Lee
SPECIES
 Chief complaint: limping hx of present illness symptoms: has been limping on the right hindlimb, on and off for the past year. Previous vet gave carprofen, and that seemed to help while he was on it. Is slower getting up, and seems to limp more after physical activity. Owner reports that he is also scratching ears and shaking head, on and off the past year as well. Owner used to take Mandoo to groomer, but stopped. tries to clean ears and give ear solution but unable to.

Canine
 Abnormal PE/Chem/CBC/UA Results: Most recent bloodwork results from 10/2022. RBC: 9.01, MCH: 21.1, Reticulocytes: 135, Reticulocyte Hemoglobin: 24.2, Cholesterol: 114, Creatine Kinase: 210 Liver, kidney, and thyroid values are healthy and within normal limits.

BREED RADIOGRAPHIC STUDY OF PELVIC LIMBS

Jindo
 Orthogonal views of the pelvic limbs are provided for review totaling 3 images. One lateral view of the right-side pelvic limb focuses on stifle joint, one lateral view of the left-side pelvic limb focuses on stifle joint, and one VD view of the pelvis and stifle joints. The VD view is mildly oblique.

SEX RADIOGRAPHIC FINDINGS

Male Neutered
Right Pelvic Limb

AGE
 There is mild articular swelling of the right stifle joint and increase in volume, extending caudally and cranially from normal margins, and is compressing the 20% of the infrapatellar fat pad.

2
 The proximal tibia is cranially translocated in relation to the distal femur.

INTERPRETED BY

Mild periarticular ossification is seen at the margins of the right patella, femoral trochlear ridges, minor at the femoral condyles, and sesamoids of the gastrocnemius.

Tilde Rodrigues Froes, DMV, MSc., Dr. Med Vet., Dipl. CBraRVet

The tarsocrural and tarsal joints are normal.

There is decrease in right pelvic limb muscle mass volume in comparison with the left side.

Left Pelvic Limb

HOSPITAL NAME

The stifle joint and fat-pad opacity are normal.

Green Dog Dental and Wellness

The tarsocrural and tarsal joints are normal.

Normal pelvis and coxofemoral joints.

REFERRING VET

RADIOGRAPHIC DIAGNOSIS

Dr. Claudia Lau

- Mild right-side stifle joint synovial swelling, mild secondary osteoarthritis and subluxation are suggestive of partial tear of the cranial cruciate ligament. Differential diagnosis includes concurrent inflammatory joint effusion, synovial hyperplasia.
- Right-side pelvic muscle mass disuse atrophy.
- The left pelvic limb, pelvis and coxofemoral joints are unremarkable.

INVOICE

57539

DATE

3-29-23



PATIENT INTERPRETATION OF THE FINDINGS & FURTHER RECOMMENDATIONS

Mandoo Lee The radiographic findings of the right stifle joint correlate with the patient's history of chronic lameness. Correlate the radiographic findings with specific orthopedic exams, for example, the tibial thrust and cranial drawer. Surgical consultation is suggested for further approaches. There is no evidence of an aggressive osseous lesion.

SPECIES

Canine

BREED

Jindo

SEX

Male Neutered

AGE

2

INTERPRETED BY

Tilde Rodrigues Froes,
DMV, MSc., Dr. Med
Vet., Dipl. CBraRVet

HOSPITAL NAME

Green Dog Dental and
Wellness

REFERRING VET

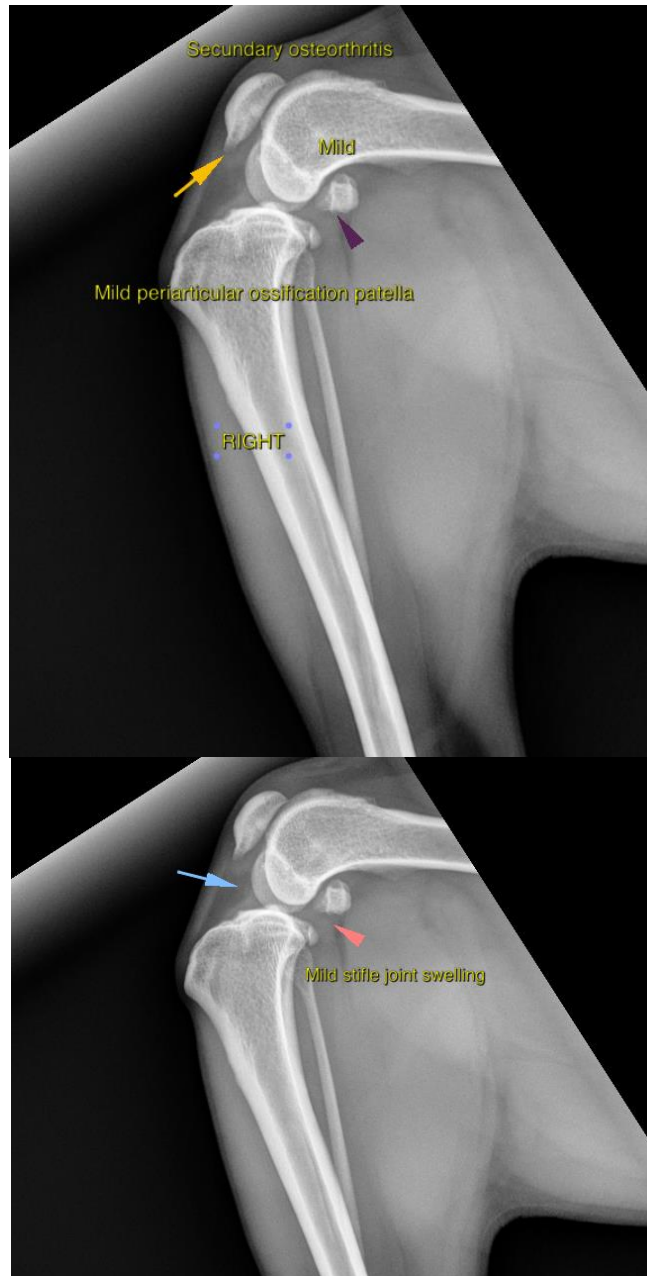
Dr. Claudia Lau

INVOICE

57539

DATE

3-29-23





PATIENT

Mandoo Lee

SPECIES

Canine

BREED

Jindo

SEX

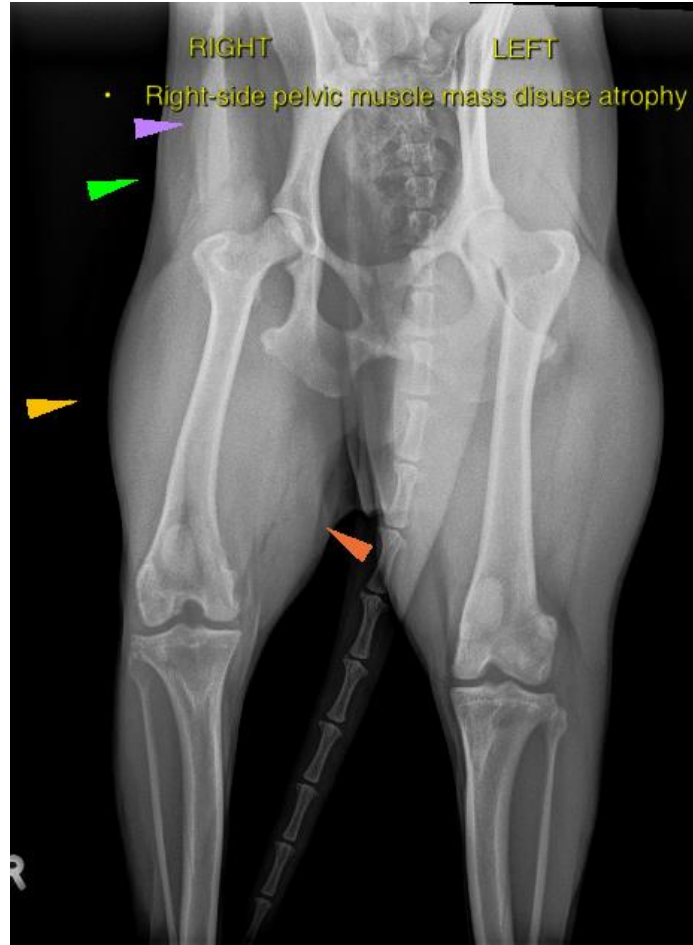
Male Neutered

AGE

2

INTERPRETED BY

Tilde Rodrigues Froes,
DMV, MSc., Dr. Med
Vet., Dipl. CBraRVet



HOSPITAL NAME

Green Dog Dental and
Wellness

The information and recommendations provided are based on the images presented by the referring veterinarian. No evaluation can be communicated regarding pathology that was not visible in the image/video clips provided.

REFERRING VET

Dr. Claudia Lau

Thank you for this referral. If the clinical or image interpretation does not parallel your findings or if I can be of any further assistance please contact me.

INVOICE

57539

Tilde Rodrigues Froes, DMV, MSc., Dr. Med.Vet., Dipl.CBraRVet
info@sonopath.com

DATE

3-29-23