

**PATIENT PRESENTING CLINICAL SIGNS**

Moose Comer P presented for a limp on front right limb, No injury O could remember but P does run alot

**SPECIES**

K9

**RADIOGRAPHIC STUDY OF THE RIGHT AND LEFT THORACIC LIMBS**

Orthogonal views of the right thoracic limb and left thoracic limb are available for review. A total of 6 images. Two cranial caudal views, two lateral views and two lateral flexed views.

**RADIOGRAPHIC FINDINGS****BREED**

The right and left shoulder joints are congruent with normal opacity.

Golden Retriever

The right and left humeroulnar and humeroradial joints are normal.

**SEX**

NM

Bilaterally, the humerus, radius and ulna are normal.

Bilaterally, the antebrachial, carpal, metacarpal, and interphalangeal joints are normal.

No soft tissue swelling or mass effect adjacently.

**AGE**

2 Years

No aggressive osseous or acute traumatic lesion are seen.

**RADIOGRAPHIC DIAGNOSIS**

- Normal thoracic limbs.
- No traumatic osseous lesions, aggressive osseous lesions, or soft tissue swelling.

**INTERPRETED BY**

Tilde Rodrigues Froes,  
DMV, MSc., Dr. Med  
Vet., Dipl. CBraRVet

**INTERPRETATION OF THE FINDINGS & FURTHER RECOMMENDATIONS**

No radiographic lesion that explains the presented clinical signs. The elbow and shoulder joints are normal. Consider as differential diagnosis a soft tissue sprain or strain injury. If signs persist or worsen with conservative management, a musculoskeletal ultrasound based on orthopedic localization may be useful in reevaluation.

**HOSPITAL NAME**

Golden Isles Animal  
Hospital

**REFERRING VET**

James Hornbuckle

**INVOICE**

57515

**DATE**

3-28-23



**PATIENT**

Moose Comer

**SPECIES**

K9

**BREED**

Golden Retriever

**SEX**

NM

**AGE**

2 Years

**INTERPRETED BY**

Tilde Rodrigues Froes,  
DMV, MSc., Dr. Med  
Vet., Dipl. CBraRVet

**HOSPITAL NAME**

Golden Isles Animal  
Hospital

**REFERRING VET**

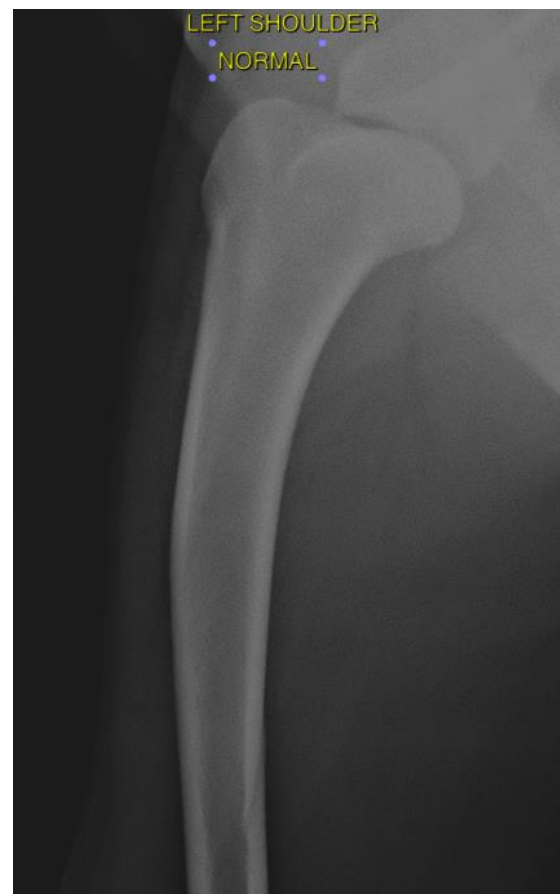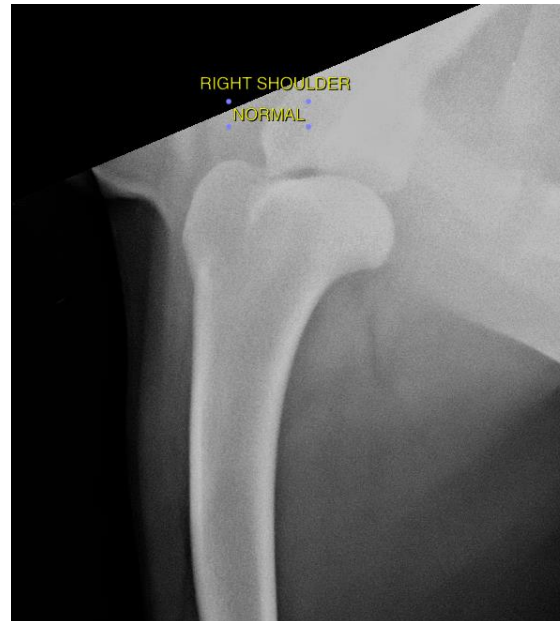James Hornbuckle

**INVOICE**

57515

**DATE**

3-28-23





**PATIENT**

Moose Comer

**SPECIES**

K9

**BREED**

Golden Retriever

**SEX**

NM

**AGE**

2 Years

**INTERPRETED BY**

Tilde Rodrigues Froes,  
DMV, MSc., Dr. Med  
Vet., Dipl. CBraRVet

**HOSPITAL NAME**

Golden Isles Animal  
Hospital

**REFERRING VET**

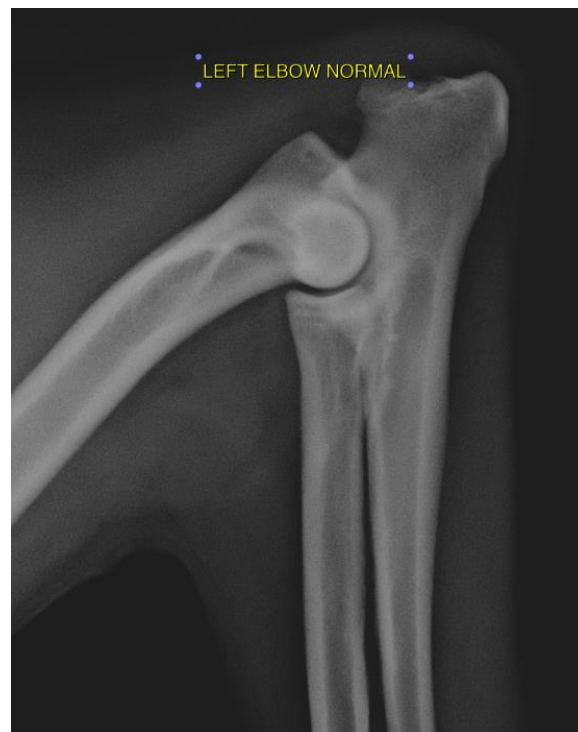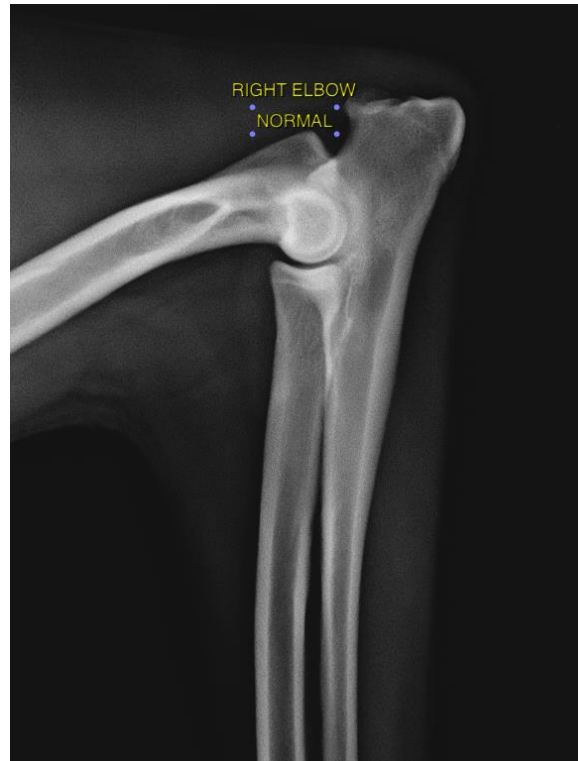
James Hornbuckle

**INVOICE**

57515

**DATE**

3-28-23





**PATIENT**

Moose Comer

The information and recommendations provided are based on the images presented by the referring veterinarian. No evaluation can be communicated regarding pathology that was not visible in the image/video clips provided.

**SPECIES**

K9

Thank you for this referral. If the clinical or image interpretation does not parallel your findings or if I can be of any further assistance please contact me.

**BREED**

Golden Retriever

**Tilde Rodrigues Froes, DMV, MSc., Dr. Med.Vet., Dipl.CBraRVet**  
info@sonopath.com

**SEX**

NM

**AGE**

2 Years

**INTERPRETED BY**

Tilde Rodrigues Froes,  
DMV, MSc., Dr. Med  
Vet., Dipl. CBraRVet

**HOSPITAL NAME**

Golden Isles Animal  
Hospital

**REFERRING VET**

James Hornbuckle

**INVOICE**

57515

**DATE**

3-28-23