



PATIENT PRESENTING CLINICAL SIGNS

Ariel Kidney Referral- history of chronic rhinitis, more prominent in the left nostril.

SPECIES COMPUTED TOMOGRAPHIC STUDY OF THE HEAD

Feline A pre and post-contrast study of the head are provided for review.
The laterality markers may be flipped because the more destructive lesion is evident on right side.

BREED COMPUTED TOMOGRAPHIC FINDINGS

Domestic Shorthair There is moderate loss of turbinate architecture more severe at the right nasal cavity. The nasal turbinates are asymmetrical with minor hypoattenuating fluid material accumulation in the more rostral and ventral portions. No evident mass effect is seen. The sphenoidal and frontal sinuses are unremarkable. The choana and nasopharynx are normal.

SEX The tympanic bullae are almost entirely filled with a hypoattenuating fluid material. Bilateral hyperostosis is also seen, and mild expansion of the bullae.

FS

The retrobulbar spaces and globes are intact.

AGE

10 Years, 2 Months The cribriform plate is intact. No mass effect is seen in the brain.
The temporomandibular joints are bilaterally congruent.

INTERPRETED BY

Tilde Rodrigues Froes, DMV, MSc., Dr. Med Vet., Dipl. CBraRVet

All teeth are present. There is variable horizontal and vertical bone loss along the teeth.
The medial retropharyngeal lymph nodes are mildly thickened, bilaterally. The right retropharyngeal lymph node measures 0.48cm thickened. The left retropharyngeal lymph node measures 0.51cm.
The mandibular lymph nodes are normal.

HOSPITAL NAME

Catskill Veterinary Services, PLLC

COMPUTED TOMOGRAPHIC DIAGNOSIS

- Bilateral moderate chronic destructive rhinitis and minor fluid accumulation, the lesion is more destructive at the right side.
- Bilateral otitis media.
- Mild retropharyngeal lymphadenopathy, reactive.
- Mild periodontal disease.

REFERRING VET

Walker Valley Veterinary

INTERPRETATION OF THE FINDINGS & FURTHER RECOMMENDATIONS

Bilateral destructive rhinitis, more right side, the differential diagnosis includes fungal rhinitis, viral rhinitis, inflammatory lymphocytic plasmocytic, and concurrent bacterial. An overlap between neoplasia and destructive rhinitis exists, however, no mass effect is seen. Concurrent minor secondary nasal fluid accumulation is seen. Nasal flush biopsy is suggested for confirmation.

INVOICE

57482 An otoscopy exam is suggested for better analysis of the auditory canal.

DATE

3-28-23

Correlate the dental findings with oral exam.



PATIENT

Ariel Kidney

SPECIES

Feline

BREED

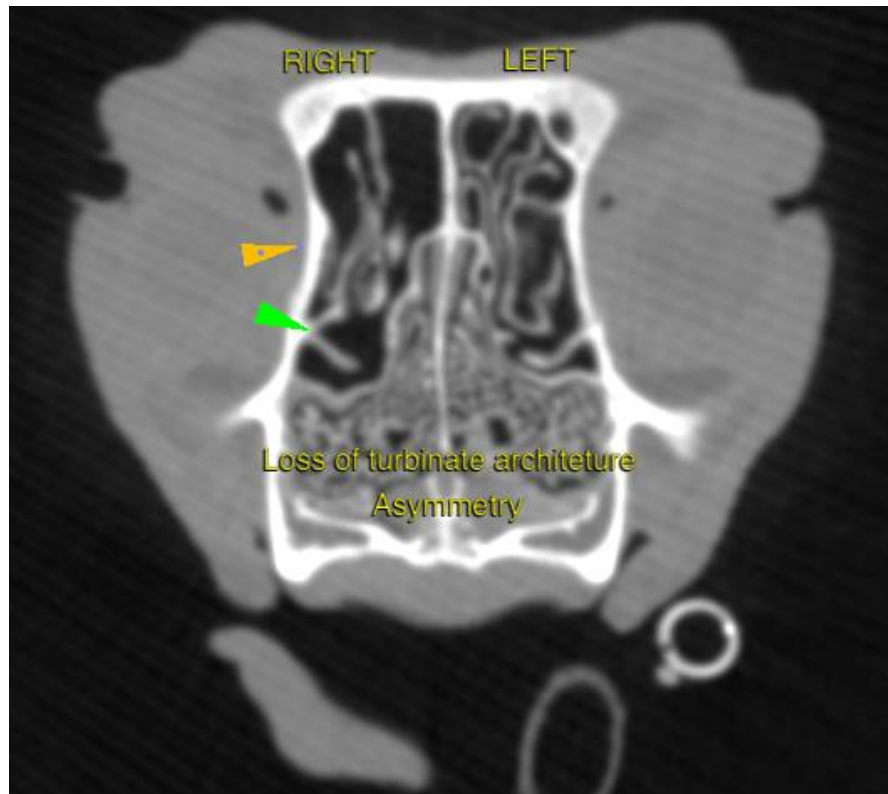
Domestic Shorthair

SEX

FS

AGE

10 Years, 2 Months



INTERPRETED BY

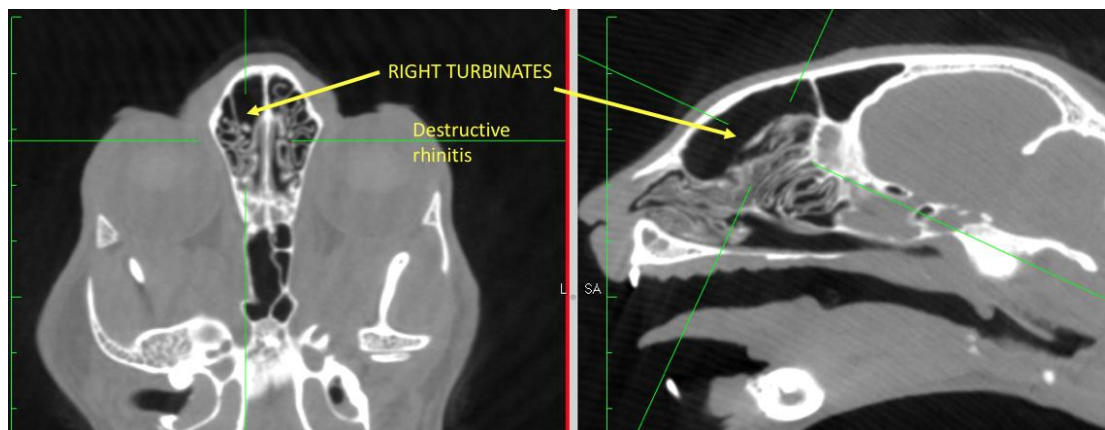
Tilde Rodrigues Froes,
DMV, MSc., Dr. Med
Vet., Dipl. CBraRVet

HOSPITAL NAME

Catskill Veterinary
Services, PLLC

REFERRING VET

Walker Valley
Veterinary



INVOICE

57482

DATE

3-28-23



PATIENT

Ariel Kidney

SPECIES

Feline

BREED

Domestic Shorthair

SEX

FS

AGE

10 Years, 2 Months

INTERPRETED BY

Tilde Rodrigues Froes,
DMV, MSc., Dr. Med
Vet., Dipl. CBraRVet

HOSPITAL NAME

Catskill Veterinary
Services, PLLC

REFERRING VET

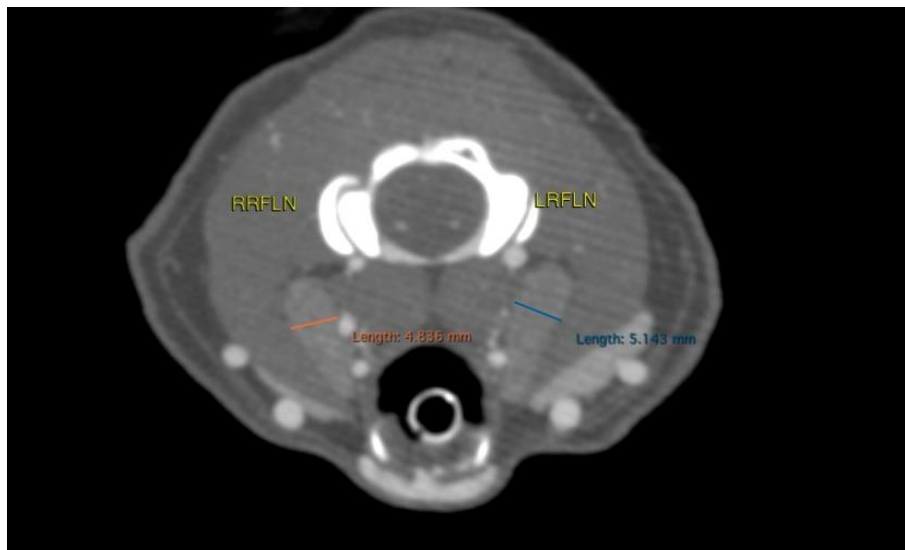
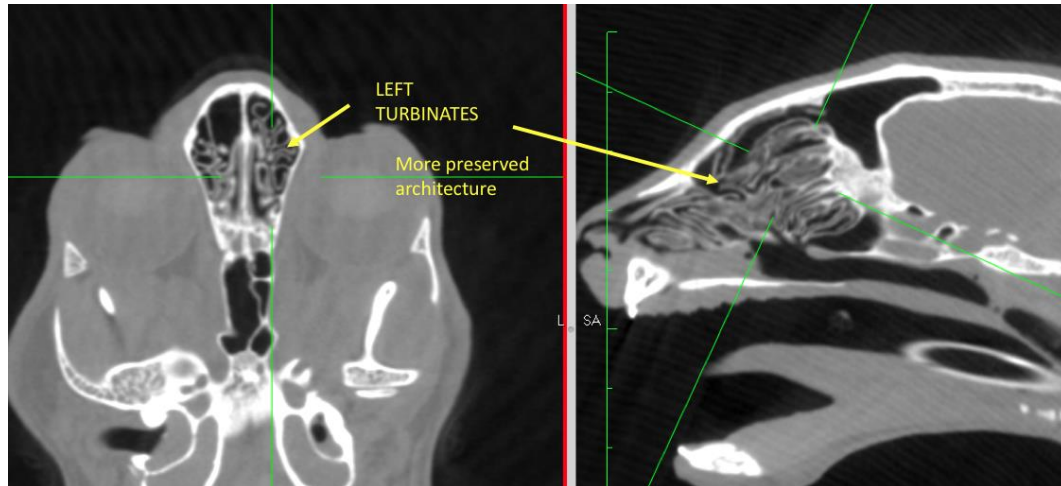
Walker Valley
Veterinary

INVOICE

57482

DATE

3-28-23





PATIENT

Ariel Kidney

SPECIES

Feline

BREED

Domestic Shorthair

SEX

FS

AGE

10 Years, 2 Months

INTERPRETED BY

Tilde Rodrigues Froes,
DMV, MSc., Dr. Med
Vet., Dipl. CBraRVet

HOSPITAL NAME

Catskill Veterinary
Services, PLLC

REFERRING VET

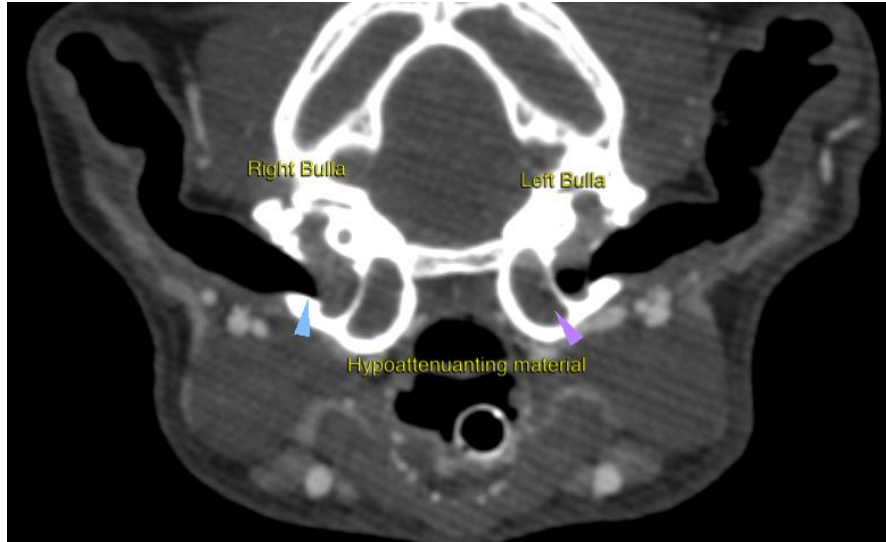
Walker Valley
Veterinary

INVOICE

57482

DATE

3-28-23



The information and recommendations provided are based on the images presented by the referring veterinarian. No evaluation can be communicated regarding pathology that was not visible in the image/video clips provided.

Thank you for this referral. If the clinical or image interpretation does not parallel your findings or if I can be of any further assistance please contact me.

Tilde Rodrigues Froes, DMV, MSc., Dr. Med.Vet., Dipl.CBraRVet
info@sonopath.com