



PATIENT

Diablo Brown

SPECIES

Canine

BREED

GSD

SEX

MN

AGE

3Y

WEIGHT

114

INTERPRETED BY

Tilde Rodrigues Froes,
DMV, MSc., Dr. Med
Vet., Dipl. CBraRVet

IMAGING PERFORMED BY

Russ Lapierre

HOSPITAL NAME

Blandford Animal
Hospital

REFERRING VET

Lapierre Russ

INVOICE

74366

DATE

3-26-26

PRESENTING CLINICAL SIGNS

9 days into doxycycline treatment as part of International Heartworm Society protocol. Clinically act normally

RADIOGRAPHIC STUDY OF THE THORAX

Orthogonal views of the thorax are available for review totaling three images. One ventrodorsal view. One right lateral view. One left lateral view.

RADIOGRAPHIC FINDINGS

The thoracic trachea is normal in diameter and position. The esophagus is not visible, which is within normal limits.

The pulmonary parenchyma is normal in opacity and volume of expansion.

The pulmonary vessels are within normal limits in size and distribution.

The cardiac silhouette is within normal limits in size and shape, spanning approximately 50% of the thoracic width and approximately 3.0 intercostal spaces. Vertebral heart score (VHS) is 9.7 and vertebral left atrial score (VLAS) is 1.9, both within normal limits.

The pleural space and mediastinum are unremarkable.

The diaphragm, thoracic wall, and visible osseous structures are within normal limits.

The included cranial abdomen and collimated musculoskeletal structures are unremarkable.

RADIOGRAPHIC DIAGNOSIS

- No radiographic abnormalities identified in the thorax.

INTERPRETATION OF THE FINDINGS & FURTHER RECOMMENDATIONS

Thoracic radiographs are within normal limits.

Continued clinical monitoring is recommended.



PATIENT

Diablo Brown

SPECIES

Canine

BREED

GSD

SEX

MN

AGE

3Y

WEIGHT

114

INTERPRETED BY

Tilde Rodrigues Froes,
DMV, MSc., Dr. Med
Vet., Dipl. CBraRVet

IMAGING PERFORMED BY

Russ Lapierre

HOSPITAL NAME

Blandford Animal
Hospital

REFERRING VET

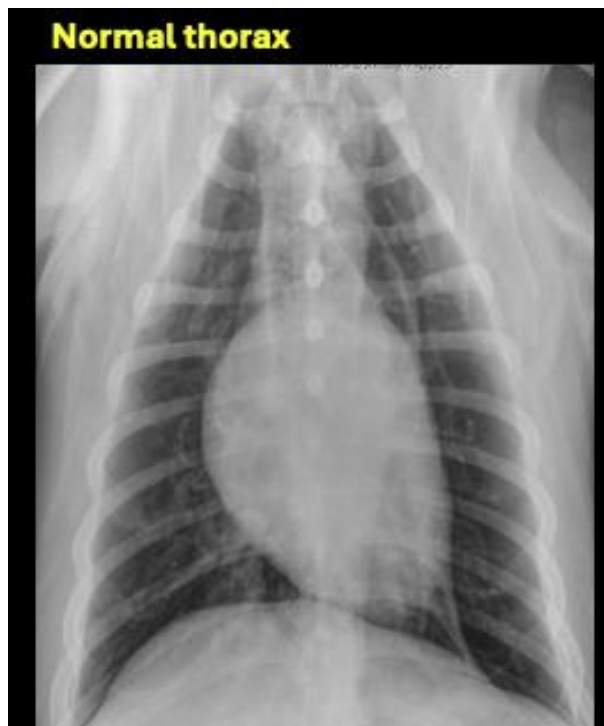
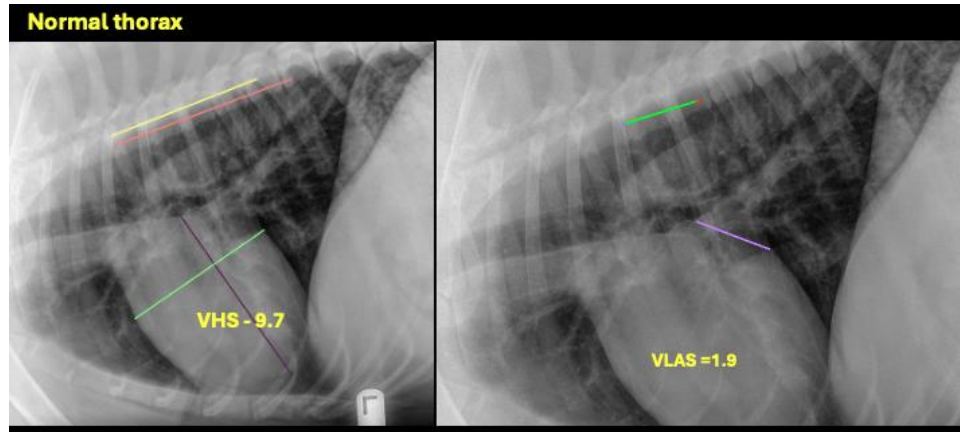
Lapierre Russ

INVOICE

74366

DATE

3-26-26



The information and recommendations provided are based on the images presented by the referring veterinarian. No evaluation can be communicated regarding pathology that was not visible in the image/video clips provided.

Thank you for this referral. If the clinical or image interpretation does not parallel your findings or if I can be of any further assistance, please contact me.

Tilde Rodrigues Froes, DMV, MSc., Dr. Med.Vet., Dipl.CBraRVet
info@sonopath.com