



PATIENT

Molly Wudzinski

SPECIES

Canine

BREED

Aussie Mix

SEX

Female Spayed

AGE

7Y

WEIGHT

42lbs

INTERPRETED BY

Tilde Rodrigues Froes,
DMV, MSc., Dr. Med
Vet., Dipl. CBraRVet

IMAGING PERFORMED BY

Dr. Burge

HOSPITAL NAME

Wilson Veterinary
Hospital

REFERRING VET

Dr. Burge

INVOICE

74348

DATE

3-25-26

PRESENTING CLINICAL SIGNS

- Pet presented on February 7th for unknown head trauma
- Severe facial swelling and deformity present after initial injury, as well as possible fractured teeth
- Pet has recovered from initial trauma but still needs fractured teeth extracted
- CT performed to assess extent of dental/peridental trauma

COMPUTED TOMOGRAPHIC STUDY OF THE HEAD

Pre- and post-contrast CT study of the head, including one pre-contrast bone algorithm series and one post-contrast bone algorithm series.

COMPUTED TOMOGRAPHIC FINDINGS HEAD

There are multifocal chronic fractures involving the facial bones and skull, resulting in mild malalignment and facial asymmetry.

Right side of the face:

Chronic fracture of the rostral portion of the right nasal bone, associated with mild focal bone loss.

Chronic fracture of the retroarticular process of the right temporal bone, associated with right temporomandibular joint (TMJ) subluxation.

Mild depression of the right frontal process of the maxilla.

Alveolar bone loss involving the right maxilla at the level of Triadan 108 and 109.

Left side of the face:

Chronic fracture of the left frontal squamous part of frontal bone, perpendicular to the frontonasal suture, with mild depression.

Orbital asymmetry associated with chronic fractures involving the medial wall of the left orbit, the perpendicular plate of the ethmoid bone, and the left frontal bone.

Chronic fracture of the body of the left maxilla at the level of the greater palatine canal.

Dental / alveolar structures:

Triadan 109 exhibits an abnormal contour of the vestibular enamel surface.

Multifocal alveolar bone resorption is present, most pronounced adjacent to Triadan 108, 109, 309, and 310.

Displacement of the prosthion (interincisive suture) is noted, associated with absence of Triadan 101, 102, and 201.



PATIENT

Molly Wudzinski

SPECIES

Canine

BREED

Aussie Mix

SEX

Female Spayed

AGE

7Y

WEIGHT

42lbs

INTERPRETED BY

Tilde Rodrigues Froes,
DMV, MSc., Dr. Med
Vet., Dipl. CBraRVet

IMAGING PERFORMED BY

Dr. Burge

HOSPITAL NAME

Wilson Veterinary
Hospital

REFERRING VET

Dr. Burge

INVOICE

74348

DATE

3-25-26

Triadan 110, 209, 210, and 409 are also absent.

Other structures:

Within the nasal cavity, there is mild asymmetry of the turbinate detail, characterized by mild focal loss of turbinate architecture in the mid-rostral right nasal cavity adjacent to the chronic nasal and frontal fractures. No intranasal fluid accumulation is identified.

The cribriform plate is intact.

The cranial nasopharynx is within normal limits.

The frontal sinuses are asymmetrical but air-filled.

The globes are within normal limits. No retrobulbar mass effect or fat stranding is identified, despite the adjacent chronic fractures and left-sided orbital asymmetry.

No intracranial mass effect or falx cerebri shift is identified.

The tympanic cavities and external auditory canals are within normal limits.

The left temporomandibular joint is congruent.

The medial retropharyngeal and mandibular lymph nodes are unremarkable.

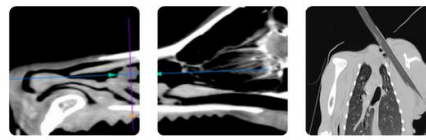
The mandibular, parotid, and zygomatic salivary glands are unremarkable.

COMPUTED TOMOGRAPHIC DIAGNOSIS

- Multifocal chronic maxillofacial and calvarial fractures, involving the right nasal bone, right retroarticular process of the temporal bone, left frontal squamous part of left frontal bone, medial wall of the left orbit, left perpendicular plate of the ethmoid bone, body of the left maxilla at the level of the greater palatine canal. These changes are associated with mild facial asymmetry and malalignment.
- Right temporomandibular joint subluxation, associated with chronic fracture of the retroarticular process of the right temporal bone.
- Multifocal dentoalveolar trauma, characterized by: Alveolar bone loss/resorption most pronounced adjacent to Triadan 108, 109, 309, and 310.
- Displacement of the prosthion and interincisive suture adjacent the absent Triadan 101, 102, 201.
- Multiple absent teeth (Triadan 101, 102, 201, 110, 209, 210, and 409)
- Triadan 109 exhibits an abnormal contour of the vestibular enamel surface, likely healing process of possible previous traumatic fracture.
- Mild focal chronic post-traumatic change within the right rostral nasal cavity, with mild loss of turbinate detail adjacent to the chronic nasal fracture.

INTERPRETATION OF THE FINDINGS & FURTHER RECOMMENDATIONS

The CT findings are consistent with chronic healed or healing multifocal maxillofacial trauma, with residual osseous deformity and mild malalignment affecting both sides of the face. The most clinically relevant residual traumatic changes include the right retroarticular process of the temporal bone right fracture and concurrent TMJ subluxation.



PATIENT

Molly Wudzinski

SPECIES

Canine

BREED

Aussie Mix

SEX

Female Spayed

AGE

7Y

WEIGHT

42lbs

INTERPRETED BY

Tilde Rodrigues Froes, DMV, MSc., Dr. Med Vet., Dipl. CBraRVet

IMAGING PERFORMED BY

Dr. Burge

HOSPITAL NAME

Wilson Veterinary Hospital

REFERRING VET

Dr. Burge

INVOICE

74348

DATE

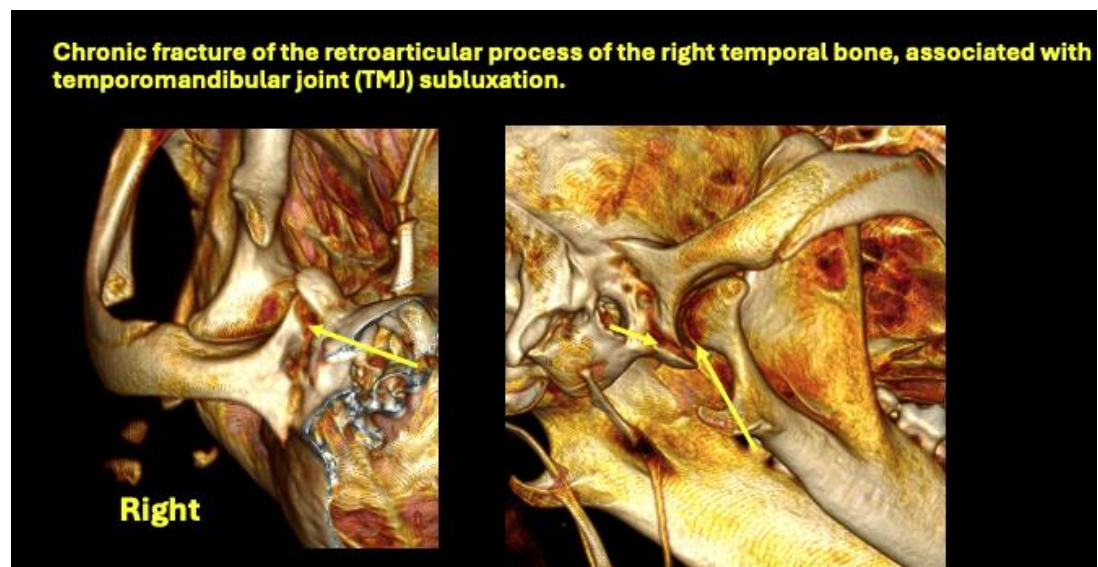
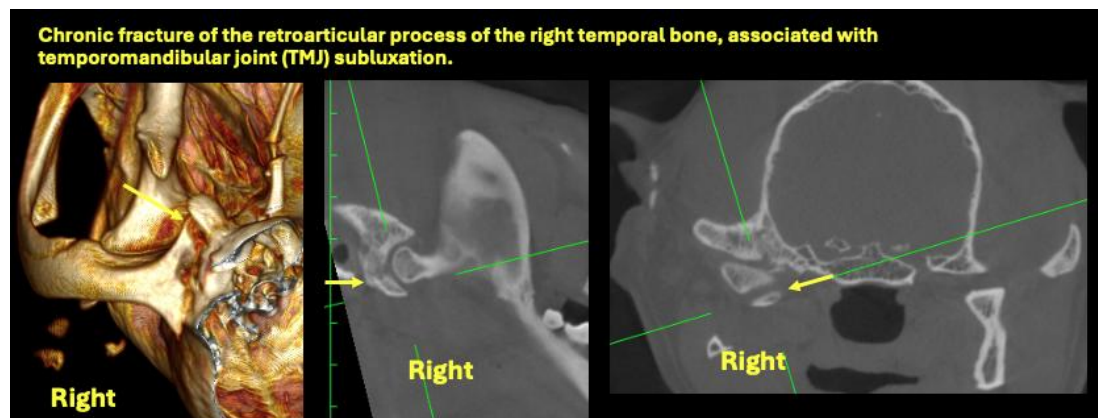
3-25-26

The dentoalveolar abnormalities are compatible with possible prior traumatic injury and likely correlate with the patient's history of fractured teeth. In particular, Triadan 109 exhibits an abnormal contour of the vestibular enamel surface, most consistent with a chronic/healing post-traumatic change. No CT evidence of ongoing abscessation, retrobulbar extension, or intracranial complication is identified on this study.

Correlation with a comprehensive anesthetized oral and dental examination is recommended.

TECHNICAL COMMENTS

Mild oblique patient positioning during image acquisition somewhat limits ideal symmetry assessment and may reduce sensitivity for detection of subtle traumatic changes, despite careful multiplanar review and image reprocessing during interpretation. Additionally, given the multifocal distribution and multiplicity of small maxillofacial traumatic abnormalities, the presence of additional subtle lesions cannot be entirely excluded.





PATIENT

Molly Wudzinski

SPECIES

Canine

BREED

Aussie Mix

SEX

Female Spayed

AGE

7Y

WEIGHT

42lbs

INTERPRETED BY

Tilde Rodrigues Froes,
DMV, MSc., Dr. Med
Vet., Dipl. CBraRVet

IMAGING PERFORMED BY

Dr. Burge

HOSPITAL NAME

Wilson Veterinary
Hospital

REFERRING VET

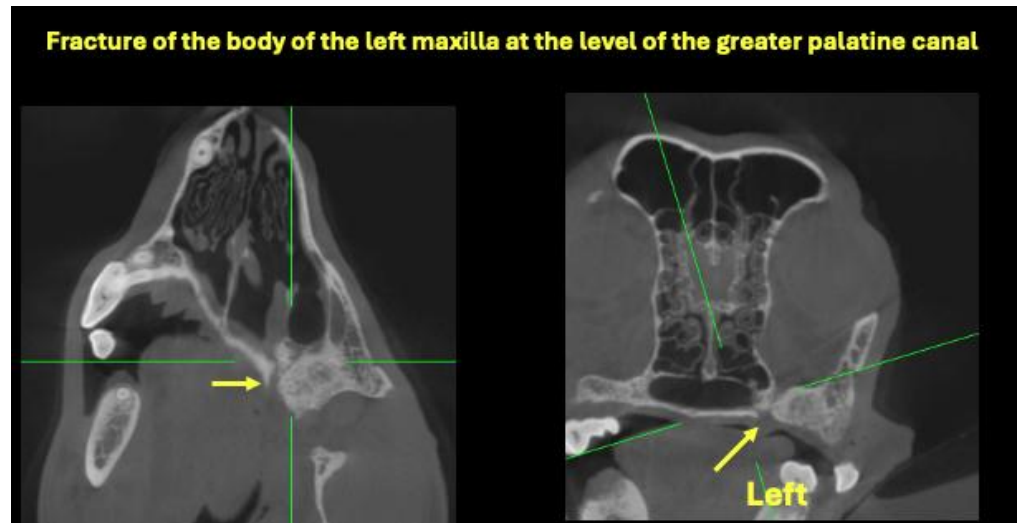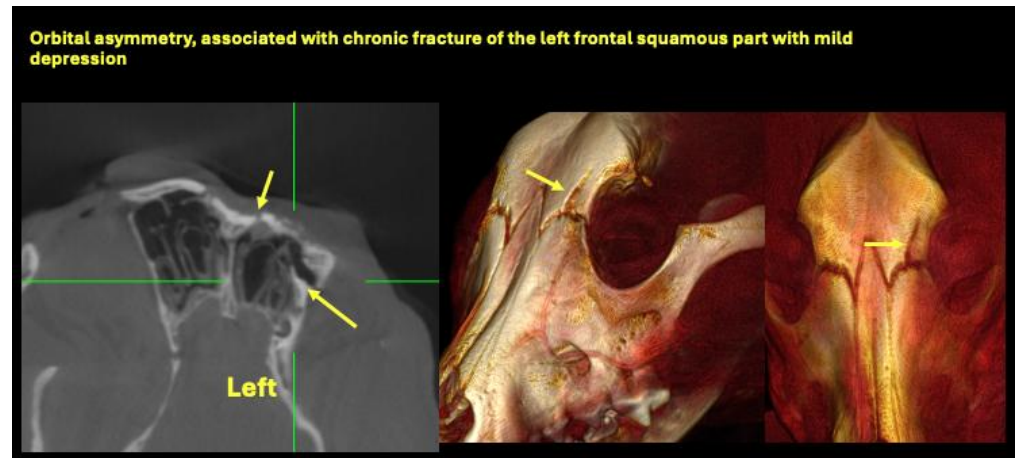
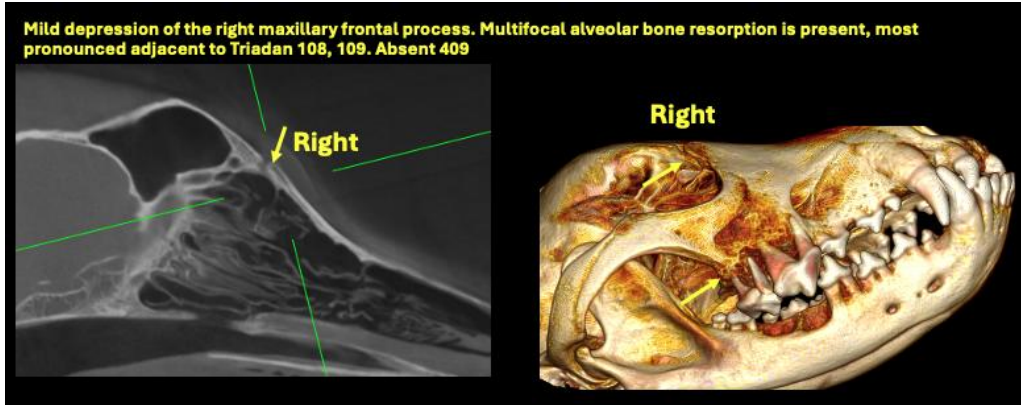
Dr. Burge

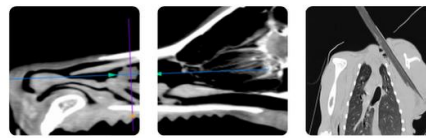
INVOICE

74348

DATE

3-25-26





PATIENT

Molly Wudzinski

SPECIES

Canine

BREED

Aussie Mix

SEX

Female Spayed

AGE

7Y

WEIGHT

42lbs

INTERPRETED BY

Tilde Rodrigues Froes,
DMV, MSc., Dr. Med
Vet., Dipl. CBraRVet

IMAGING PERFORMED BY

Dr. Burge

HOSPITAL NAME

Wilson Veterinary
Hospital

REFERRING VET

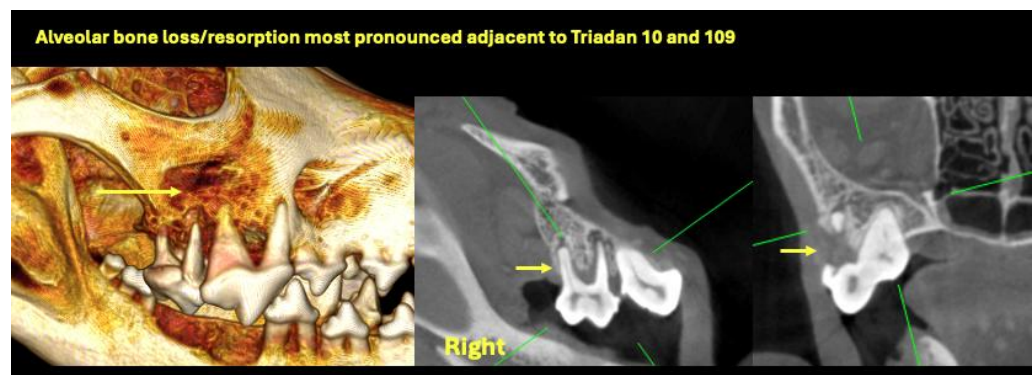
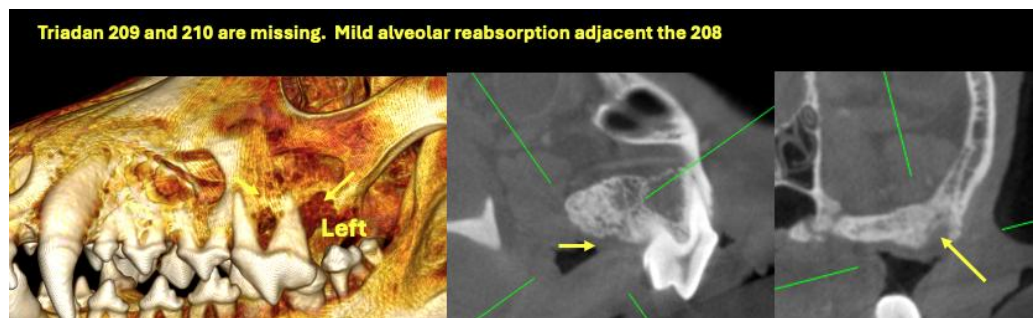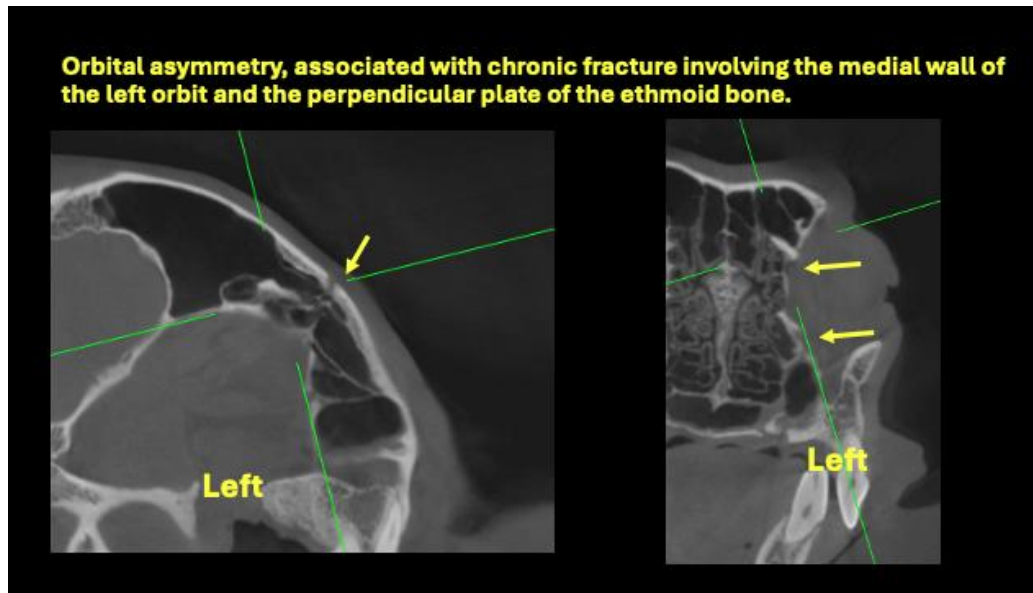
Dr. Burge

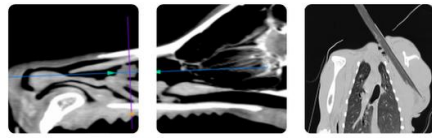
INVOICE

74348

DATE

3-25-26





PATIENT

Molly Wudzinski

SPECIES

Canine

BREED

Aussie Mix

SEX

Female Spayed

AGE

7Y

WEIGHT

42lbs

INTERPRETED BY

Tilde Rodrigues Froes,
DMV, MSc., Dr. Med
Vet., Dipl. CBraRVet

IMAGING PERFORMED BY

Dr. Burge

HOSPITAL NAME

Wilson Veterinary
Hospital

REFERRING VET

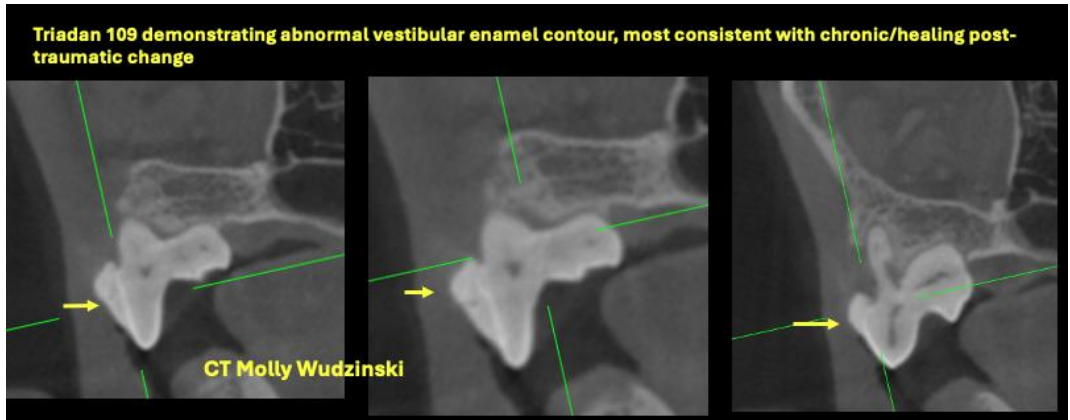
Dr. Burge

INVOICE

74348

DATE

3-25-26



The information and recommendations provided are based on the images presented by the referring veterinarian. No evaluation can be communicated regarding pathology that was not visible in the image/video clips provided.

Thank you for this referral. If the clinical or image interpretation does not parallel your findings or if I can be of any further assistance, please contact me.

Tilde Rodrigues Froes, DMV, MSc., Dr. Med.Vet., Dipl.CBraRVet
info@sonopath.com