



PATIENT

Abilene Luipia

SPECIES

Canine

BREED

Mix

SEX

FS

AGE

7

WEIGHT

22.7kg

INTERPRETED BY

Tilde Rodrigues Froes,
DMV, MSc., Dr. Med
Vet., Dipl. CBraRVet

IMAGING PERFORMED BY

Dr. Runde

HOSPITAL NAME

Northeast Veterinary
Referral Hospital

REFERRING VET

Dr. Runde

INVOICE

74360

DATE

3-25-26

PRESENTING CLINICAL SIGNS

- presented for not eating and diarrhea. hx of a heart murmur. suspected SI mass and mesenteric lymphadenopathy

Abnormal PE/Chem/CBC/UA Results: albumin 1.7

COMPUTED TOMOGRAPHIC STUDY OF THE THORAX AND ABDOMEN

A pre- and post-contrast CT study of the thorax and abdomen is provided for review totaling 3 series. One pre-contrast series of the abdomen (soft tissue algorithm). One post-contrast series of the abdomen (soft tissue algorithm), and one post-contrast series of the thorax (soft tissue algorithm).

COMPUTED TOMOGRAPHIC FINDINGS

ABDOMEN

The stomach is mildly distended, containing homogeneous hypoattenuating fluid material and gas. It is in normal position. No evidence of gastric mural thickening is identified. The cardia is within normal limits.

There is multifocal, diffuse intestinal mural thickening, affecting at least two distinct intestinal segments. One more extensive lesion is identified in the mid-abdominal intestinal tract, characterized by circumferential mural thickening without appreciable post-contrast enhancement, measuring approximately 4.1 cm in length and 1.1 cm in thickness. A second, more peripheral lesion is also identified, measuring approximately 3.5 cm in length and 0.9 cm in thickness. Additionally, there is mild loss of mural definition involving the distal duodenum; however, this segment is completely collapsed/non-distended, limiting detailed assessment.

The cecum and colon contain a mild amount of heterogeneous fecal material and gas. No significant mural abnormality is identified.

The hepatic and jejunal mesenteric lymph nodes are moderately to severely enlarged, rounded, and hypoattenuating. The largest jejunal mesenteric lymph node measures approximately 7.5 × 2.9 cm. The right medial iliac lymph node is also mildly enlarged. The remaining abdominal lymph nodes are within normal limits.

The liver is homogeneously soft tissue attenuating and uniformly contrast-enhancing, with normal size and shape. The gallbladder, cystic duct, and common bile duct are within normal limits.

The kidneys are normal in size, shape, and contour. Multifocal triangular to amorphous hypoattenuating cortical lesions are identified in both kidneys on the post-contrast series. The renal pelvises and ureters are within normal limits.

The urinary bladder is moderately distended with homogeneous hypoattenuating fluid material. Wall thickness is within normal limits.

The spleen is homogeneously soft tissue attenuating and uniformly contrast-enhancing, with normal size and shape.

The pancreas and adrenal glands are within normal limits.

The serosal fat shows normal attenuation. There is no evidence of peritoneal effusion or peritonitis.



PATIENT

Abilene Luipia

SPECIES

Canine

BREED

Mix

SEX

FS

AGE

7

WEIGHT

22.7kg

INTERPRETED BY

Tilde Rodrigues Froes,
DMV, MSc., Dr. Med
Vet., Dipl. CBraRVet

IMAGING PERFORMED BY

Dr. Runde

HOSPITAL NAME

Northeast Veterinary
Referral Hospital

REFERRING VET

Dr. Runde

INVOICE

74360

DATE

3-25-26

The uterus and ovaries are not visualized, consistent with prior ovariohysterectomy.

Multifocal thoracic and lumbar spondylosis deformans is noted, including T7-8, T8-9, T12-13, L1-2, and L7-S1, with incomplete and complete bridging ventral endplate osteophytes.

THORAX

The trachea and main bronchi are within normal limits.

The sternal, cranial mediastinal, and tracheobronchial lymph nodes are unremarkable.

There are scattered hyperattenuating mineral foci in the subpleural pulmonary parenchyma, compatible with pulmonary osteomas. The remaining pulmonary parenchyma demonstrates normal attenuation, with no evidence of pulmonary micronodules, nodules, or masses.

The bronchial tree exhibits normal branching and tapering. Bronchial walls are thin and smooth, with a normal bronchus-to-artery ratio.

The cardiac silhouette and pulmonary vessels are within normal limits. Post-contrast vascular and cardiac chamber opacification is adequate.

The pleural space, diaphragm, and thoracic wall are unremarkable.

The thoracic esophagus is unremarkable.

COMPUTED TOMOGRAPHIC DIAGNOSIS

- Multifocal intestinal mural thickening, affecting at least two intestinal segments, including one more extensive mid-abdominal lesion and a second smaller peripheral lesion, with additional questionable distal duodenal mural abnormality. Differential diagnoses include intestinal neoplasia (particularly lymphoma, or other infiltrative neoplasms), less likely severe inflammatory/infiltrative enteropathy.
- Moderate to severe enlargement of the hepatic and jejunal mesenteric lymph nodes, with mild enlargement of the right medial iliac lymph node. Findings are most concerning for metastatic or multicentric lymphadenopathy, although marked reactive lymphadenitis remains a differential.
- Multifocal bilateral renal cortical hypoattenuating lesions visible on post-contrast images. Differential diagnoses include renal infarcts, less likely lymphomatous/neoplastic infiltration.
- Scattered subpleural mineralized pulmonary foci, most consistent with incidental pulmonary osteomas. No evidence of metastatic pulmonary nodules.
- Multifocal thoracolumbar spondylosis deformans.

INTERPRETATION OF THE FINDINGS & FURTHER RECOMMENDATIONS

The most clinically significant abnormalities are the multifocal intestinal mural lesions associated with marked abdominal lymphadenomegaly. Given this combination of findings, the primary differential diagnoses include an infiltrative intestinal disease process, particularly intestinal lymphoma and other neoplastic conditions, while severe inflammatory disease is considered less likely.



PATIENT

Abilene Luipia

Recommend ultrasound-guided FNA or biopsy of the enlarged abdominal lymph nodes. Alternatively, exploratory surgery with intestinal biopsy and/or enterectomy may be considered for definitive diagnosis.

SPECIES

Canine

The multifocal renal cortical hypoattenuating lesions are considered most compatible with renal infarctions. Differential diagnoses include less likely renal infiltration and inflammatory renal disease

BREED

Mix

The thoracic study demonstrates scattered incidental subpleural mineralized foci, compatible with pulmonary osteomas. No evidence of pulmonary metastatic disease is identified.

SEX

FS

AGE

7

WEIGHT

22.7kg

INTERPRETED BY

Tilde Rodrigues Froes,
DMV, MSc., Dr. Med
Vet., Dipl. CBraRVet

IMAGING PERFORMED BY

Dr. Runde

HOSPITAL NAME

Northeast Veterinary
Referral Hospital

REFERRING VET

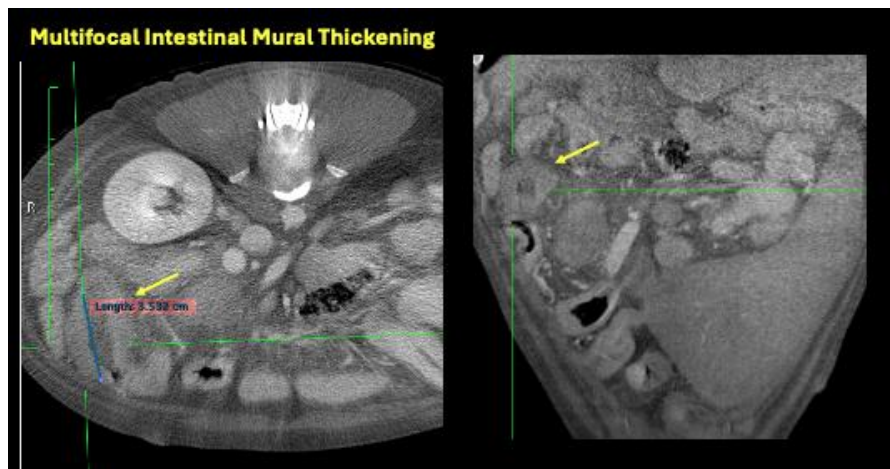
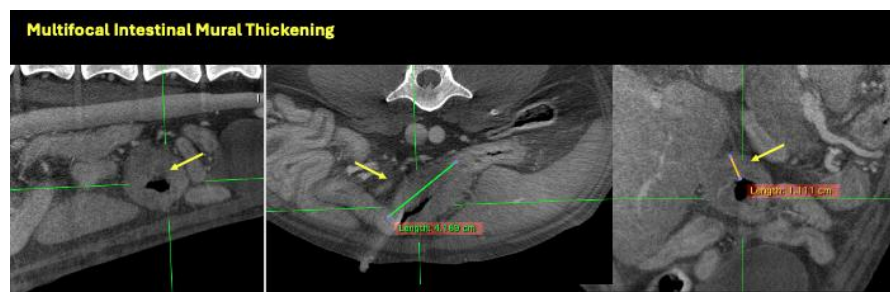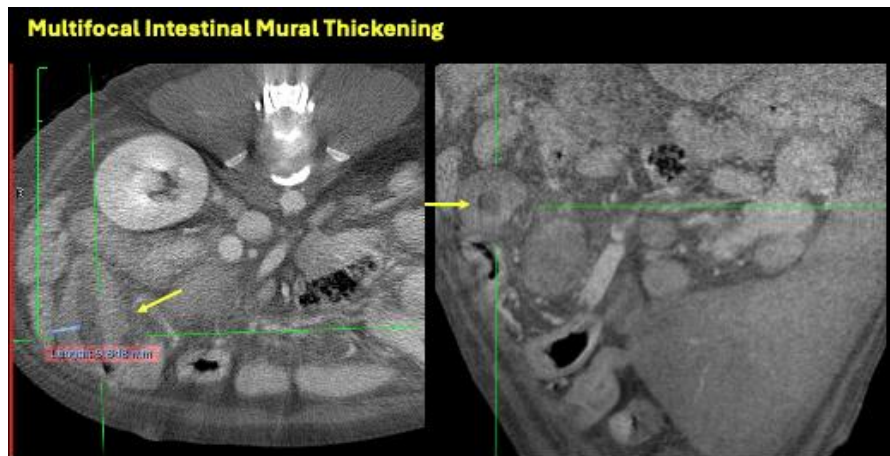
Dr. Runde

INVOICE

74360

DATE

3-25-26





PATIENT

Abilene Luipia

SPECIES

Canine

BREED

Mix

SEX

FS

AGE

7

WEIGHT

22.7kg

INTERPRETED BY

Tilde Rodrigues Froes,
DMV, MSc., Dr. Med
Vet., Dipl. CBraRVet

IMAGING PERFORMED BY

Dr. Runde

HOSPITAL NAME

Northeast Veterinary
Referral Hospital

REFERRING VET

Dr. Runde

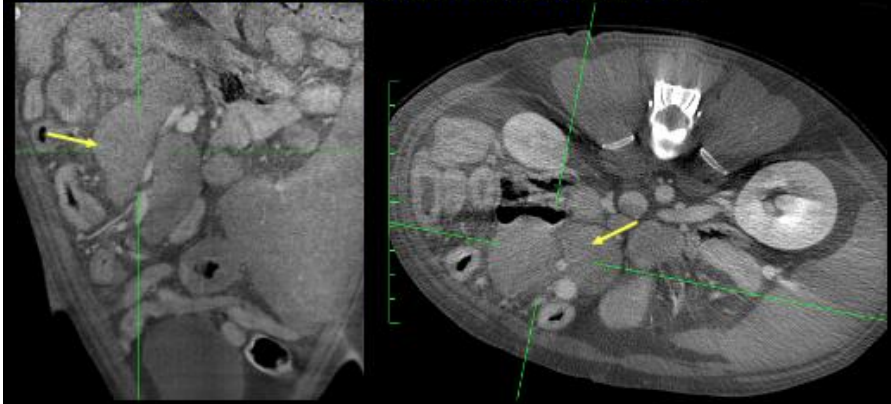
INVOICE

74360

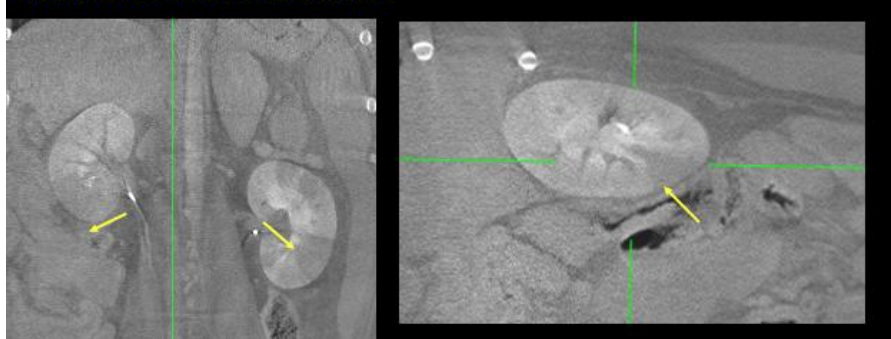
DATE

3-25-26

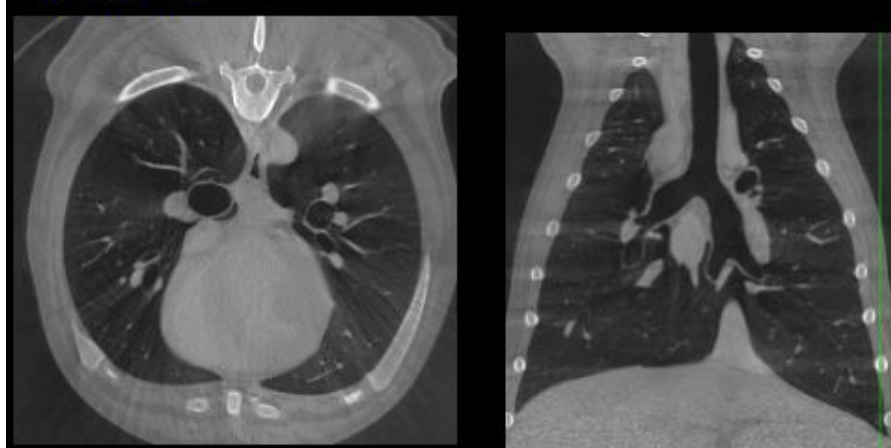
Marked Enlargement of the Jejunal Mesenteric Lymph Nodes



Multifocal Renal Cortical Infarctions



Normal thorax





PATIENT

Abilene Luipia

SPECIES

Canine

BREED

Mix

SEX

FS

AGE

7

WEIGHT

22.7kg

INTERPRETED BY

Tilde Rodrigues Froes,
DMV, MSc., Dr. Med
Vet., Dipl. CBraRVet

IMAGING PERFORMED BY

Dr. Runde

HOSPITAL NAME

Northeast Veterinary
Referral Hospital

REFERRING VET

Dr. Runde

INVOICE

74360

DATE

3-25-26

The information and recommendations provided are based on the images presented by the referring veterinarian. No evaluation can be communicated regarding pathology that was not visible in the image/video clips provided.

Thank you for this referral. If the clinical or image interpretation does not parallel your findings or if I can be of any further assistance, please contact me.

Tilde Rodrigues Froes, DMV, MSc., Dr. Med.Vet., Dipl.CBraRVet
info@sonopath.com