



PATIENT PRESENTING CLINICAL SIGNS

Winston Aklia has hx of collapsing trachea, eating less than usual when he gets excited he coughs and chokes. He has bad anxiety.
 Abnormal PE/Chem/CBC/UA Results: chem: mild alp elevation grade 2 heart murmur

SPECIES

Canine

RADIOGRAPHIC STUDY OF THE THORAX

Orthogonal views of the thorax are provided for review. Two right lateral, one left lateral and one ventrodorsal view. The ventrodorsal view is moderately oblique.

BREED

Pomeranian

RADIOGRAPHIC FINDINGS

Between the lateral views, the air column height of the cervical and cranial intrathoracic trachea is variable, overdistended, and narrowed.

SEX

MN

An overdistension of the pharynx is also evident.

AGE

13 Years

The cervical and thoracic esophagus is mild to moderately distended by gas, and a tracheal stripe sign is seen.

The cardiac silhouette spans approximately 60% of the thoracic width, 3.0 intercostal spaces, and is normal in shape. The cardiac silhouette is rotated and dislocated to the left hemithorax, and it is correlated to obliquity positional artifact.

INTERPRETED BY

Tilde Rodrigues Froes, DMV, MSc., Dr. Med Vet., Dipl. CBraRVet

A mild diffuse unstructured interstitial and bronchial pulmonary pattern is noted. The pulmonary parenchyma is variably atelectatic.

The pleural space and mediastinum are normal.

On the collimated abdomen:

HOSPITAL NAME

CJAH

The liver is moderately enlarged with elongated bulbous margins, displacing the gastric axis caudally.

Abundant fat stores are seen in the subcutaneous tissues and cranial abdomen.

C3-C4, C5-C5, and C6-C7 mild spondylosis deformans is noted.

REFERRING VET

Gabriel

No other abnormalities are identified.

RADIOGRAPHIC DIAGNOSIS

INVOICE

57398

DATE

3-23-23

- Dynamic tracheal collapse and overdistention correlated to severe dyspnea.
- Overdistention of the nasopharynx is correlated to severe dyspnea and airway obstruction due to tracheal collapse.
- Generalized hepatic enlargement, differential diagnosis includes secondary to metabolic (e.g. diabetes mellitus, or hyperadrenocorticism), inflammatory, or infiltrative disease.
- Esophageal aerophagy. Differential diagnosis includes esophageal reflux.
- Mild unstructured interstitial pulmonary pattern. Differential diagnosis includes mild lower



PATIENT airway inflammatory/infectious disease or correlated to passive atelectasis.

Winston Aklian

- Normal heart and pulmonary vasculature size.
- C3-C4, C5-C5 and C6-C7 spondylosis deformans, incidental
- Excessive body condition score.

SPECIES INTERPRETATION OF THE FINDINGS & FURTHER RECOMMENDATIONS

Canine

Dynamic tracheal collapse and overdistention correlates to severe dyspnea and is correlated to the patient history. The variable tracheal and nasopharynx overdistention could be correlated to excitement, anxiety, and/or respiratory distress.

BREED

Abdominal ultrasound may be useful in further evaluation of the liver.

Pomeranian

Present murmur with normal radiographic heart, consider cardiac disease at a stage not producing secondary radiographic changes. Echocardiogram may be recommended for further evaluation of cardiac structure and function.

SEX

MN

AGE

13 Years

INTERPRETED BY

Tilde Rodrigues Froes,
DMV, MSc., Dr. Med
Vet., Dipl. CBraRVet

HOSPITAL NAME

CJAH

REFERRING VET

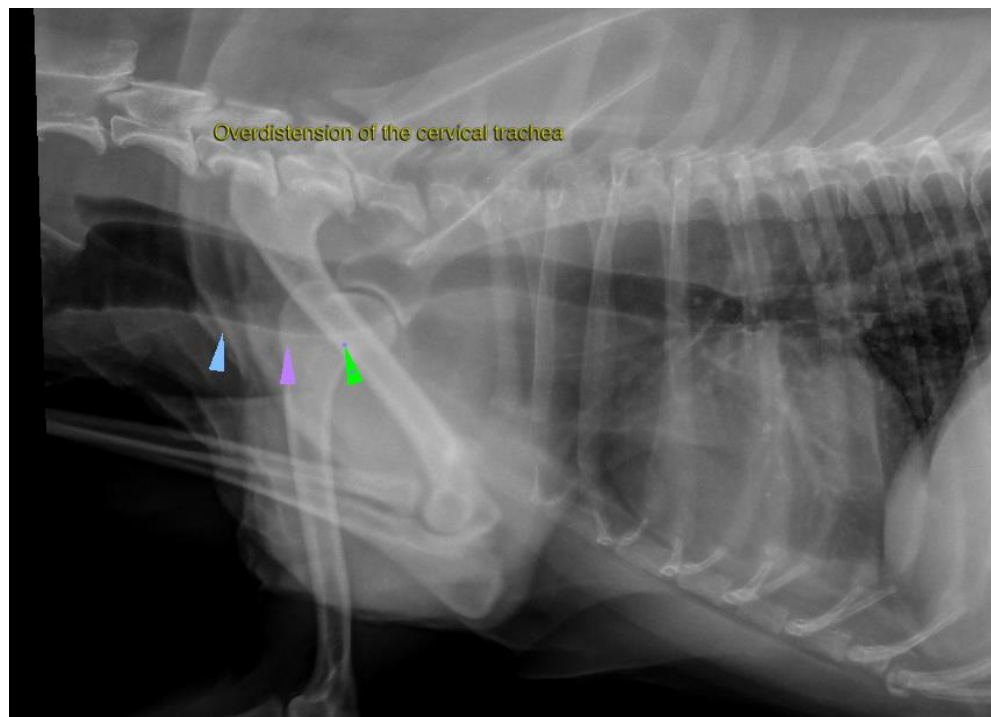
Gabriel

INVOICE

57398

DATE

3-23-23





PATIENT

Winston Aklian

SPECIES

Canine

BREED

Pomeranian

SEX

MN

AGE

13 Years

INTERPRETED BY

Tilde Rodrigues Froes,
DMV, MSc., Dr. Med
Vet., Dipl. CBraRVet

HOSPITAL NAME

CJAH

REFERRING VET

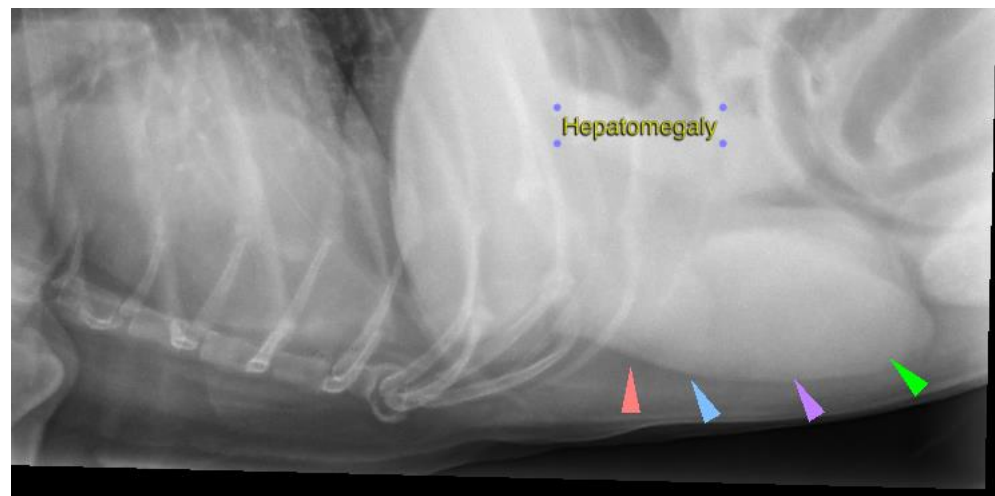
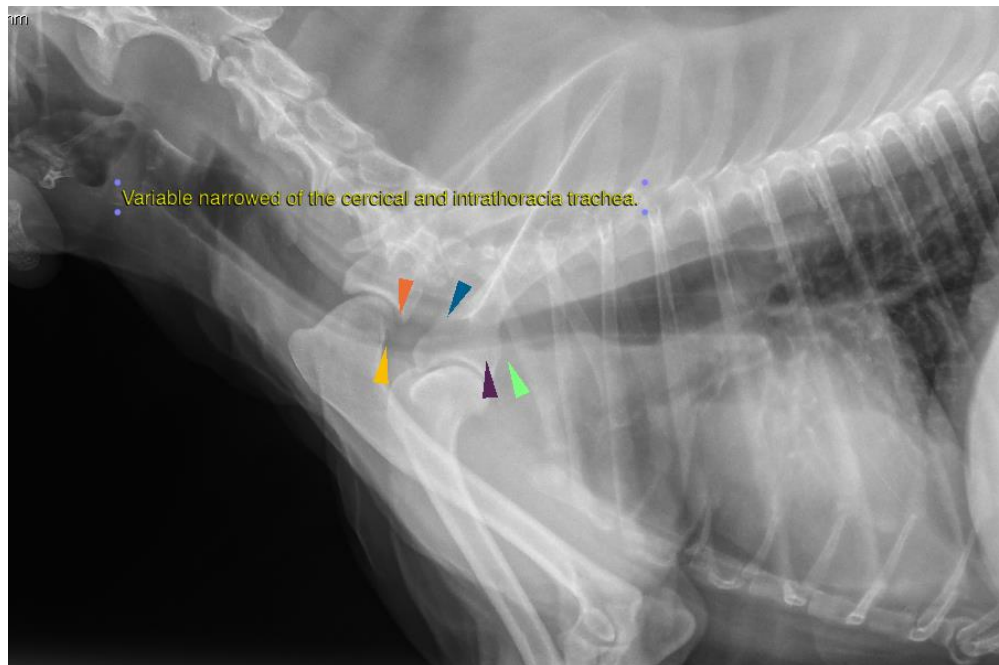
Gabriel

INVOICE

57398

DATE

3-23-23





PATIENT

Winston Aklian

The information and recommendations provided are based on the images presented by the referring veterinarian. No evaluation can be communicated regarding pathology that was not visible in the image/video clips provided.

SPECIES

Canine

Thank you for this referral. If the clinical or image interpretation does not parallel your findings or if I can be of any further assistance please contact me.

Tilde Rodrigues Froes, DMV, MSc., Dr. Med.Vet., Dipl.CBraRVet
info@sonopath.com

BREED

Pomeranian

SEX

MN

AGE

13 Years

INTERPRETED BY

Tilde Rodrigues Froes,
DMV, MSc., Dr. Med
Vet., Dipl. CBraRVet

HOSPITAL NAME

CJAH

REFERRING VET

Gabriel

INVOICE

57398

DATE

3-23-23