



PATIENT PRESENTING CLINICAL SIGNS

Rocky Oliveira presented with fever and no appetite
 Abnormal PE/Chem/CBC/UA Results: Bloodwork: band neutrophils leukopenia neutropenia lymphopenia monocytosis UA: blood 250 ery/ul

SPECIES

Canine

RADIOGRAPHIC STUDY OF THE THORAX AND ABDOMEN

Orthogonal views of the thorax and abdomen are available for review totaling 3 images. Two lateral views of the abdomen and one lateral view of the thorax.

BREED

Golden Doodle

RADIOGRAPHIC FINDINGS

ABDOMEN

The liver and spleen are normal in size, shape, and contour.

SEX

MN

The stomach contains a moderate amount of gas admixed with homogeneous soft tissue opaque fluid material, which redistributes with the patient position.

AGE

5 Years

The small intestines are normally distributed, of normal diameter, contain a moderate amount of gas and homogeneous soft tissue fluid material.

The colon contains a small amount of heterogeneous opaque fecal material and gas.

The abdominal serosal detail is normal. The retroperitoneal space is normal.

INTERPRETED BY

Tilde Rodrigues Froes, DMV, MSc., Dr. Med Vet., Dipl. CBraRVet

The left renal silhouette is more clearly visible, and it is unremarkable. The right renal silhouette is partially visible, unremarkable at this portion.

The urinary bladder is moderately filled with the apex in the plane of cranial L6 and is homogeneously soft tissue opaque. No radiopaque calculi are seen.

HOSPITAL NAME

The Collegeway Animal Hospital

THORAX

The trachea is normal.

The cardiac silhouette, pulmonary vasculature, and parenchyma are normal.

REFERRING VET

Dr Ehab Hanna

The pleural space and mediastinum are normal.

No evidence of soft tissue opaque pulmonary nodules or abnormal intrathoracic lymph nodes.

The thoracic wall and ribs are normal.

INVOICE

57364

The musculoskeletal structures are unremarkable.

DATE

3-22-23

RADIOGRAPHIC DIAGNOSIS

- Normal thorax and abdomen.



PATIENT INTERPRETATION OF THE FINDINGS & FURTHER RECOMMENDATIONS

Rocky Oliveira

No evidence of radiographic findings were identified to correlate with the clinical signs. No evidence of bronchopneumonia or other abnormalities that could be correlated to fever and no appetite. If clinical signs persist, an abdominal ultrasound is suggested for further evaluation.

SPECIES

Canine

BREED

Golden Doodle

SEX

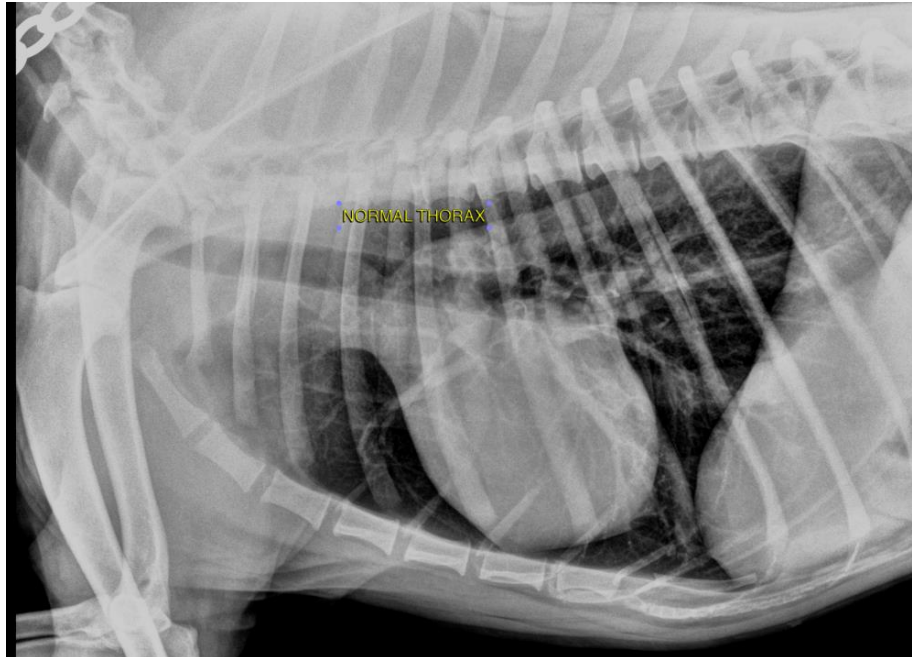
MN

AGE

5 Years

INTERPRETED BY

Tilde Rodrigues Froes,
DMV, MSc., Dr. Med
Vet., Dipl. CBraRVet



HOSPITAL NAME

The Collegeway
Animal Hospital

REFERRING VET

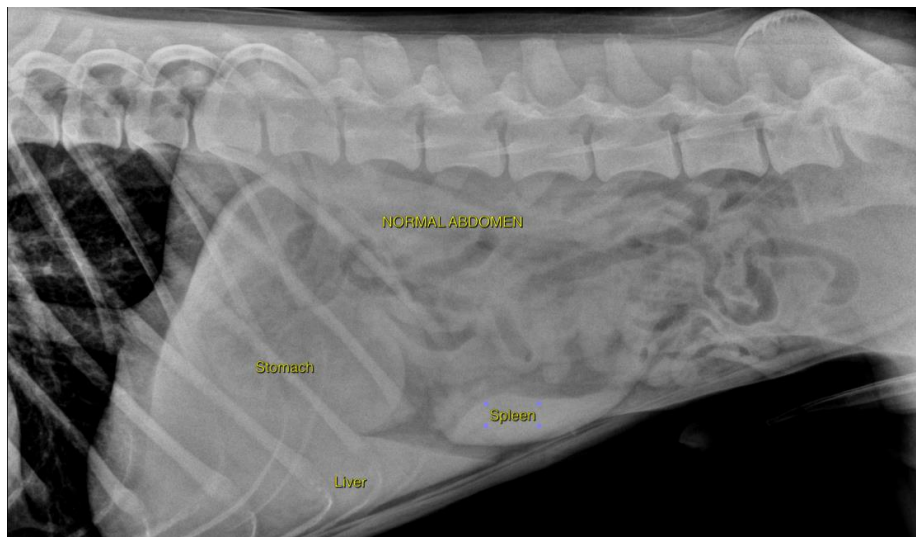
Dr Ehab Hanna

INVOICE

57364

DATE

3-22-23





PATIENT

Rocky Oliveira

The information and recommendations provided are based on the images presented by the referring veterinarian. No evaluation can be communicated regarding pathology that was not visible in the image/video clips provided.

SPECIES

Canine

Thank you for this referral. If the clinical or image interpretation does not parallel your findings or if I can be of any further assistance please contact me.

Tilde Rodrigues Froes, DMV, MSc., Dr. Med.Vet., Dipl.CBraRVet
info@sonopath.com

BREED

Golden Doodle

SEX

MN

AGE

5 Years

INTERPRETED BY

Tilde Rodrigues Froes,
DMV, MSc., Dr. Med
Vet., Dipl. CBraRVet

HOSPITAL NAME

The Collegeway
Animal Hospital

REFERRING VET

Dr Ehab Hanna

INVOICE

57364

DATE

3-22-23