



PATIENT PRESENTING CLINICAL SIGNS

Traeger Petiprin Recently diagnosed HW pos. Chest x-rays prior to treatment. O reports pt doing well, no coughing.

RADIOGRAPHIC STUDY OF THE THORAX

SPECIES
Canine
Orthogonal views of the thorax are provided for review. One right lateral, one left lateral and one ventral dorsal view. Total three images.

RADIOGRAPHIC FINDINGS

BREED
Retriever Mix
The thoracic trachea is normal.

SEX
NM
The cardiac silhouette and pulmonary vasculature are normal. (VHS = 10.1)

AGE
1.5 Years
The mediastinum and pleural space are normal.

The musculoskeletal structures collimated on the field are normal.

The cranial abdomen collimated on the field is normal.

RADIOGRAPHIC DIAGNOSIS

INTERPRETED BY

Tilde Rodrigues Froes,
DMV, MSc., Dr. Med
Vet., Dipl. CBraRVet

- Mild pulmonary interstitial pulmonary pattern and reduced lung expansion. Differential diagnosis includes the expiratory respiratory phase, passive atelectasis, mild eosinophilic bronchitis, correlated to the patient history of positive Heartworm disease.
- Otherwise, normal thorax.

INTERPRETATION OF THE FINDINGS & FURTHER RECOMMENDATIONS

HOSPITAL NAME

The Pet Hospital of
Stratford

The mild interstitial pattern is most likely correlated to respiratory expiratory phase, however, mild eosinophilic bronchitis cannot be excluded as a differential diagnosis, considering the patient history.

Normal heart and pulmonary vasculature sizes.

REFERRING VET

Dr. David

INVOICE

57329

DATE

3-21-23



PATIENT

Traeger Petiprin

SPECIES

Canine

BREED

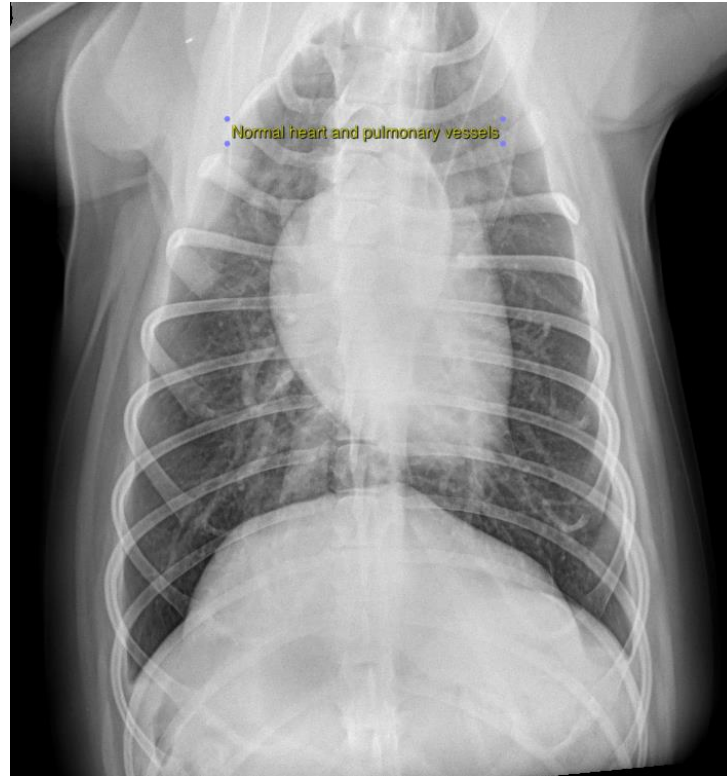Retriever Mix

SEX

NM

AGE

1.5 Years



INTERPRETED BY

Tilde Rodrigues Froes,
DMV, MSc., Dr. Med
Vet., Dipl. CBraRVet

HOSPITAL NAME

The Pet Hospital of
Stratford

REFERRING VET

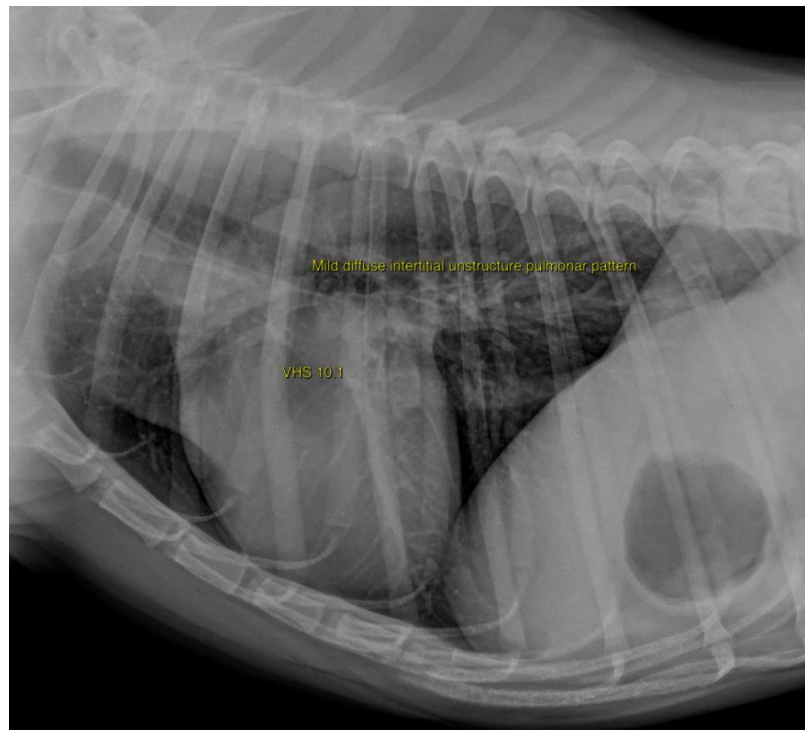
Dr. David

INVOICE

57329

DATE

3-21-23





PATIENT

Traeger Petiprin

The information and recommendations provided are based on the images presented by the referring veterinarian. No evaluation can be communicated regarding pathology that was not visible in the image/video clips provided.

SPECIES

Canine

Thank you for this referral. If the clinical or image interpretation does not parallel your findings or if I can be of any further assistance please contact me.

BREED

Retriever Mix

Tilde Rodrigues Froes, DMV, MSc., Dr. Med.Vet., Dipl.CBraRVet
info@sonopath.com

SEX

NM

AGE

1.5 Years

INTERPRETED BY

Tilde Rodrigues Froes,
DMV, MSc., Dr. Med
Vet., Dipl. CBraRVet

HOSPITAL NAME

The Pet Hospital of
Stratford

REFERRING VET

Dr. David

INVOICE

57329

DATE

3-21-23