



PATIENT PRESENTING CLINICAL SIGNS

Tucker Castillo 2 year history of ongoing ear infections and URI. Currently has a right head tilt and is inappetent.

SPECIES COMPUTED TOMOGRAPHIC STUDY OF THE THORAX AND HEAD

Feline A pre-contrast and post-contrast CT study of the Head and Thorax with collimated abdomen are provided for review. One pre-contrast series and post-contrast series of the head, One pre-contrast series and post-contrast series of the thorax.

BREED COMPUTED TOMOGRAPHIC FINDINGS

DSH HEAD

Expansion with severe hyperostosis and multifocal osteolysis of the tympanic bullae is seen as well as complete filling by predominantly non-contrast hypoattenuating soft tissue fluid material. The expansive effect causes contact of the tympanic bullae with the hyoid apparatus, adjacent muscles, and causes external, extramural, compression of the nasopharynx. Also, a mild hypoattenuating fluid material is seen within the nasopharynx lumen. Thickening of the inner ear and increased ill-defined meningeal enhancement at the level of the vestibular cochlear nerve is seen on the right. Bilaterally, the wall of the horizontal ear canal is mildly thickened within the proximal portion of the horizontal portion.

SEX

Male

AGE

8 Years Mild hypoattenuating fluid accumulation in the nasal cavity is noted bilaterally. The sphenoidal and frontal sinuses are normal.

INTERPRETED BY

Tilde Rodrigues Froes, DMV, MSc., Dr. Med Vet., Dipl. CBraRVet

The retrobulbar spaces are normal.
 The cribriform plate is normal.
 The osseous structures of the calvarium are normal.
 Mild horizontal bone loss throughout the mandibular and maxillary arcades is seen. The triadans 101 and 103 are fractured, with retained root.

HOSPITAL NAME

Animal Surgical Center

The retropharyngeal lymph nodes are moderately enlarged with heterogeneous enhancement. LRFL measures approximately 0.7cm and the RRLF measures approximately 0.8cm in thickness.

The mandibular lymph nodes are normal.

REFERRING VET

East Village Green Hospital

THORAX

The trachea and main bronchus are normal.

INVOICE

57332

There is mild diffuse thickening of the bronchial wall. In addition, a mild multifocal patchy ground glass attenuation is seen at the left cranial lung lobe, in the transition between the cranial and caudal subsegment, and on the left caudal lung lobe. No pulmonary nodules are seen.

The pleural space and mediastinum are normal.

DATE

3-16-23

No evidence of enlarged mediastinal lymph nodes.



PATIENT

Tucker Castillo

The esophagus is moderately diffusely distended by intraluminal gas.
The diaphragm and thoracic wall are normal.

SPECIES

Feline

The musculoskeletal structures are unremarkable.

On the collimated abdomen:

BREED

DSH

The kidneys are normal in size, shape, and attenuation. No mineral calculi are identified. Right kidney is 4.0cm length, left kidney is 4.1cm length.

The spleen is enlarged, homogeneous in attenuation, and with regular borders.

SEX

Male

The urinary bladder is moderately distended, filled with hypoattenuating homogeneous fluid, no mineral calculi is seen. The trigone region and proximal urethra were not collimated.

The stomach is moderately distended, filled with gas, and normal in position.

The colon contains gas admixed with heterogeneously soft tissue attenuating fecal material.

AGE

8 Years

The mesenteric attenuation is normal.

No mass effect is seen.

Abundant fat stores are seen in the subcutaneous tissues, pericardium, and throughout the abdomen.

INTERPRETED BY

Tilde Rodrigues Froes,
DMV, MSc., Dr. Med
Vet., Dipl. CBraRVet

COMPUTED TOMOGRAPHIC DIAGNOSIS

- Severe expansile chronic bilateral otitis media, right side otitis interna.
- Retropharyngeal lymphadenopathy, reactive.
- Mild nondestructive rhinitis.
- Mild diffuse periodontal disease. Fracture at the triadans 101 and 103 with retained root.
- Mild multifocal ground glass alveolar pattern, more left lung lobes, and bronchial wall thickening. Differential diagnosis includes allergic lower airway disease, infectious bronchitis with focal mild bronchopneumonia, and/or concurrent atelectasis.
- Esophageal aerophagy, likely iatrogenic, due to anesthesia procedure. The differential diagnosis esophagitis, less likely acquired megaesophagus.
- No evidence of pulmonary metastatic disease.
- No evidence of enlarged mediastinal lymph nodes.
- Splenomegaly, differential diagnosis includes correlated to anesthesia procedure, lymphoid hyperplasia, hematopoiesis, less likely infiltrative diseases.
- Excessive body condition score.

HOSPITAL NAME

Animal Surgical
Center

REFERRING VET

East Village Green
Hospital

INVOICE

57332

INTERPRETATION OF THE FINDINGS & FURTHER RECOMMENDATIONS

Bilateral severe proliferative and mild osteolytic expansive chronic otitis media and otitis interna on the right side is correlated to the clinical signs and head tilt.

DATE

3-16-23



PATIENT Tucker Castillo
The pulmonary tomographic findings are mild, could indicate an active or non-active bronchial disease. Consider an association with the respiratory clinical findings. If specific respiratory findings such as difficulty breathing, wheezing, and/or coughing, a bronchoalveolar lavage may be useful in obtaining samples for cytology, culture, and sensitivity.

SPECIES TECHNICAL COMMENTS

Feline Motion and noise artifacts are seen in the available series. It can cause interference in the detailed analysis and tomographic interpretation.

BREED

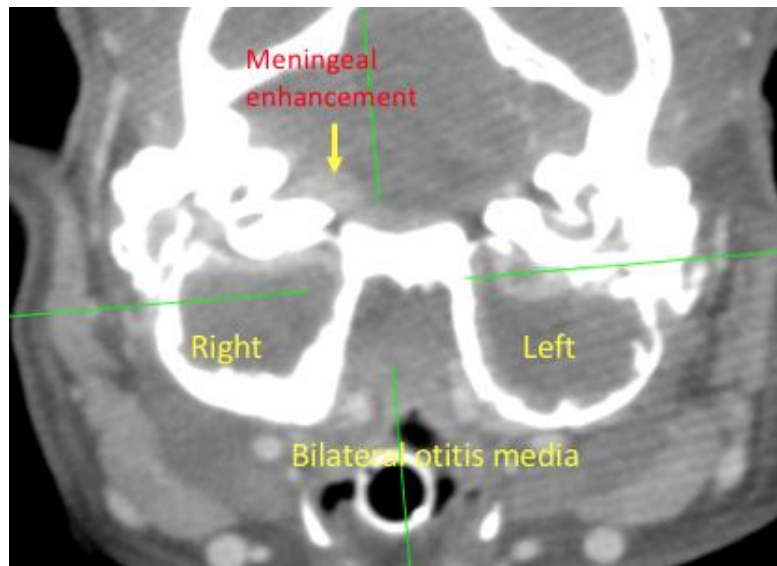
DSH

SEX

Male

AGE

8 Years



INTERPRETED BY

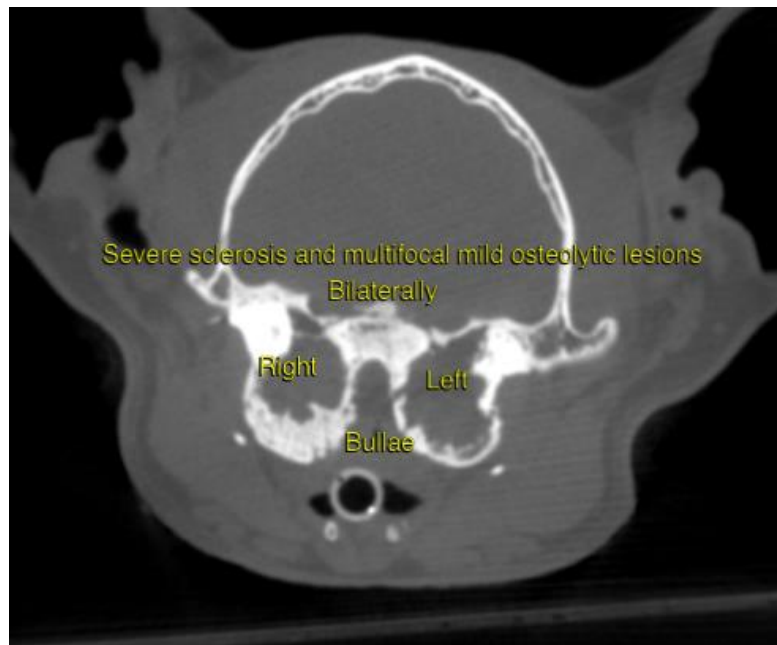Tilde Rodrigues Froes,
DMV, MSc., Dr. Med
Vet., Dipl. CBraRVet

HOSPITAL NAME

Animal Surgical
Center

REFERRING VET

East Village Green
Hospital

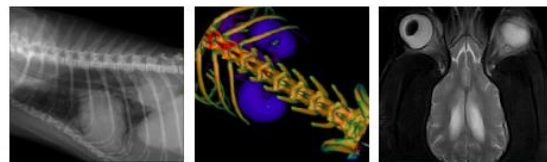


INVOICE

57332

DATE

3-16-23



PATIENT

Tucker Castillo

SPECIES

Feline

BREED

DSH

SEX

Male

AGE

8 Years

INTERPRETED BY

Tilde Rodrigues Froes,
DMV, MSc., Dr. Med
Vet., Dipl. CBraRVet

HOSPITAL NAME

Animal Surgical
Center

REFERRING VET

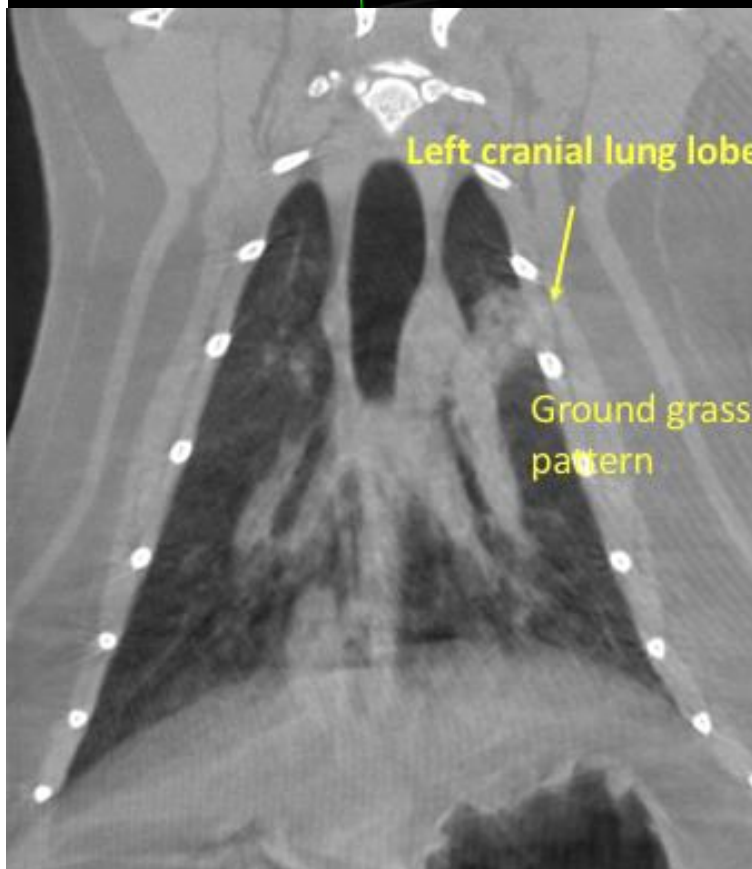
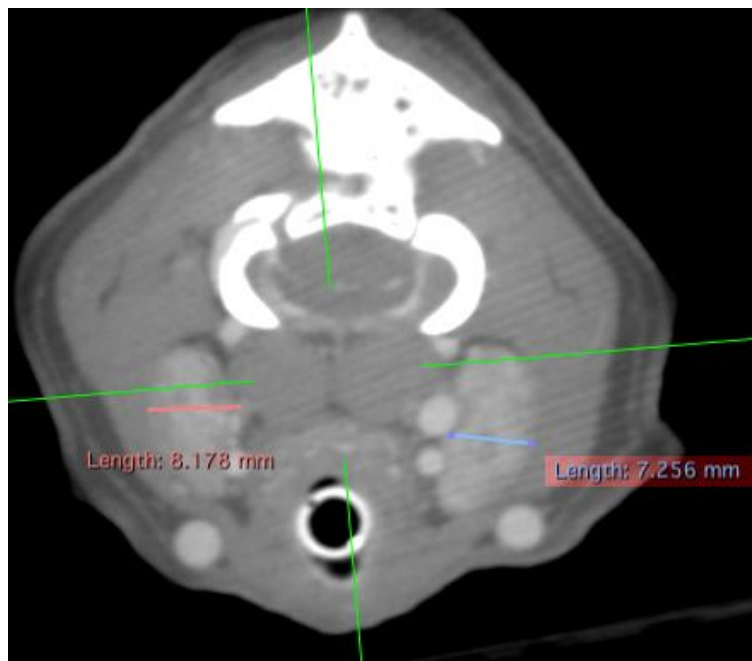East Village Green
Hospital

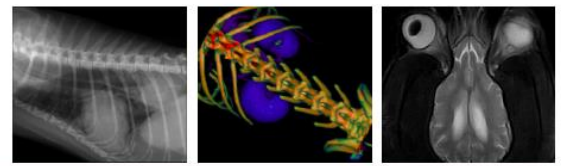
INVOICE

57332

DATE

3-16-23





PATIENT

Tucker Castillo

SPECIES

Feline

BREED

DSH

SEX

Male

AGE

8 Years

INTERPRETED BY

Tilde Rodrigues Froes,
DMV, MSc., Dr. Med
Vet., Dipl. CBraRVet

HOSPITAL NAME

Animal Surgical
Center

REFERRING VET

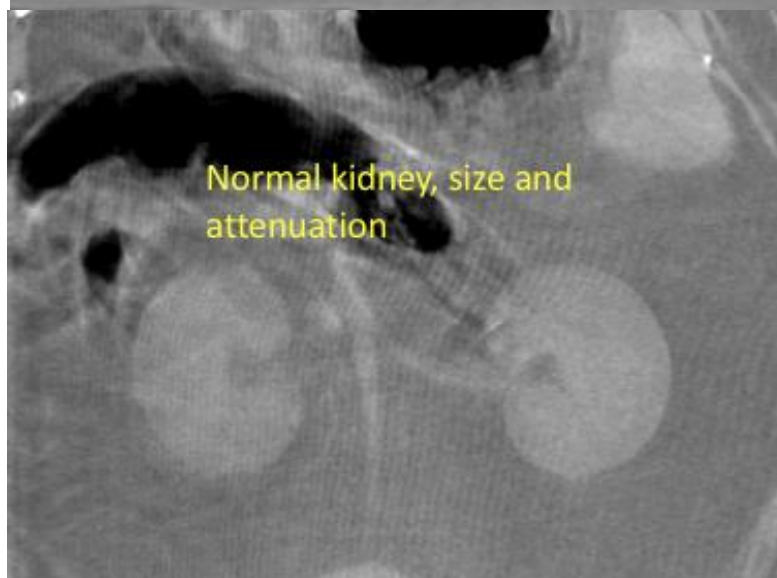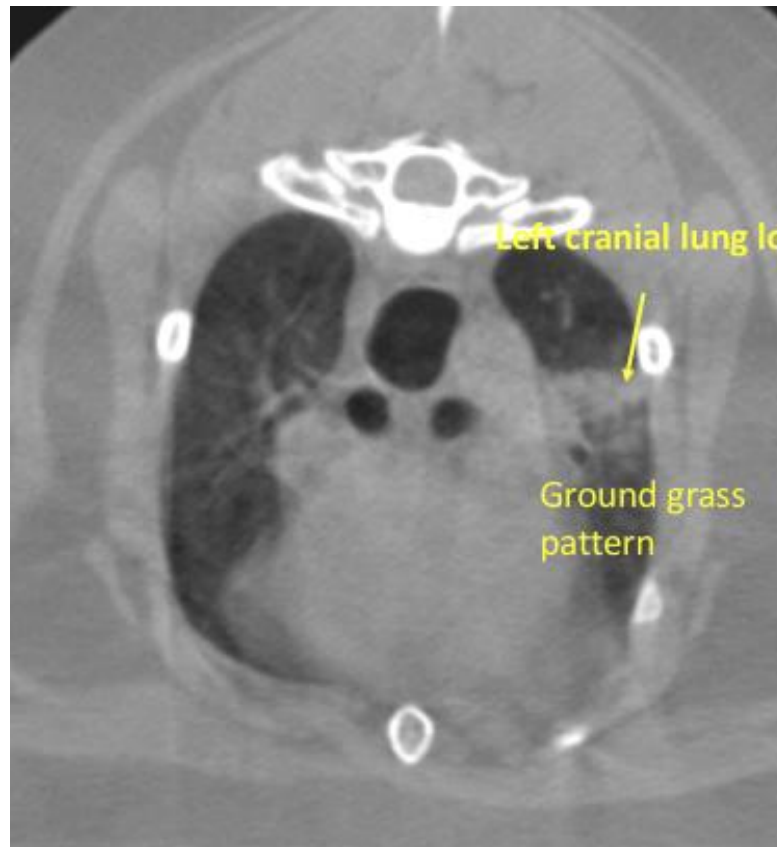
East Village Green
Hospital

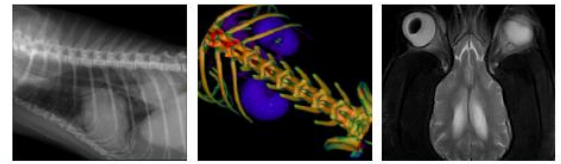
INVOICE

57332

DATE

3-16-23





PATIENT The information and recommendations provided are based on the images presented by the referring veterinarian. No evaluation can be communicated regarding pathology that was not visible in the image/video clips provided.

Tucker Castillo

SPECIES

Feline

Thank you for this referral. If the clinical or image interpretation does not parallel your findings or if I can be of any further assistance please contact me.

Tilde Rodrigues Froes, DMV, MSc., Dr. Med.Vet., Dipl.CBraRVet
info@sonopath.com

BREED

DSH

SEX

Male

AGE

8 Years

INTERPRETED BY

Tilde Rodrigues Froes,
DMV, MSc., Dr. Med
Vet., Dipl. CBraRVet

HOSPITAL NAME

Animal Surgical
Center

REFERRING VET

East Village Green
Hospital

INVOICE

57332

DATE

3-16-23