



**PATIENT PRESENTING CLINICAL SIGNS**

Stormy Lodge persistent cough duration 6mnt not resolved despite repeat courses of doxycycline  
 Abnormal PE/Chem/CBC/UA Results: initially testing positive to Bordetella bronchisetica and mycoplasma now negative to both

**SPECIES COMPUTED TOMOGRAPHIC STUDY OF THE THORAX**

Canine A high-resolution pre- contrast CT study of the thorax and airway cervical structures are provided for review. A total of seven series. One pre-contrast soft tissue, one bone and one pulmonary window. One post-contrast soft tissue, one bone and one pulmonary window.

**BREED COMPUTED TOMOGRAPHIC FINDINGS**

Poodle The choana, oropharynx, nasopharynx and hyoid apparatus are normal.

**SEX** The trachea is normal in luminal diameter and position.

F The lumen of the main bronchus is normal.

The pulmonary expansion and attenuation are normal.

**AGE** The cardiac silhouette and pulmonary vessels are normal. The contrast media fills adequately within the cardiac chambers and vessels on the post-contrast series.

14 Months

The tracheobronchial lymph nodes are normal.

**INTERPRETED BY** The sternal, mediastinal, and cranial mediastinal lymph nodes are unremarkable.

Tilde Rodrigues Froes, DMV, MSc., Dr. Med

Vet., Dipl. CBraRVet The pleural space and diaphragm are normal.

The collimated abdomen is normal.

**HOSPITAL NAME** The thoracic musculoskeletal structures are unremarkable.

Advanced Veterinary No other abnormalities are identified.

Imaging **COMPUTED TOMOGRAPHIC DIAGNOSIS**

- Normal airway, trachea, and pulmonary parenchyma.
- No evidence of bronchopneumonia.

**REFERRING VET INTERPRETATION OF THE FINDINGS & FURTHER RECOMMENDATIONS**

Eamon No tomographic findings were detected that could explain the causes of the chronic cough.  
**INVOICE** No evidence of fluid accumulation in the airway pathway. The pulmonary parenchyma is normal.  
 Consider some irritation causes of the airway, or viral etiologies. Continuing symptomatic therapy is suggested.  
 57246

**DATE**

3-15-23



**PATIENT**

Stormy Lodge

**SPECIES**

Canine

**BREED**

Poodle

**SEX**

F

**AGE**

14 Months

**INTERPRETED BY**

Tilde Rodrigues Froes,  
DMV, MSc., Dr. Med  
Vet., Dipl. CBraRVet

**HOSPITAL NAME**

Advanced Veterinary  
Imaging

**REFERRING VET**

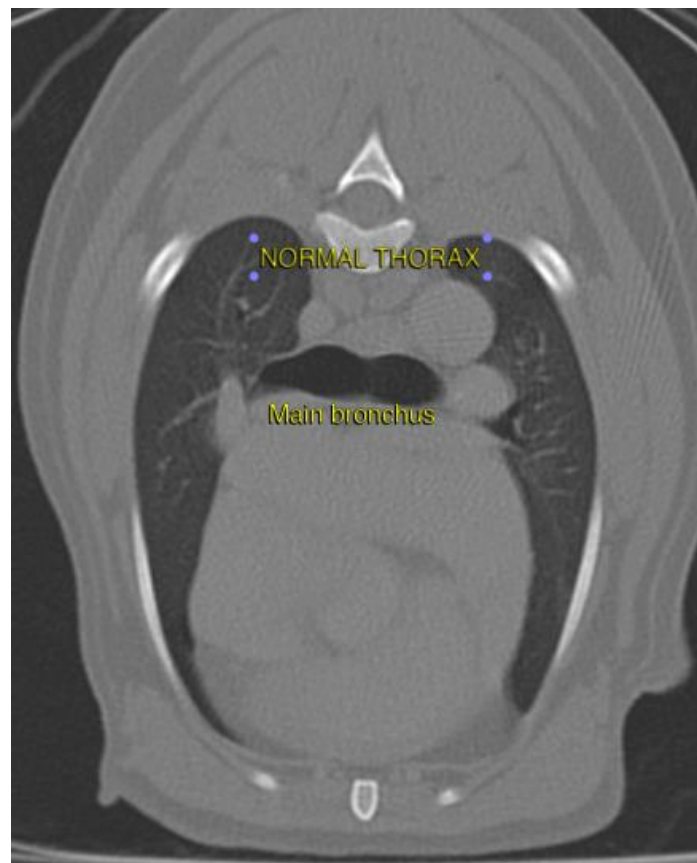
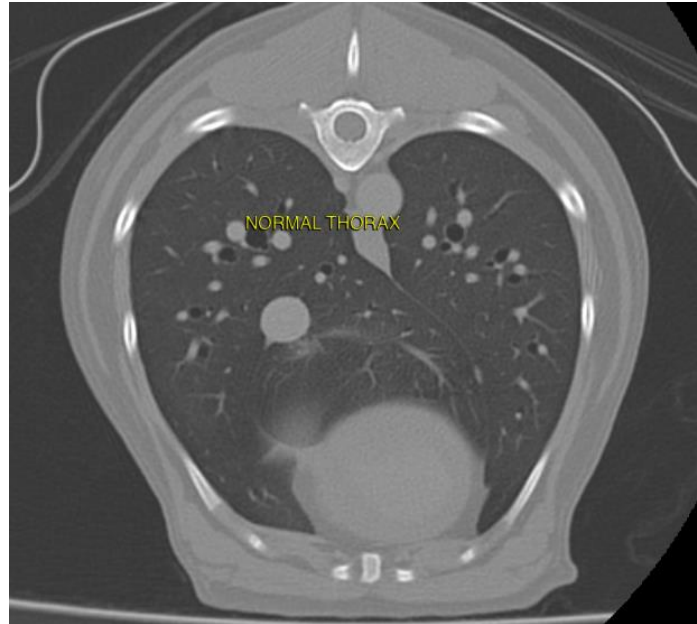
Eamon

**INVOICE**

57246

**DATE**

3-15-23





**PATIENT**

Stormy Lodge

**SPECIES**

Canine

**BREED**

Poodle

**SEX**

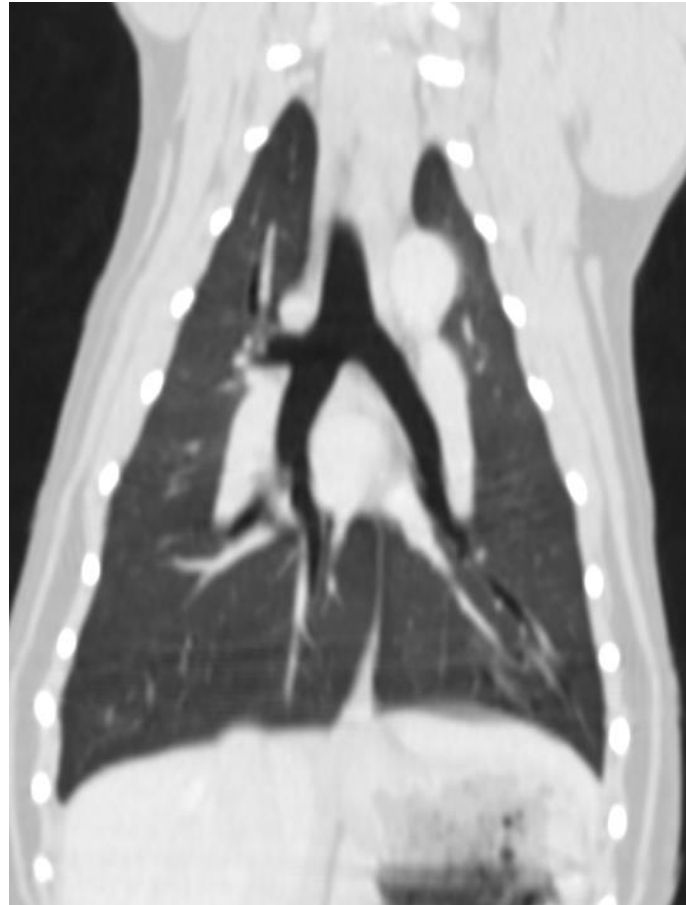F

**AGE**

14 Months

**INTERPRETED BY**

Tilde Rodrigues Froes,  
DMV, MSc., Dr. Med  
Vet., Dipl. CBraRVet



**HOSPITAL NAME**

Advanced Veterinary  
Imaging

**REFERRING VET**

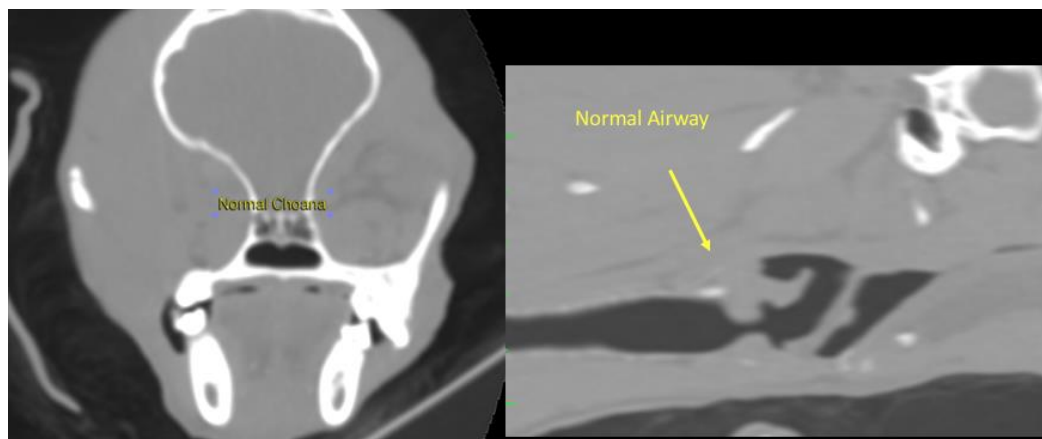
Eamon

**INVOICE**

57246

**DATE**

3-15-23





**PATIENT**

Stormy Lodge

The information and recommendations provided are based on the images presented by the referring veterinarian. No evaluation can be communicated regarding pathology that was not visible in the image/video clips provided.

**SPECIES**

Canine

Thank you for this referral. If the clinical or image interpretation does not parallel your findings or if I can be of any further assistance please contact me.

**Tilde Rodrigues Froes, DMV, MSc., Dr. Med.Vet., Dipl.CBraRVet**  
info@sonopath.com

**BREED**

Poodle

**SEX**

F

**AGE**

14 Months

**INTERPRETED BY**

Tilde Rodrigues Froes,  
DMV, MSc., Dr. Med  
Vet., Dipl. CBraRVet

**HOSPITAL NAME**

Advanced Veterinary  
Imaging

**REFERRING VET**

Eamon

**INVOICE**

57246

**DATE**

3-15-23