



PATIENT

Ajax Tully

SPECIES

Canine

BREED

French Bulldog

SEX

MN

AGE

9Y, 8M

WEIGHT

9.1kg

INTERPRETED BY

Tilde Rodrigues Froes,
DMV, MSc., Dr. Med
Vet., Dipl. CBraRVet

IMAGING PERFORMED BY

BN

HOSPITAL NAME

Bridgwater Veterinary
Hospital and Wellness
Centre

REFERRING VET

Dr D. Trindade

INVOICE

74113

DATE

3-10-26

PRESENTING CLINICAL SIGNS

- Feb 14/26-rDVM-Palpable large caudal abdominal hard mass.
- Rectal exam can palpate mass extraluminal of distal colon.
- Abdominal rads-Increased space occupying opacity of dorsocaudal abdomen in region of sublumbar LN a/w ventral displacement of colon and urinary bladder
- Discreet radiopacity in the pulmonary parenchyma adjacent to the cardiac apex.
- Other possible smaller discreet lung opacities noted.
- FNA's were inconclusive
- Mets check
- Surgical candidate?
- April/25: Hx of possible disc issue with ongoing LHL lameness

COMPUTED TOMOGRAPHIC STUDY OF THE THORAX AND ABDOMEN

A pre- and post-contrast CT study of thorax and abdomen are provided for review totaling 3 series. Two pre-contrast series of the thorax and abdomen, soft tissue algorithm. One post-contrast series of the thorax and abdomen, soft tissue algorithm.

COMPUTED TOMOGRAPHIC FINDINGS

ABDOMEN

Within the caudal retroperitoneal region extending into the caudal abdomen there is a very large, multilobulated soft tissue mass characterized by irregular margins and markedly heterogeneous attenuation. The lesion contains multiple hypoattenuating areas components interspersed with irregular regions of contrast enhancement. The mass produces marked mass effect on adjacent abdominal structures and demonstrates infiltrative characteristics.

The lesion appears to encompass the medial iliac lymph nodes, including accessory lymph nodes, and extends ventrally toward the left abdominal wall with infiltration of the adjacent musculature. The involved musculature includes portions of the left internal abdominal oblique muscle, rectus abdominis muscle, psoas minor, psoas major, and the region of the inguinal ligament. These findings result in a combined intra-abdominal and parietal soft tissue component, indicating extensive regional invasion.

The mass also surrounds the major caudal abdominal vessels and their distal tributaries. A large intraluminal filling defect is identified within the left common iliac vein, compatible with vascular invasion and possible tumor thrombus. The abdominal aorta does not demonstrate intraluminal filling defects; however, its wall appears diffusely thickened at the level of and distal to the iliac bifurcation. The left external and internal iliac arteries are displaced and appear tortuous secondary to the surrounding mass effect.

The descending colon is displaced and compressed by the mass, with partial loss of normal serosal border definition, raising suspicion for possible mural or serosal involvement. Despite this compression, there is no evidence of significant fecal retention, and the remaining portions of the colon and rectum appear unremarkable.

The urinary bladder is displaced ventrally, while the urethra and prostate are displaced ventrolaterally. The left ureter is markedly dilated, measuring approximately 2.2 cm proximally, consistent with severe hydronephrosis. This dilation is associated with severe hydronephrosis of the left kidney and marked loss of both cortical and medullary parenchyma, compatible with chronic obstructive uropathy. The left



PATIENT

ureter appears to course through or adjacent to the large retroperitoneal mass and is likely compressed or infiltrated by it. The right ureter cannot be clearly delineated.

Ajax Tully

SPECIES

Both kidneys contain multiple small hypoattenuating nodules, some of which display mixed attenuation characteristics, measuring between approximately 3.8 mm and 9.1 mm. The left kidney is enlarged relative to the contralateral side, likely secondary to the obstructive process.

Canine

BREED

Within the hepatic parenchyma, multiple nodules of similar attenuation are identified in a multifocal distribution, measuring between approximately 5 mm and 1.2 cm in diameter. The liver otherwise maintains normal size and overall contour.

French Bulldog

Multiple para-aortic lymph nodes are enlarged, rounded, and heterogeneous in attenuation.

SEX

The gallbladder, cystic duct, and common bile duct are within normal limits.

MN

The spleen is homogeneous in soft tissue attenuation with uniform contrast enhancement and normal size and contour.

AGE

9Y, 8M

The pancreas and remaining mesenteric abdominal lymph nodes appear unremarkable. Mild regional fat stranding is present adjacent to the large mass effect.

WEIGHT

9.1kg

The remaining abdominal serosal fat demonstrates normal attenuation, and there is no evidence of peritoneal effusion.

INTERPRETED BY

The left adrenal gland contains two small hypoattenuating nodules measuring approximately 7.5 mm and 6.7 mm; however, the gland maintains normal overall size and morphology. The right adrenal gland appears within normal limits.

Tilde Rodrigues Froes,
DMV, MSc., Dr. Med
Vet., Dipl. CBraRVet

Multiple congenital vertebral malformations consistent with hemivertebrae are identified throughout the thoracic and thoracolumbar spine, extending from approximately T3 through T12. These are associated with kyphosis, variable narrowing of the intervertebral disc spaces, and multifocal complete and incomplete spondylosis deformans. Within the vertebral canal, small amounts of mineralized extradural material are present at the level of L2-L3 on the right side, producing mild spinal cord compression, and at L7-S1 along the ventral and left aspects of the canal, producing mild impingement of adjacent nerve roots. No aggressive osseous lesions are identified.

IMAGING PERFORMED BY

BN

HOSPITAL NAME

Bridgwater Veterinary
Hospital and Wellness
Centre

The coxofemoral joints are bilaterally subluxated and associated with moderate periarticular ossifications. At the caudal margin of the scan, both patellae appear medially subluxated with concurrent periarticular ossification.

REFERRING VET

Dr D. Trindade

THORAX

Within the thorax, the trachea is mildly displaced secondary to the presence of markedly enlarged tracheobronchial lymph nodes. No intraluminal abnormalities are identified within the trachea, and the main bronchi remains within normal limits.

INVOICE

74113

The cranial mediastinal, and tracheobronchial lymph nodes are moderately to severely enlarged, rounded, and demonstrate heterogeneous contrast enhancement. The largest sternal lymph node measures approximately 1.8 × 2.8 cm, while the largest cranial mediastinal lymph node measures approximately 2.4 × 1.9 cm.

DATE

3-10-26



PATIENT

Ajax Tully

SPECIES

Canine

BREED

French Bulldog

SEX

MN

AGE

9Y, 8M

WEIGHT

9.1kg

INTERPRETED BY

Tilde Rodrigues Froes,
DMV, MSc., Dr. Med
Vet., Dipl. CBraRVet

IMAGING PERFORMED BY

BN

HOSPITAL NAME

Bridgwater Veterinary
Hospital and Wellness
Centre

REFERRING VET

Dr D. Trindade

INVOICE

74113

DATE

3-10-26

Within the pulmonary parenchyma, a heterogeneous rounded mass with irregular contours is identified in the ventral portion of the left caudal lung lobe, measuring 3.4 x 4.3 cm. A second heterogeneous rounded mass is identified in the ventral portion of the right cranial lung lobe measuring 1.8 x 2.8 cm. In addition, numerous pulmonary nodules of variable size are present throughout the lungs, including micronodules, small nodules, and larger nodules distributed in a multifocal pattern across the pulmonary parenchyma.

The bronchial tree demonstrates normal branching and progressive tapering toward the periphery. The bronchial walls appear thin and smooth, and the bronchus-to-artery ratio remains within normal limits.

The cardiac silhouette and pulmonary vasculature appear normal in size and morphology, and adequate opacification of the cardiac chambers and major vessels is observed on the post-contrast images.

The pleural space, diaphragm, and thoracic wall are unremarkable.

Within the caudal mediastinum, adjacent to and partially silhouetting the esophageal and cardia region, there is a rounded heterogeneous hypoattenuating soft tissue mass measuring approximately 2.1 x 2.1 cm. This structure may represent an enlarged metastatic lymph node, an esophageal-associated lesion, or another metastatic focus.

COMPUTED TOMOGRAPHIC DIAGNOSIS

- There is a very large, aggressive retroperitoneal soft tissue mass within the caudal abdomen demonstrating heterogeneous attenuation, infiltrative behavior, and extensive regional invasion. The lesion encompasses the medial iliac lymph nodes, extends into the left abdominal wall musculature and pelvic limb musculature, and surrounds the major caudal abdominal vessels. A filling defect within the left common iliac vein is present and is highly suspicious for tumor thrombus or vascular invasion. Possible phlebitis of the caudal abdominal aorta.
- The mass results in marked mass effect and secondary complications including severe left hydronephrosis and hydronephrosis with significant loss of renal parenchyma, consistent with chronic obstructive uropathy. Multiple enlarged para-aortic lymph nodes are also present and are highly suspicious for metastatic lymphadenopathy.
- Multifocal hepatic nodules and multiple small renal nodules are present, raising strong suspicion for metastatic disease.
- Within the thorax, a pulmonary mass is identified within the ventral portion of the left lung lobe and in right cranial lung lobe, accompanied by numerous pulmonary nodules of variable size distributed throughout the pulmonary parenchyma. These findings indicate pulmonary metastatic disease.
- Marked enlargement of the tracheobronchial and cranial mediastinal lymph nodes is present and is consistent with metastatic lymphadenopathy.
- A rounded paraesophageal mass within the caudal mediastinum is also identified and likely represents metastatic lymphadenopathy or another metastatic soft tissue focus.
- Incidental findings include multiple thoracic hemivertebrae with associated kyphosis and multifocal spondylosis deformans, mild extradural disc mineralization at L2-L3 and L7-S1 with mild neural compression, bilateral hip dysplasia with periarticular osteoarthritis, and bilateral medial patellar subluxation with osteoarthritis.

INTERPRETATION OF THE FINDINGS & FURTHER RECOMMENDATIONS

The computed tomographic findings reveal a large aggressive retroperitoneal mass with extensive local invasion involving the abdominal wall, pelvic limb musculature, regional lymph nodes, and major



PATIENT

Ajax Tully

SPECIES

Canine

BREED

French Bulldog

SEX

MN

AGE

9Y, 8M

WEIGHT

9.1kg

INTERPRETED BY

Tilde Rodrigues Froes,
DMV, MSc., Dr. Med
Vet., Dipl. CBraRVet

IMAGING PERFORMED BY

BN

HOSPITAL NAME

Bridgwater Veterinary
Hospital and Wellness
Centre

REFERRING VET

Dr D. Trindade

INVOICE

74113

DATE

3-10-26

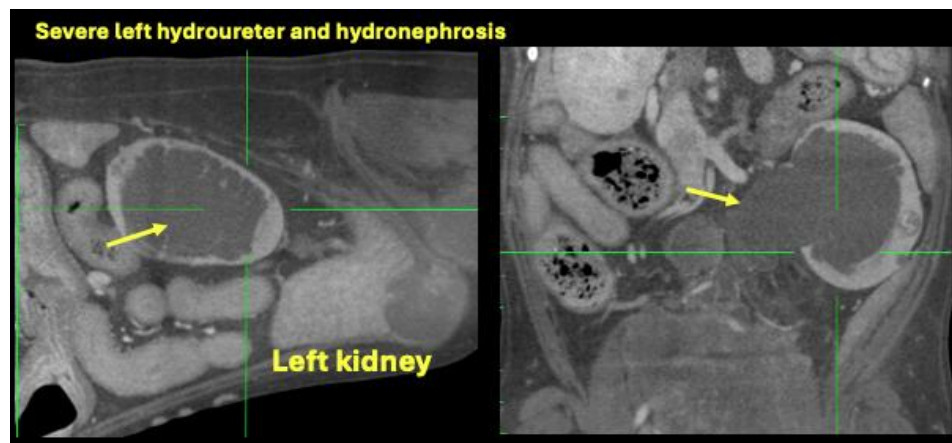
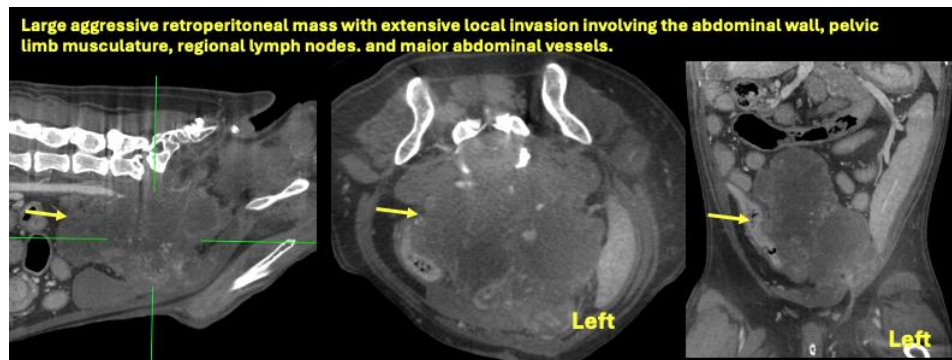
abdominal vessels. Secondary severe obstruction of the left ureter with resulting hydroureter and hydronephrosis is present. The presence of multiple enlarged abdominal lymph nodes, multifocal hepatic nodules, a pulmonary mass with numerous pulmonary nodules, thoracic lymphadenopathy, and a caudal mediastinal mass strongly supports advanced metastatic disease.

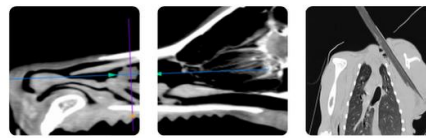
The imaging characteristics and distribution of disease are most compatible with an aggressive malignant neoplasm arising from the retroperitoneal or sublumbar lymph node region, with widespread metastatic dissemination, possible hemangiosarcoma or other types of soft tissue sarcoma.

Overall, the CT findings indicate an aggressive retroperitoneal neoplastic process with extensive regional invasion and widespread metastatic dissemination to thoracic lymph nodes, lungs, liver, and mediastinum, with secondary severe obstructive uropathy of the left kidney. The extent of disease suggests an advanced oncologic stage and a poor likelihood of surgical resectability.

Image-guided fine-needle aspiration or biopsy of the retroperitoneal mass or one of the enlarged lymph nodes (such as the para-aortic or sternal lymph nodes) is recommended for definitive diagnosis.

Consultation with a veterinary oncologist is recommended to discuss potential treatment options, including systemic therapy or palliative management. Assessment of renal function may also be considered given the severe left-sided obstructive uropathy.





PATIENT

Ajax Tully

SPECIES

Canine

BREED

French Bulldog

SEX

MN

AGE

9Y, 8M

WEIGHT

9.1kg

INTERPRETED BY

Tilde Rodrigues Froes,
DMV, MSc., Dr. Med
Vet., Dipl. CBraRVet

IMAGING PERFORMED BY

BN

HOSPITAL NAME

Bridgwater Veterinary
Hospital and Wellness
Centre

REFERRING VET

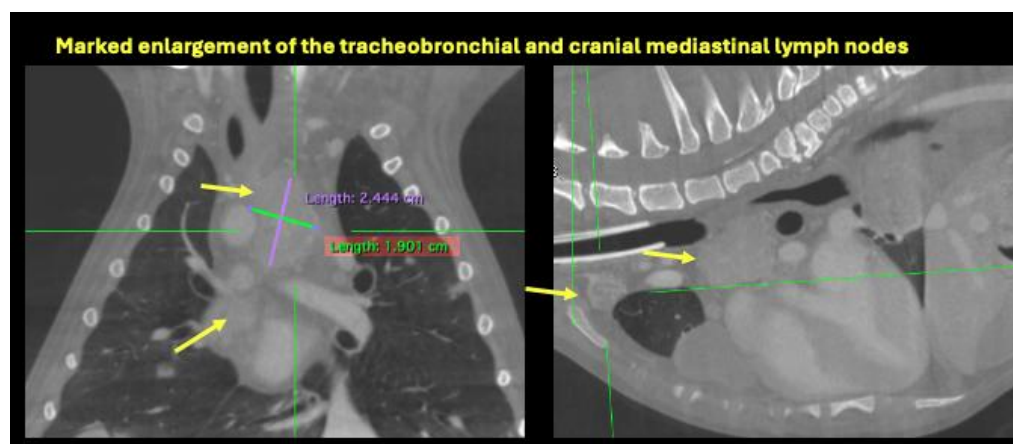
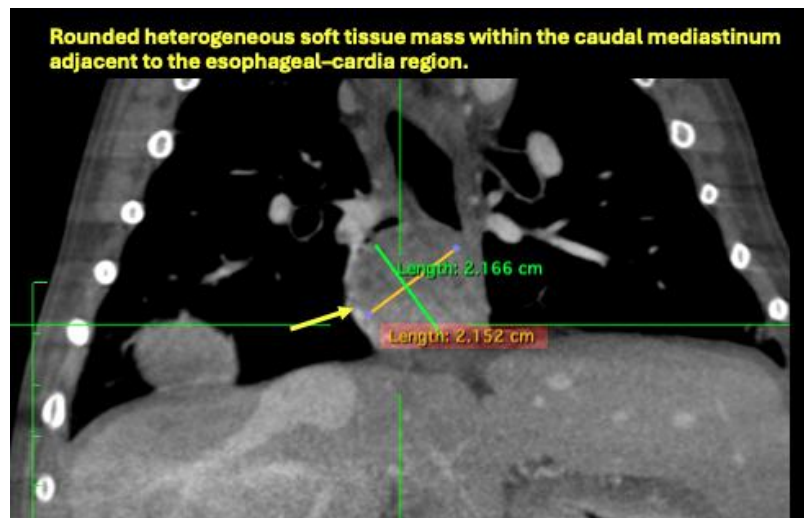
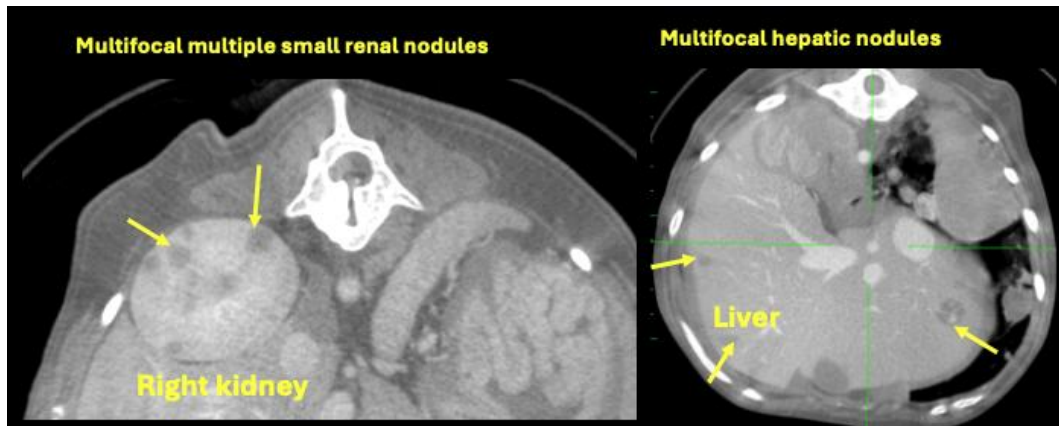
Dr D. Trindade

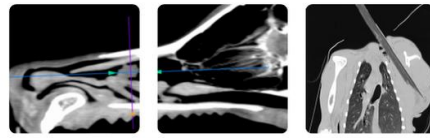
INVOICE

74113

DATE

3-10-26





PATIENT

Ajax Tully

SPECIES

Canine

BREED

French Bulldog

SEX

MN

AGE

9Y, 8M

WEIGHT

9.1kg

INTERPRETED BY

Tilde Rodrigues Froes,
DMV, MSc., Dr. Med
Vet., Dipl. CBraRVet

IMAGING PERFORMED BY

BN

HOSPITAL NAME

Bridgwater Veterinary
Hospital and Wellness
Centre

REFERRING VET

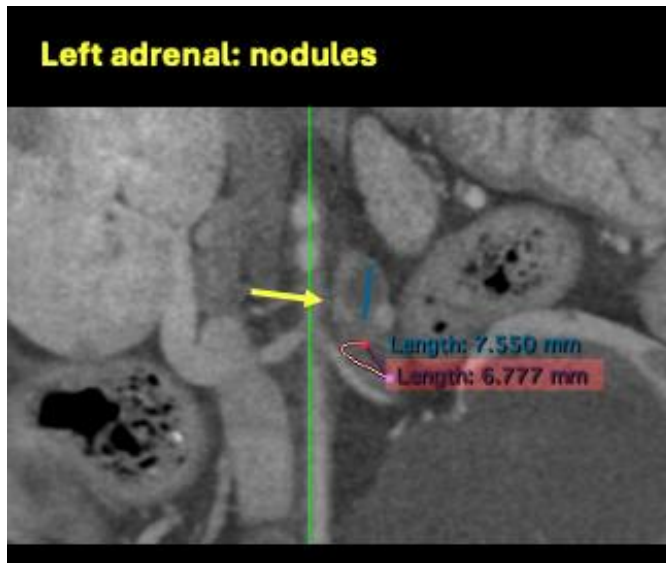
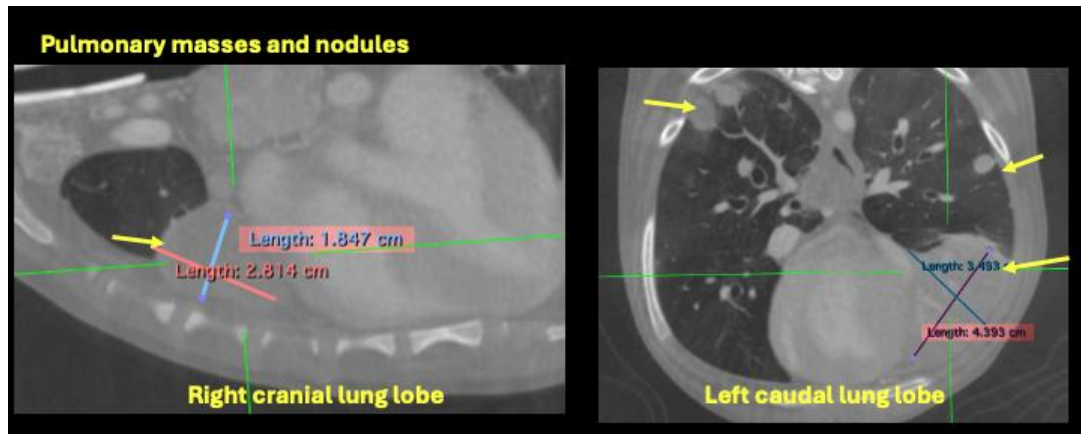
Dr D. Trindade

INVOICE

74113

DATE

3-10-26



The information and recommendations provided are based on the images presented by the referring veterinarian. No evaluation can be communicated regarding pathology that was not visible in the image/video clips provided.

Thank you for this referral. If the clinical or image interpretation does not parallel your findings or if I can be of any further assistance, please contact me.

Tilde Rodrigues Froes, DMV, MSc., Dr. Med.Vet., Dipl.CBraRVet
info@sonopath.com