



PATIENT PRESENTING CLINICAL SIGNS

Wiley King vomiting and decreased appetite x 1 week, may have been due to cefpodoxime (for a pyoderma)
 Abnormal PE/Chem/CBC/UA Results: mild increase in ALP Pending cPL

SPECIES RADIOGRAPHIC STUDY OF THE ABDOMEN

Canine Orthogonal views of the abdomen are available for review totaling 5 images.

RADIOGRAPHIC FINDINGS

BREED The cranial abdominal serosal detail is reduced, especially between the stomach and transverse colon, at the 10th through 13th intercostal spaces, in the region of the right lobe of the pancreas. The remainder of the abdominal serosal detail is normal.
 Brittany Spaniel

SEX The stomach is moderately filled with gas and homogeneous soft tissue opaque fluid, which redistributes normally with changes in patient position.

MN The small intestines are normally distributed, of normal diameter, and contain a predominantly soft tissue opaque fluid material throughout. No evidence of radiopaque foreign material or mechanical gastrointestinal obstruction.

AGE All portions of the colon are filled by intraluminal gas.

9 The liver and spleen are normal in size and shape.

INTERPRETED BY The urinary bladder is homogeneously soft tissue opaque and mildly distended with the apex in the plane of L6.

Tilde Rodrigues Froes, DMV, MSc., Dr. Med Vet., Dipl. CBraRVet The prostate is not identified, intrapelvic, it is normal.

The retroperitoneal space is normal.

HOSPITAL NAME In the collimated thorax, a diffuse unstructured interstitial pattern is seen as well as reduced lung volume expansion.

Northshore Veterinary Hospital No other abnormalities are identified.

RADIOGRAPHIC DIAGNOSIS

- REFERRING VET**
- Reduced serosal detail in the cranial abdomen, differential diagnosis includes pancreatitis and/or focal peritonitis, scant peritoneal effusion.
 - No evidence of mechanical gastrointestinal obstruction or radiopaque foreign material.
 - No evidence of abdominal mass effect.
 - Pulmonary atelectasis.

INVOICE

57029

INTERPRETATION OF THE FINDINGS & FURTHER RECOMMENDATIONS

A nonobstructive functional gastroenteritis and colitis is usually concurrent with pancreatitis. Other differential diagnosis includes inflammatory gastrointestinal disease, or less likely

DATE

3-1-23



PATIENT

Wiley King

infectious gastroenteritis. Recommend supportive care and an abdominal ultrasound is suggested if the patient fails to improve or worsens.

SPECIES

Canine

BREED

Brittany Spaniel

SEX

MN

AGE

9

INTERPRETED BY

Tilde Rodrigues Froes,
DMV, MSc., Dr. Med
Vet., Dipl. CBraRVet

HOSPITAL NAME

Northshore
Veterinary Hospital

REFERRING VET

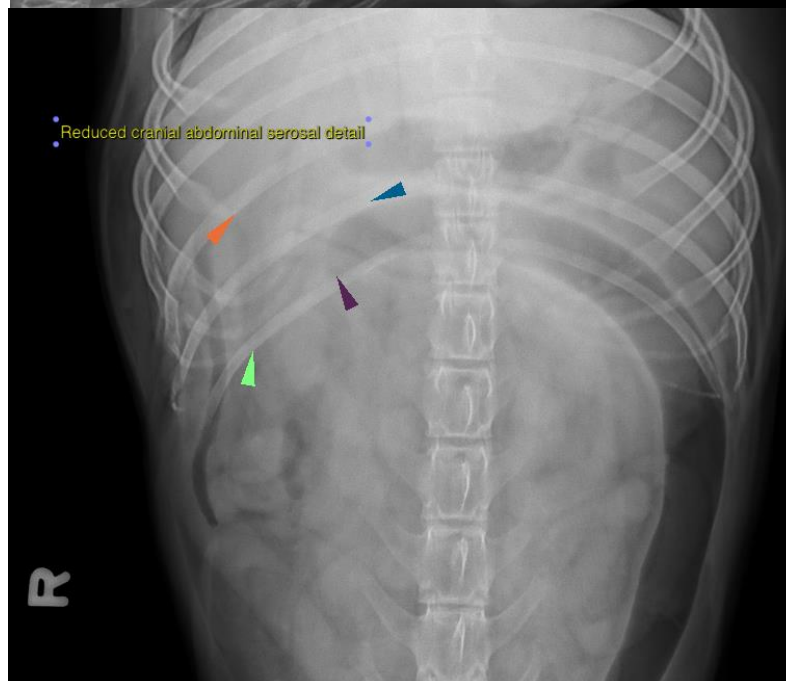
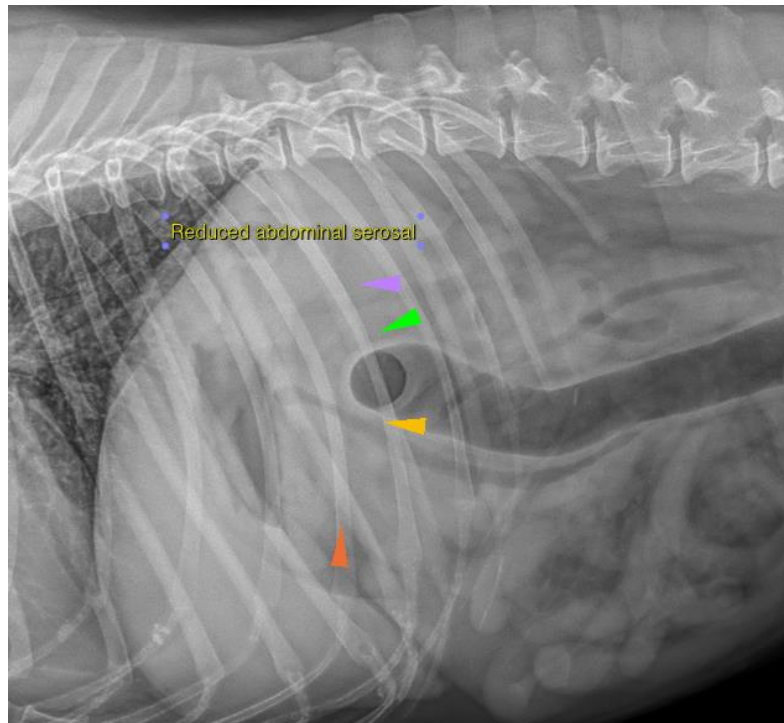
Brita Kiffney

INVOICE

57029

DATE

3-1-23





PATIENT

Wiley King

The information and recommendations provided are based on the images presented by the referring veterinarian. No evaluation can be communicated regarding pathology that was not visible in the image/video clips provided.

SPECIES

Canine

Thank you for this referral. If the clinical or image interpretation does not parallel your findings or if I can be of any further assistance please contact me.

BREED

Brittany Spaniel

Tilde Rodrigues Froes, DMV, MSc., Dr. Med.Vet., Dipl.CBraRVet
info@sonopath.com

SEX

MN

AGE

9

INTERPRETED BY

Tilde Rodrigues Froes,
DMV, MSc., Dr. Med
Vet., Dipl. CBraRVet

HOSPITAL NAME

Northshore
Veterinary Hospital

REFERRING VET

Brita Kiffney

INVOICE

57029

DATE

3-1-23